

Original article:

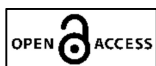A study of safety and efficacy of sub- conjunctival injection of mitomycin-c in combined cataract and glaucoma surgeries

¹Dr Rahul Baljirao Pandhre , ²Dr Sohel Irfan Mohd.Khan

¹Resident Doctor, Department of Ophthalmology Dr SCGMC Nanded.

²Associate Professor, Department of Ophthalmology Dr SCGMC Nanded.

Corresponding author: Dr Rahul Baljirao Pandhre



This work is licensed under a Creative Commons Attribution-NonCommercial 4.0 International License

Date of submission: 10 January 2023

Date of Final acceptance: 05 March 2023

Date of Publication: 30 March 2023

Source of support: Nil

Conflict of interest: Nil

Abstract:

Introduction: As subconjunctival scarring is the most common cause of post-operative bleb failure, the use of anti-scarring agents like Mitomycin-C (MMC) has proven to be beneficial in the successful outcome of this surgery.

Material and methods: This was Prospective longitudinal study conducted at tertiary care hospital. All patients with cataract and glaucoma attending ophthalmology OPD who fulfill the inclusion/exclusion criteria and those who give written informed consent were included in the study. All cases attending ophthalmology opd and casualty with Cataract and Glaucoma must understand the study and agree to participate which may include patients of all age groups excluding childrens and Patients with Cataract and glaucoma and with significant.

Results: Seidel test grading at 1 month is shown in Table , at 1 month, only 1 patient in the injection group demonstrated to have presence of pinpoint leaks on Seidel test. Seidel test grading at 3 months is shown in Table, no patient had bleb leak at 3 months follow up. Seidel test grading at 6 months is shown in Table , no patient had bleb leak at 6 months follow up.

Conclusion: In conclusion, subconjunctival injection of MMC (0.02%) injection is an safe, effective convenient in combined manual small incision cataract and glaucoma surgeries. Mitomycin C helps in longtime maintainence of patency of filtering bleb.

Keywords: sub- conjunctival , injection mitomycin-c

Introduction

As subconjunctival scarring is the most common cause of post-operative bleb failure, the use of anti-scarring agents like Mitomycin-C (MMC) has proven to be beneficial in the successful outcome of this surgery. MMC is the most frequently used agent due to its reasonable efficacy in preventing subconjunctival fibrosis as it causes inhibition of fibroblast proliferation (1-3). Though beneficial effect, the use of MMC has been associated with some serious side effects, thereby prompting its cautious use. The efficacy of MMC is

dependent on numerous factors, which includes concentration of MMC used, surface area of exposure, duration of exposure and other tissue-related factors (4). The method of MMC application using either subconjunctival sponge, sub-scleral flap sponge or subconjunctival injection influence the effectiveness and contributes to the morphology of the filtering bleb and its long-term survival (4). Subconjunctival injection of MMC is a common practice, which is associated with some well recognized complications (5). This study aims at studying safety and efficacy of the post-operative outcome of combined cataract and glaucoma surgeries with MMC by direct sub-conjunctival injection in cataract with glaucoma patients in MSICS cases.

Materials and methods

This was Prospective longitudinal study conducted at tertiary care hospital. All patients with cataract and glaucoma attending ophthalmology OPD who fulfill the inclusion/exclusion criteria and those who give written informed consent were included in the study.

Convenient Sampling method - Purposive Sampling

INCLUSION CRITERIA-

All cases attending ophthalmology opd and casualty with Cataract and Glaucoma must understand the study and agree to participate which may include :

- 1- patients of all age groups excluding childrens
- 2-Patients with Cataract and glaucoma and with significant visual loss and uncontrolled IOP .

EXCLUSION CRITERIA-

- 1.Any patient who does not give consent to be part of study
- 2.Patients with normal tension glaucoma and NVG glaucomas ,secondary glaucoma other than PXF glaucoma
- 3.Patients with history of trauma.
- 4.Patient failed to follow up.

Data were summarized using mean (SD) / median (range) for continuous variables and categorical data were expressed as frequency along with percentages. The baseline variables were observed using independent-t-test for continuous variables and chi square statistics for categorical variables.

Seidel test grading at 1 week is shown in Table 26. None of patient show presence of leak during the 1st week of follow up.

Results:

TABLE 1: SEIDEL TEST GRADING USING IBAGS AT 1 WEEK

Seidel test	Subconj MMC injection(%)
Total patients	32 (100)
S0: No leak	32 (100)

S1: Multiple pinpoint Leaks	0 (0.00)
S2: Streaming leak (within 5 seconds)	0 (0.00)
Mean \square SD	NA

Seidel test grading at 1 month is shown in Table , at 1 month, only 1 patient in the injection group demonstrated to have presence of pinpoint leaks on Seidel test.

TABLE 2: SEIDEL TEST GRADING USING IBAGS CLASSIFICATION AT1 MONTH

Seidel test	Subconj MMC injection (%)
Total patients	33 (100)
S0: No leak	32 (96.97)
S1: Multiple pinpoint Leaks	1 (3.03)
S2: Streaming leak (within 5 seconds)	0 (0.00)
Mean \square SD	NA

BLEB SEIDEL TEST: Seidel test grading at 3 months is shown in Table, no patient had bleb leak at 3 months follow up

TABLE 3: SEIDEL TEST GRADING USING IBAGS CLASSIFICATION AT3 MONTHS

Seidel test	Subconj MMC injection(%)
Total patients	33 (100)
S0: No leak	33 (100)
S1: Multiple pinpoint Leaks	0 (0.00)
S2: Streaming leak (within 5 seconds)	0 (0.00)
Mean \pm SD	NA

BLEB SEIDEL TEST: Seidel test grading at 6 months is shown in Table, no patient had bleb leak at 6 months follow up.

TABLE 4: SEIDEL TEST GRADING USING IBAGS CLASSIFICATION AT6 MONTHS

Seidel test	Subconj MMC injection(%)
Total patients	32 (100)
S0: No leak	32 (100)
S1: Multiple pinpoint Leaks	0 (0.00)
S2: Streaming leak (within 5 seconds)	0 (0.00)

Mean \square SD	NA
-------------------	----

Discussion:

MMC soaked sponges applied under the conjunctival space is the most widely used method of MMC delivery in patients undergoing trabeculectomy (.6,7) The application of MMC should involve a broader area, to help achieve a diffuse and ideal functional filtering bleb. With the use of MMC soaked sponges the volume of MMC delivered at the desired area may differ depending on the size of the sponges used, number of sponges used, the amount of soakage of the sponge and adequate coverage of the sub-conjunctival area. These factors may influence the morphological and functional characteristics of the filtering bleb. Additionally although rare, this method has been associated with the dreaded complication of losing the sponge into the orbit, and its sequelae. Hence, it is considered important to standardize the surgical procedure using a technique which can be exactly replicated and also ensure delivery of uniform dosage and concentration of MMC.(8)

By giving sub-conjunctival injection, MMC delivery is more widespread and its exact amount and concentration can be controlled, thereby theoretically providing an improved filtering bleb morphology and functionality. In this study, we seek to compare the two modes of delivery of MMC during trabeculectomy. Patients diagnosed to have either POAG, CACG, PACG or combined mechanism glaucoma and planned to undergo trabeculectomy with subconjunctival injection of MMC . All patients in this study underwent surgery. The concentration of MMC used was 0.02% (0.2mg/ml) and the surgical procedure was uniform throughout the study duration. All patients were followed up as per regular post- operative follow up schedule, and if needed more frequent follow-ups were advised, based on the glaucoma specialist’s clinical judgment. As per study protocol, patients were examined at 1 week, 1 month , 3 months and 6 months post-surgery. At each follow-up bleb images were taken by the PI.(9)

Releasable suture release is a common procedure in the post-operative management of filtering blebs. One patient underwent release of the releasable suture .This result may indicate a minimally better bleb morphology attained after MMC injection use, that defers the need to improve further aqueous outflow by removing a suture. Two patients had pointing sutures causing discomfort to patients which were trimmed. During the 3 months’ follow-up period, only five patients underwent additional bleb manipulation ,also bleb manipulation was demonstrated to patient and their relatives. Although statistically insignificant, this outcome can be considered clinically relevant in the management of glaucoma.(10)

Conclusion

In conclusion, subconjunctival injection of MMC (0.02%) injection is an safe, effective convenient in combined manual small incision cataract and glaucoma surgeries. Mitomycin C helps in longtime maintainence of patency of filtering bleb.

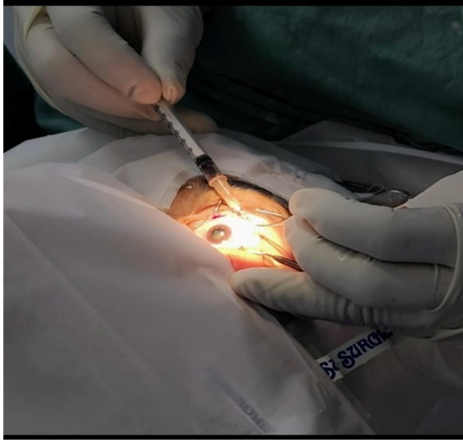

Image 1 . Showing injecting 0.2 mg Mitomycin C subconjunctivally.

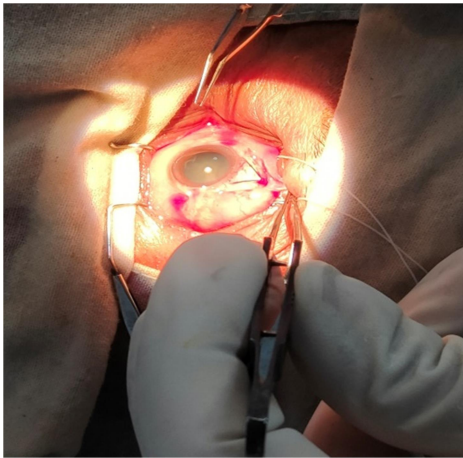


Image 2. Showing Partial thickness triangular flap.

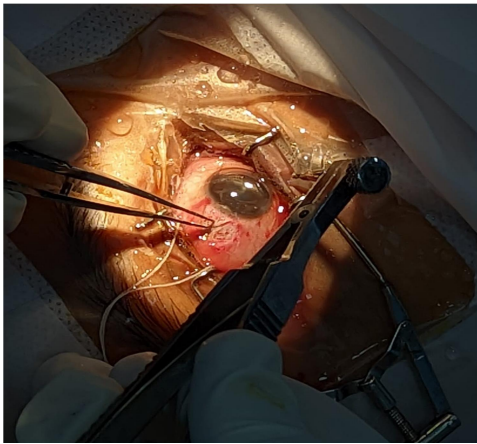


Image 3. Showing GASS punch using to excise trabecular block

References:

- 1.Weinreb RN, Aung T, Medeiros FA. The pathophysiology and treatment of glaucoma: a review. *JAMA*. 2014 May 14;311(18):1901–11.
- 2.Razeghinejad MR, Fudemberg SJ, Spaeth GL. The changing conceptual basis of trabeculectomy: a review of past and current surgical techniques. *Surv Ophthalmol*. 2012 Feb;57(1):1–25.
- 3.Crowston JG, Akbar AN, Constable PH, Occeleston NL, Daniels JT, Khaw PT. Antimetabolite-induced apoptosis in Tenon's capsule fibroblasts. *Invest Ophthalmol Vis Sci*. 1998 Feb;39(2):449–54.

4. Al Habash A, Aljasim LA, Owaidhah O, Edward DP. A review of the efficacy of mitomycin C in glaucoma filtration surgery. *Clin Ophthalmol Auckl NZ*. 2015 Oct 20;9:1945–51.
5. Lee E, Doyle E, Jenkins C. Trabeculectomy surgery augmented with intra-Tenon injection of mitomycin C. *Acta Ophthalmol (Copenh)*. 2008 Dec;86(8):866–70.
6. Quigley HA, Nickells RW, Kerrigan LA, Pease ME, Thibault DJ, Zack DJ. Retinal ganglion cell death in experimental glaucoma and after axotomy occurs by apoptosis. *Invest Ophthalmol Vis Sci*. 1995 Apr 1;36(5):774–86.
7. Quigley HA, Broman AT. The number of people with glaucoma worldwide in 2010 and 2020. *Br J Ophthalmol*. 2006 Mar 1;90(3):262–7.
8. Tham Y-C, Li X, Wong TY, Quigley HA, Aung T, Cheng C-Y. Global prevalence of glaucoma and projections of glaucoma burden through 2040: a systematic review and meta-analysis. *Ophthalmology*. 2014 Nov;121(11):2081–90.
9. Vohra R, Tsai JC, Kolko M. The Role of Inflammation in the Pathogenesis of Glaucoma. *Surv Ophthalmol*. 2013 Jul;58(4):311–20.
10. Arvind H, Raju P, Paul PG, Baskaran M, Ve Ramesh S, George RJ, et al. Pseudoexfoliation in south India. *Br J Ophthalmol*. 2003 Nov;87(11):1321–3.