

Case Report:

A rare case of type - I congenital pouch colon associated with common cloaca in a female child at birth in southern part of India

¹Dr Akshay Hiremath , ²Dr Avinash Vijay Joshi

¹Surgery Resident, Department of Surgery, Government Medical College, Miraj

²Assistant Professor, Department of Surgery, Government Medical College, Miraj

Corresponding author : Dr Akshay Hiremath



This work is licensed under a Creative Commons Attribution-NonCommercial 4.0 International License

Date of submission: 24 January 2023

Date of Final acceptance: 11 March 2023

Date of Publication: 30 March 2023

Source of support: Nil

Conflict of interest: Nil

Abstract:

We presented a case report of a 1-day-old female child admitted to the neonatal intensive care unit (NICU) with abdominal distension. Prenatal ultrasonography in the second trimester had revealed a large abdominal cyst. On examination, a common cloaca was noted along with a distended abdomen. Radiographic imaging confirmed the presence of collapsed small bowel pushed to the right, while a single large bowel filled most of the abdominal cavity. Further investigations, including ultrasound, indicated a 5.2 cm distended large bowel containing fecal material but no free fluid. The patient underwent exploratory laparotomy, during which an end ileostomy was performed following closure of the fistula with the urogenital tract. The postoperative period was uneventful, and the patient was discharged on postoperative day 5 with regular follow-up scheduled. Type I congenital pouch colon associated with common cloaca is an extremely rare condition involving complex malformations of the gastrointestinal and urogenital systems. This case report describes the clinical presentation, management, and outcomes of a 1-day-old female child with Type I congenital pouch colon and associated common cloaca.

Keywords: type - I congenital pouch colon, southern part of India

Introduction:

Type I congenital pouch colon associated with common cloaca is a rare condition that should be considered as a differential diagnosis in cases of abdominal distension, particularly in the presence of anorectal malformation. Early diagnosis and prompt management are essential to reduce mortality and morbidity associated with this condition. Awareness among healthcare professionals and timely intervention can improve outcomes for affected children. The pathogenesis and embryology of Type I congenital pouch colon associated with common cloaca are complex and involve abnormal development of the gastrointestinal and urogenital systems. Early identification and differentiation

from other conditions, such as anorectal malformations, are crucial for timely diagnosis and management. Prognosis depends on the type and length of the affected colon, perineal characteristics, and associated congenital anomalies.

Congenital anomalies of the colon and rectum are a diverse group of conditions that can present unique challenges in the field of pediatric surgery. One such rare case is that of Type I congenital pouch colon associated with common cloaca in a female child, which was observed at birth in the southern part of India. This condition represents a complex congenital malformation involving the gastrointestinal and urogenital systems.

Type I congenital pouch colon (CPC) is a rare variant of anorectal malformation (ARM) characterized by the presence of a dilated pouch-like colon that is blind-ending and communicates with the urogenital sinus. It is typically associated with an imperforate anus and a common cloaca, where the urinary, reproductive, and gastrointestinal tracts share a common opening.

Case Presentation:

A 1-day-old female child was admitted to the NICU with abdominal distension. Physical examination revealed a common cloaca and a distended abdomen. Radiographic imaging showed collapsed small bowel pushed to the right, with a single large bowel occupying most of the abdominal cavity. Ultrasound confirmed a distended large bowel containing fecal material. The patient underwent exploratory laparotomy, where an end ileostomy was performed after fistula closure with the urogenital tract. Postoperatively, the patient was shifted to the NICU and received appropriate care. Follow-up consultations were scheduled in both pediatric and surgical outpatient departments. The patient showed good weight gain and had no further complaints.

Discussion:

The case of a female child born with Type I CPC associated with common cloaca in southern India highlights the importance of early diagnosis and multidisciplinary management. The presentation of this condition can vary, ranging from mild symptoms to life-threatening complications. Prompt recognition and appropriate surgical intervention are crucial to ensure optimal outcomes for affected children. Understanding the complexities of such congenital malformations can aid healthcare professionals in delivering appropriate care and improving the quality of life for affected individuals.

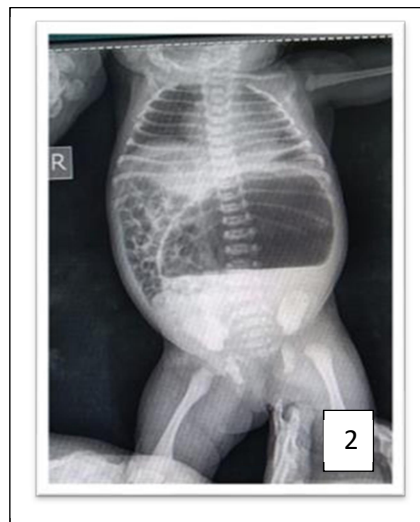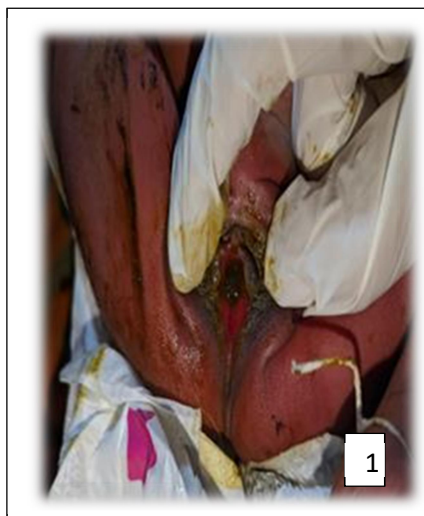Clinical Significance:

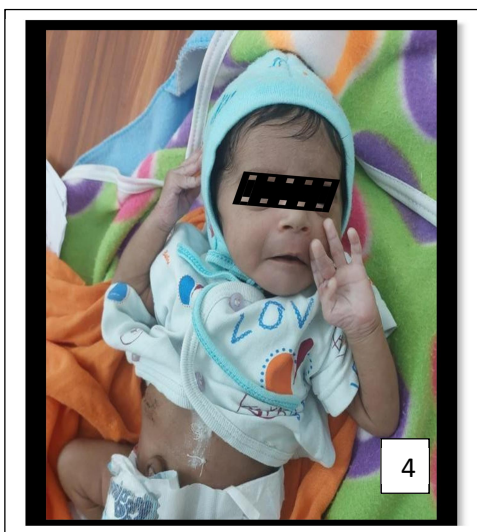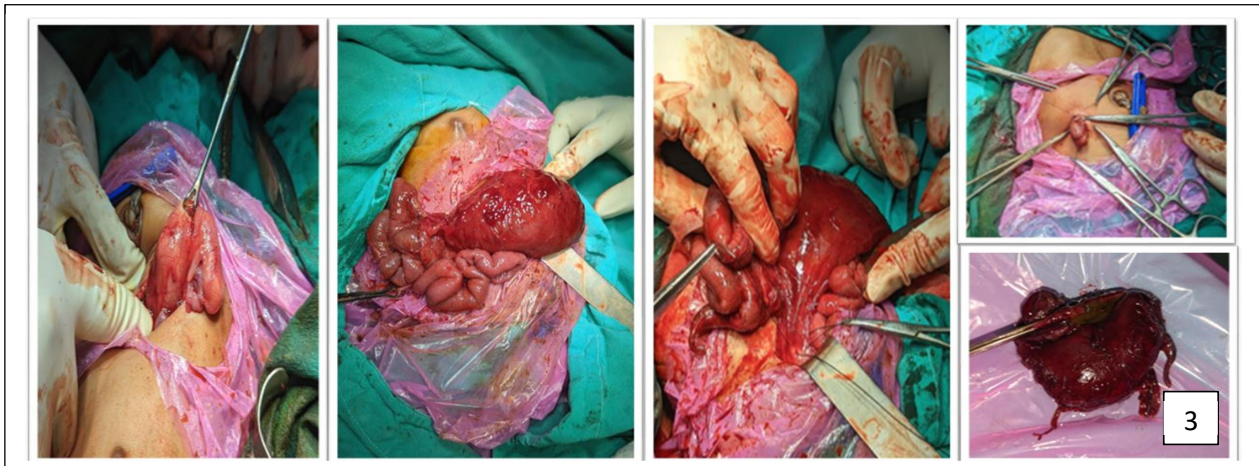
Type I congenital pouch colon associated with common cloaca is a clinically significant condition due to its rarity and complex nature. Understanding its clinical significance is essential for healthcare professionals involved in the management of affected children. The following points highlight the clinical significance of this condition:

1. **Rare and Challenging:** Type I congenital pouch colon associated with common cloaca is an extremely rare condition. Its occurrence poses diagnostic and management challenges due to the complex anatomical abnormalities involving both the gastrointestinal and urogenital systems. Healthcare professionals should be aware of this condition to ensure early detection and appropriate interventions.
2. **Abdominal Distension:** Abdominal distension is a common presenting symptom in these cases. Recognizing this clinical feature and considering Type I congenital pouch colon associated with common cloaca as a potential cause can help avoid delayed diagnosis and prevent complications associated with bowel obstruction.
3. **Differential Diagnosis:** Differential diagnosis plays a crucial role in distinguishing Type I congenital pouch colon associated with common cloaca from other conditions, particularly anorectal malformations.

Awareness of this condition as a differential diagnosis is vital for accurate diagnosis and timely management.

4. **Multidisciplinary Approach:** The complex nature of Type I congenital pouch colon associated with common cloaca necessitates a multidisciplinary approach involving pediatric surgeons, pediatric urologists, neonatologists, and other relevant specialists. Collaboration among different specialties is essential for comprehensive evaluation, surgical planning, and postoperative care.
5. **Surgical Intervention:** Timely surgical intervention is required to address the anatomical anomalies and associated complications. Exploratory laparotomy, fistula closure, and the creation of a stoma, such as an end ileostomy, are common surgical procedures performed in the management of Type I congenital pouch colon associated with common cloaca.
6. **Long-term Follow-up:** Long-term follow-up is crucial for monitoring the patient's growth, development, and bowel function. Regular follow-up visits to both pediatric and surgical outpatient departments allow for timely identification and management of potential complications or associated anomalies.
7. **Prognosis and Quality of Life:** The prognosis for Type I congenital pouch colon associated with common cloaca depends on factors such as the type and length of the affected colon, the presence of associated congenital anomalies, and the type of perineum. Understanding the prognostic factors can help healthcare professionals provide appropriate counseling to the child's family and ensure necessary support for optimal quality of life





Conclusion:

In conclusion, recognizing the clinical significance of Type I congenital pouch colon associated with common cloaca is crucial for early diagnosis, appropriate surgical management, and long-term follow-up. Timely intervention and multidisciplinary collaboration contribute to better outcomes and improved quality of life for affected children.

References:

1. Gallegos Torres P, Argüello Gordillo T, Ferrer Gracia V, Salazar Porras M. Congenital pouch colon: an unusual case report. *Cir Pediatr.* 2020 Jul 1;33(3):146-148.
2. Levitt MA, Pena A. Anorectal malformations. *Orphanet J Rare Dis.* 2007; 2:33.
3. Wood RJ, Levitt MA. Anorectal malformations. *Clin Colon Rectal Surg.* 2018; 31:61-70.
4. Bechit E, Murphy F, Puri P, Hutson JM. The clinical features and diagnostic guidelines for identification of anorectal malformations, In: *Anorectal Malformations in Children.* Springer Berlin Heidelberg; 2006 .p. 185-200.
5. Nah SA, Ong CC, Lakshmi NK, Yap TL, Jacobsen AS, Low Y. Anomalies associated with anorectal malformations according to the Krickbeck anatomic classification. *J Pediatr Surg.* 2012; 47:2273-8.

6. Stoll C, Alembik Y, Dott B, Roth MP. Associated malformations in patients with anorectal anomalies. *Eur J Med Genet.* 2007; 50:281–90.
7. Pierro A, Eaton S, Ong E. Neonatal physiology and metabolic considerations. In: Grosfeld JL, O’Neill JA Jr, Coran AG, Fonkalsrud EW, Caldamone AA. editors. *Pediatric Surgery.* 6th ed. Chicago: YearBook; 2006. p. 89-113.
8. Thapa B, Basnet B, Pun M, Thapa A. Management of Anorectal malformations in a tertiary level children’s hospital of Nepal. *J Nepal Paediatr Soc.* 2013; 33:196-200.