

Original article:

Erythroid hyperplasia on bone marrow aspiration – differential diagnosis on the basis of morphological changes

**Dr.Poonam Nanwani¹, Dr. SandeepBhandari², Dr. Sunil Jaiswal³ Dr.Priyanka Verma⁴,
Dr.Ashok Panchonia⁵, Dr. Sativan Khatri⁶**

¹-Assistant Professor, ²- PG resident , ³- Demonstrator, ⁴ - PG Resident, ⁵- Professor and Head of Department, ⁶ - Demonstrator

Department of Pathology, Mahatma Gandhi Memorial Medical College, Indore, Madhya Pradesh

Corresponding Author

Dr.Poonam Nanwani

Assistant Professor

M.G.M. medical college, Indore

Abstract:

Introduction - Erythroid hyperplasia is a condition of excessive count of erythroid precursor cells in the bone marrow. Erythroid cells are formed from myeloid progenitor cells and from megakaryocyte erythroid progenitor cells, which are then turned into mature red blood cells.

Aim- Aim of this study is to do differential diagnosis of various hematological disorder presented with erythroid hyperplasia on the basis of morphological changes in bone marrow aspiration.

Method and material - Prospective study, carried out in Department of Pathology from July 2019 to July 2021. A total of 200 cases were studied. Bone marrow aspiration done and all smears studied. Out of 200 cases 70 cases showing erythroid hyperplasia were included in this study.

Result - Specimens of 70 patients with distinct erythroid hyperplasia were selected (20 with megaloblastic anemia, 09 with nutritional anemia, 08 with hemolytic anemia, 14 with myeloid dysplastic syndromes, two with waldenstrom's syndrome, one with reactive hyperplasia , one with polycythemia vera and one with post transplant bone marrow, and 10 with iron deficiency) . Marrow hypercellularity and distinct erythropoietic hyperplasia were present in all cases those were studied.

Conclusion - It was concluded from the study that erythroid hyperplasia on bone marrow aspiration along with correlation of clinical, hematological finding help in differential diagnosis of various hematological disorders.

Introduction:

The marrow produces cellular elements of blood, including platelets, red blood cells and white blood cells. While much information can be gained by testing the blood itself, it is sometimes necessary to examine the source of the blood cells in the marrow. (1)

Anemias caused by RBC destruction or blood loss are characterized by reticulocytosis and bone marrow erythroid hyperplasia, whereas anemias due to marrow hypoplasia or ineffective erythropoiesis are associated with reticulocytopenia and a variable bone marrow cellularity ranging from profound hypocellularity to marked hypercellularity.(2)

Erythroid hyperplasia:

Benign causes- Erythroid hyperplasia is usually a compensatory condition. It can develop in case of Nutritional anemia, hemolytic anemia, iron deficiency anemia, thalassemia, angiopathies, thrombotic thrombocytopenic purpura (TTP), familial polycythemia, pancytopenia secondary to hypersplenism, erythromyelosis and blood loss.

Malignant causes : polycythemia vera, dysregulated erythropoietin production by various neoplasms

Aim- Aim of this study is to do differential diagnosis of various hematological disorder presented with erythroid hyperplasia on the basis of morphological changes in erythroid series on bone marrow aspiration.

Method and material-

This study was undertaken in the Department of Pathology of a tertiary care hospital over a period of 2 year. A total of 200 bone marrow aspirates of patients with various hematological, nonhematological disorders or when otherwise indicated were examined. A detailed clinical history was obtained from all the patients followed by a thorough clinical examination. Routine laboratory investigations were done. A written and informed consent was taken from the patients for bone marrow aspiration.

Bone marrow aspiration was done according to the standard procedure using Salah's bone marrow aspiration needle. A peripheral smear of patients was also done at the same time.

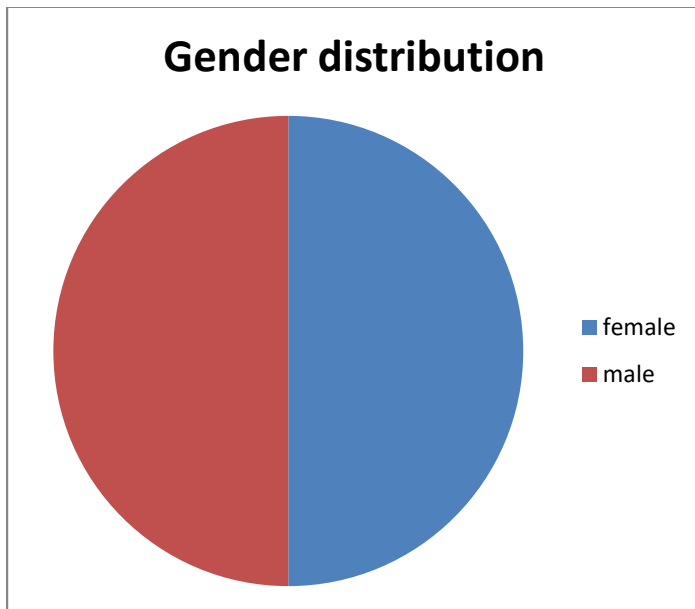
Prospective study, carried out in Department of Pathology from July 2019 to July 2021. A total of 200 cases were studied. After bone marrow aspiration was done and all smears were studied. Out of 200cases , 70 cases showing erythroid hyperplasia on bone marrow aspiration were included in this study. Patient of all age group and both the sex were included in the study. Bone Marrow Aspiration was evaluated for adequacy, cellularity, morphology and maturation of hemopoietic precursor cells. In all the cases 500 erythroblasts were counted and looked for morphological changes. Along with this myeloid erythroid ratio were calculated in each case. Blood test reports were noted from patient record, Complete blood count and reticulocyte count were done in all cases.

Result:-

In this study, 200 bone marrow aspirations were examined. The following observations were made. Patient of all age group and both the sex were included in the study (mean-47 years). 35 (50%) males and 35 (50%) females were included in the study showing equal incidence.

59 aspirates (74.54%) showed hypercellularity, 10 (21.81%) were normocellular and only 01 cases (3.63%) were hypocellular. Of the 59 cases which were hypercellular, 10 showedmicronormoblastic maturation, 20 showed megaloblastic maturation, 09 cases showed dual maturation and only 3 cases showed normoblastic maturation.

S. No.	Age group(in years)	Erythroid hyperplasia (no. of cases)
1	Up to 10	10
2	11-20	30
3	21-30	11
4	31-40	09
5	41-50	08
6	51-60	01
7	>60	01
	Total	70



Erythroid hyperplasia was confirmed by bone marrow aspiration. The marrow was normo- or hypercellular with increased normoblastic erythropoiesis, which is organized in clusters. Blood test results were noted in all the cases, results variable depending on the underlying disorder. Reticulocyte count was raises.

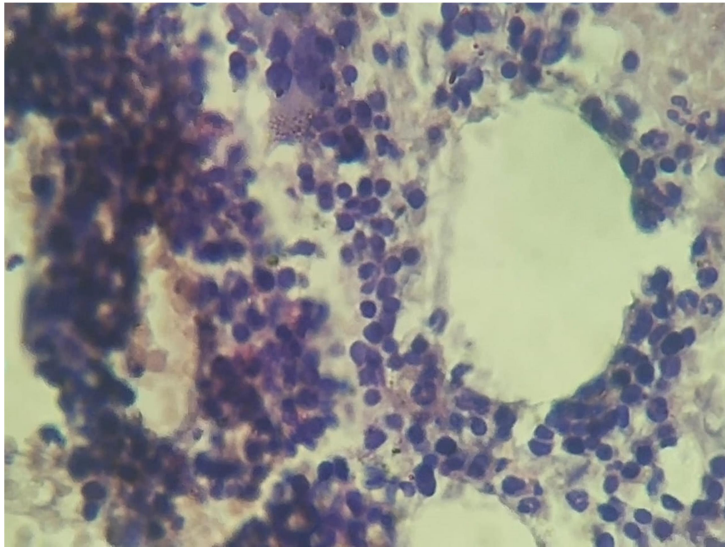


Fig. 1. Bone marrow biopsy showing erythroid hyperplasia.

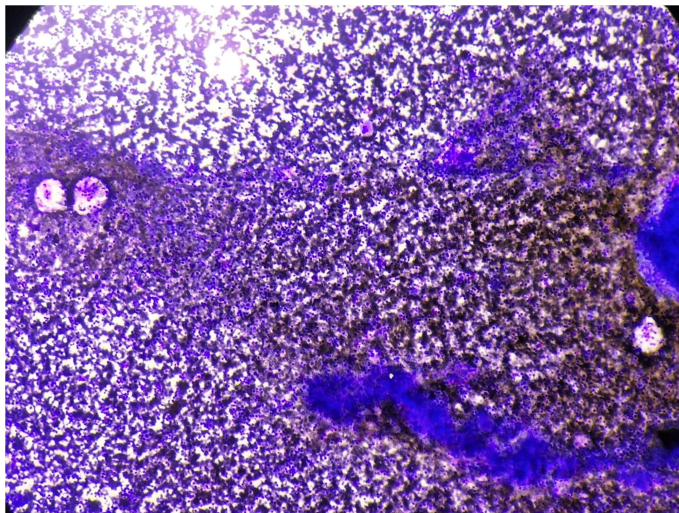


Fig 2. Hypercellular marrow showing Erythroid hyperplasia with megakaryocytic hyperplasia(10x)

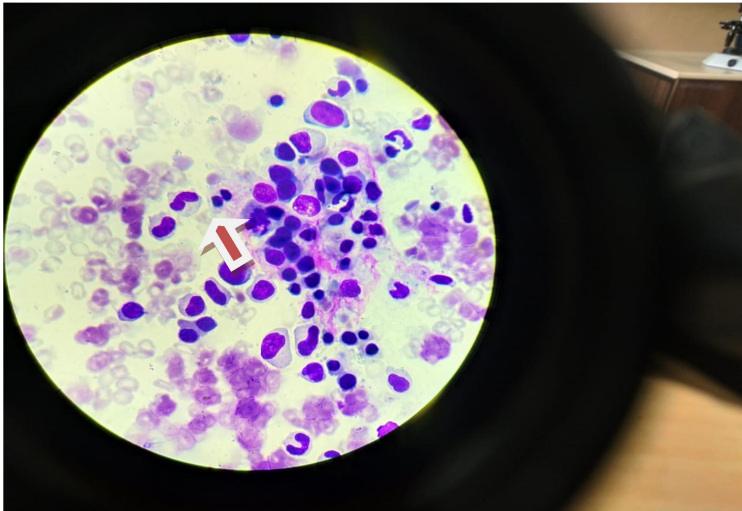


Fig. 3. Bone marrow aspirate showing Hypercellular marrow showing binucleated erythroblast (red arrow)

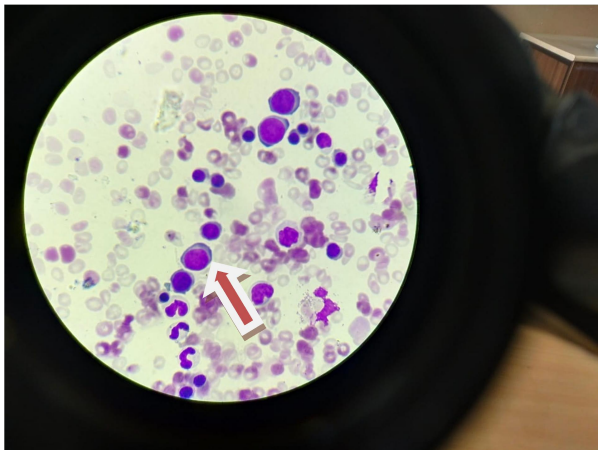


Fig 4a

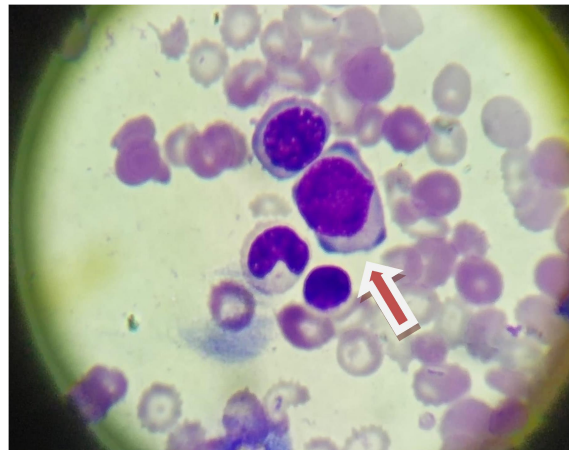


Fig 4 b

Fig 4 'a' and 'b' BMA showing macroerythroblasts

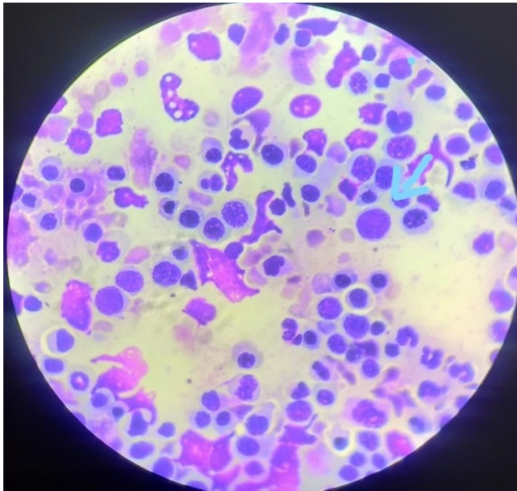


Fig 5a – erythroblasts showing nuclear budding , macrorothroblasts

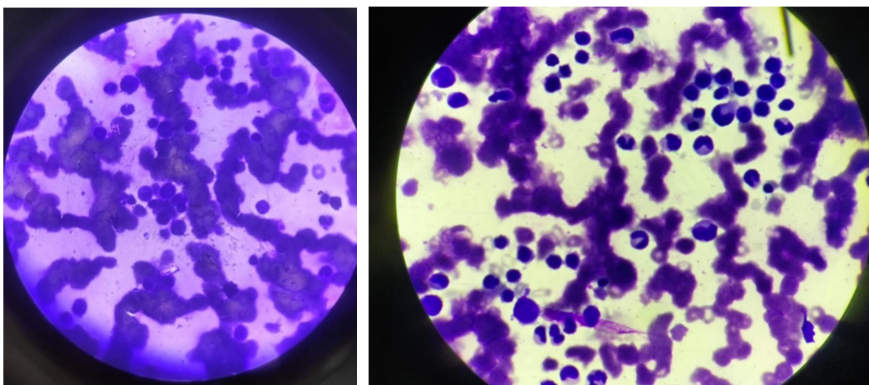
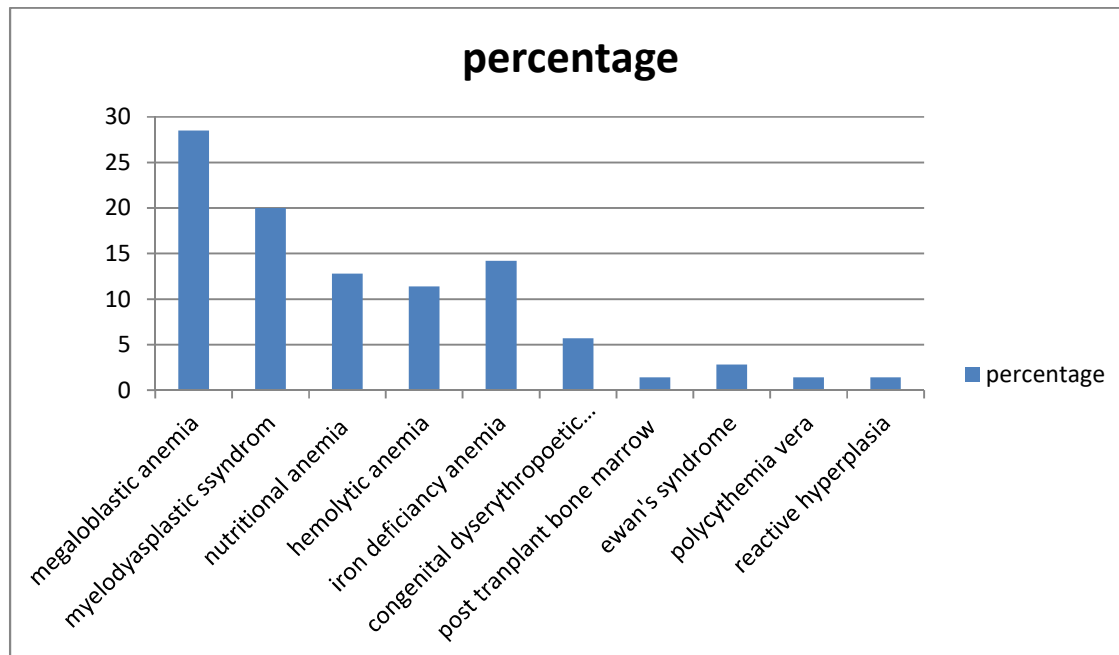


Fig 5b – erythroblasts showing cytoplasmic bridging Fig 5c – nuclear bridging

Fig 5 (a, b, c)Erythroid hyperplasia with dyserythropoiesis



Discussion :

The nutritional anemia was found in 55.5 % of the patient and was the most prevalent anemia in our studies. The sensitivity of aspiration in diagnosing anemia was 100%. Megaloblastic anemia was the most common anemia and also the cause of pancytopenia. Mahajan et al. [3] also found the similar finding in his studies.

A study by Mahfuzet al. [07] showed micronormoblastic erythroid hyperplasia in 29.5% and 10.66% in a study by Parajuli[08]. A review of 700 bone marrow aspirations in Papua New Guinea, 1977 Mar; 20 Hypercellular marrows with erythroid hyperplasia were very common. Iron stores were absent or nearly absent in almost half of the evaluable specimens. Iron deficiency anemia was less frequent. This could be due to the fact that, bone marrow examination is not routinely done to diagnose iron deficiency anemia and is treated as an outpatient basis.

Kibira et al. [12] observed AML (27.7%) and Parajuli [08] observed erythroid hyperplasia (13.3%) as common hematological disorders in patients undergoing bone marrow examination. This could be explained by the fact that cases belonged to rural, sub-urban regions and agricultural backgrounds with lower socio-economic status and lack of appropriate education; therefore, they had exposure to various risk factors co-incidentally and finally faced hematological abnormalities.

Meredith A. Lakey, MD, Animesh Pardani, MBBS, PhD, James D. Hoyer, et al. in June 2010, identified 7 PV cases with exon 12 mutations; all had hypercellular bone marrow with erythroid hyperplasia. [09] In December, 2018 M. Atchuta* , P. Premalatha et al. Dept. of Pathology, NRI Medical College, Chinakakani, Andhra Pradesh, India described among the non-malignant hematologic diseases, the most common disorder was erythroid hyperplasia followed by megaloblastic anemia, ITP, Hypoplastic marrow, dimorphic anemia, Infective pathology and Anemia of chronic disorder. [10]

Anushka Da Silva Pereira¹ et al. ,Goa Medical College, India described that among the 80 cases studied the age of the patients ranged from 4 to 80, with a slight preponderance in the males. The most common bone marrow finding was hypercellularity with erythroid hyperplasia. The most common cause for pancytopenia was megaloblastic anemia followed by aplastic anemia, subleukemic leukemia, and myelodysplastic syndrome. [11] Manjula P. Biradar , Praveen Biradar et al explained that --Micronormoblasticerythroid hyperplasia with peripheral pancytopenia was seen in 16.6% of our pancytopenia cases. [12] KajalKiranDhingra¹ ,Deepali Jain et al studied that bone marrow aspirate smears in all six cases showed hypercellular marrow with moderate erythroid hyperplasia. Myelopoiesis was normal and there was megakaryocytic hyperplasia including clusters at places with presence of immature megakaryocytes[13].

In CDA , Marrow hypercellularity and distinct erythropoietic hyperplasia were present in all patients. The relative frequency of the pertinent abnormalities of erythroblasts. Highly significant differences were found for binucleated cells, abnormalities of chromatin structures, chromatin bridges between erythroblasts, incompletely divided and large polyploid cells.[4,5] In 2019.AnuragsinghChandel, AnupItihas et al. explained that CDA I should be suspected in all children with refractory anaemia, hepatosplenomegaly, erythroid hyperplasia and features of dyserythropoiesis in marrow examination. The diagnosis of CDA I can be made from typical peripheral blood smear and bone marrow examination characteristics.[14]

Conclusion -

In conclusion, this study from diligent analysis of peripheral blood and technically appropriate specimens of aspirated bone marrow shows that majority of cases of erythroid hyperplasia are due to megaloblastic anemia followed by in decreasing frequency myelodysplastic syndrome, iron deficiency anemia, nutritional anemia { iron, vit.b12 and folate}, CDA, Evan's syndrome. However some rare causes also noted such as post transfusion bone marrow, polycythemia vera and reactive hyperplasia.

References:-

01. NaeimFaramarz; Atlas of bone and blood pathology/faramarz Naeim.-1st ed,2001.ISBN0-7216-8735-0;173.
02. Kallen, Michael E., AlinaDulau-Florea, Weixin Wang, and Katherine R. Calvo. "Acquired and germline predisposition to bone marrow failure: diagnostic features and clinical implications." In Seminars in hematology, vol. 56, no. 1, pp. 69-82. WB Saunders, 2019.
03. Mahajan, S.K. and Aundhakar, S.C., 2015. A study of the prevalence of serum vitamin B12 and folic Acid deficiency in Western maharashtra. Journal of family medicine and primary care, 4(1), p.64.
04. Wickramasinghe SN. Congenital dyserythropoieticanemias: clinical features, haematological morphology and new biochemical data. Blood Rev. 1998;12(3):178–200.
05. Heimpel H, Forteza-Vila J, Queisser W, Spiertz E. Electron and light microscopic study of the1717erythropoiesis of patients with congenital dyserythropoietic anemia. Blood. 1971;37(3):299–310.
06. Erythroid hyperplasia associated with microcytic anemia. DANIEL A. ARBER , in modern surgical pathology (second Edition) 2009

07. Anemia / other nutritional causes F.G. Huffman ,... Z.C. Shah , in Encyclopedia of Food sciences and Nutrition (second edition),2003
08. Diagnostic dilemma in Evans syndrome 2015. Harish Chandra , Smita Chandra , Anita Sharma
09. bone marrow morphologic features in polycythemia vera with JAK2 exon 12 mutations. Meredith A Lakey et al. Am J ClinPathol. 2010 jun.
10. In December, 2018 study done on” Spectrum of hematological diseases diagnosed by bone marrow examination in a tertiary care hospital” by M. Atchyuta1* , P. Premalatha2 et al. Dept. of Pathology, NRI Medical College, Chinakakani, Andhra Pradesh, India
11. Study done on “Hematological Analysis of Pancytopenia: A Prospective Study” by Anushka Da Silva Pereira1 et al. , Department of Pathology, Goa Medical College, Santa Cruz, Goa, India
12. October-December 2016, A Study of Bone Marrow Examination in Cases of Pancytopenia--- 1* 2 1 Manjula P. Biradar , Praveen Biradar , Sharada M.S 1 2 Department of Pathology, SIMS & RH, Tumkur-572101 (Karnataka) India, Consultant Pathologist, Fortis Hospital, Seshadripuram, Bangalore-560020 (Karnataka) India--
13. KajalKiran Dhingra1 , Deepali Jain1 , Shramana Mandal1 , Nita Khurana1 , Tejinder Singh1 and Naresh Gupta2 1 studied on “Evans syndrome: a study of six cases with review of literature” Department of Pathology and 2 Department of Medicine, Maulana Azad Medical College and LokNayak Hospital, Bahadur Shah ZafarMarg, New Delhi 110002, India---14,2019