

**Original article**

**The Efficacy of Two Rotary System for Gutta Percha and Sealer Removal in Root Canal Retreatment: Microscopic Versus Radiographic Evaluation – An In Vitro Study**

**Dr. Anubhuti<sup>1</sup> Dr. Rahul Maria<sup>2</sup>**

Name of the Institute/college: Rishiraj College of Dental Sciences And Research Centre , Gandhi Nagar, Bhopal, Madhya Pradesh 462036

Corresponding author: Dr. Anubhuti

---

**ABSTRACT**

**Introduction:** The main goal of nonsurgical root canal retreatment is to re-establish healthy periapical tissues. Only if the filling material cannot be removed completely and the canal negotiated to the apical foramen, can the prerequisites for successful retreatment be fulfilled.

**Aim:** To evaluate and compare the efficacy of two rotary systems for gutta percha and sealer removal and to test the hypothesis that radiographs fail to represent the real extent of remaining material on canal walls.

**Materials and Methodology:** Sixty maxillary anterior single-rooted teeth were selected. The coronal third of each root canal was prepared with peeso reamer whilst the apical two thirds were prepared with manual files. Obturation was performed using lateral condensation method. The teeth divided into five groups. The root filling material were removed with Mtwo and ProTaper retreatment files with and without chloroform. The presence of remaining filling material was evaluated radiographically and then by the microscopic evaluation of split roots.

**Result and conclusion:** From present study we conclude that, 6-11% of the canal wall remained covered with filling material. The use of solvent did not speed up the mechanized procedures. Radiographic evaluation failed to adequately and reliably detect the extent of filling material remaining on the canal walls, which was later observed by microscopic evaluation.

**Conclusion:** All methods left root canal filling material on the canal walls. Radiographic evaluation failed to detect the extent of remaining root filling material, which could only be detected using microscopy.

**Key words:** Chloroform, Microscopy, ProTaper, Radiography, Mtwo

---

**INTRODUCTION**

One of the greatest technical difficulties faced by endodontics is conventional root canal re-treatment, as the filling materials represent a mechanical barrier that can often require considerable time and effort to remove. <sup>1</sup>Endodontic retreatment is indicated when the root canal system becomes reinfected. The procedure requires the complete removal of the original root filling, further cleaning and refilling. <sup>2</sup>

An important step in retreatment is the removal of existing filling material to regain access to the entire canal, expose remnants of necrotic tissue and microorganisms and facilitate their removal. The most common root canal filling material to be removed is gutta-percha.<sup>1</sup>

However, it remains unclear what method of evaluation indicates complete removal of filling material. A variety of techniques have been used to remove root filling materials including stainless steel hand instruments alone or combined with solvents, endosonics and rotary devices.<sup>1</sup> Conventionally, the removal of gutta-percha using hand files with or without solvent can be a tedious, time-consuming process especially when the root filling material is well compacted. Therefore, the use of NiTi rotary instruments in root canal retreatment might decrease patient and operator fatigue.<sup>3</sup>

The most commonly used method to evaluate the amount of residual root filling material has been splitting the roots longitudinally to evaluate microscopically the canal walls. Radiographs are another way to evaluate residual material and are of special interest as they are the only methods that might be used clinically to evaluate root filling removal.

#### **MATERIAL & METHODOLOGY:**

This in-vitro study was conducted in the Department of Conservative Dentistry and Endodontics, Rishiraj College of Dental Science and research Centre, Bhopal, Madhya Pradesh.

Sixty maxillary anterior single-rooted teeth with straight root canals were selected. Preoperative mesio-distal (M-D) and bucco-lingual (B-L) radiographs of each root were taken.(Fig1)

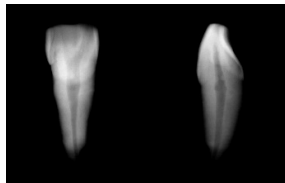


Fig 1:Pre-operative radiographs in M-D and B-L directions

The crowns were removed at the CEJ using a diamond-coated high-speed bur with air-water spray cooling. The roots were ground coronally to establish a uniform 16-mm working length for all teeth. The coronal thirds of all root canals were enlarged with Gates-Glidden drills (3, 2 and 1). The apical two-thirds were enlarged to working length using K-files and thus confirming Master apical file (MAF). Recapitulation was done.

At each instrument change, 2 mL of 3% NaOCl & saline was used for irrigation. Root canals were dried by paper points. Removal of smear layer was done by 17% EDTA. The root canals were dried with paper points. Obturation was done with lateral condensation method.

The coronal orifice of each canal was then sealed with a temporary filling material. Teeth were radiographed in B-L and M-D directions, to confirm the radiographic adequacy of root filling (Fig2)

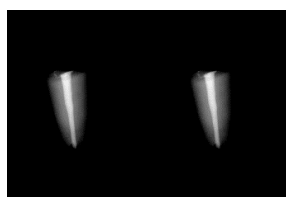


Fig 2:Radiographs showing obturation done

The teeth were stored at 37 C in 100% humidity for 1 week to allow complete setting of the sealer.

#### Retreatment procedures

The temporary fillings were removed. All specimens were then coded and randomly assigned to five groups of 15 specimens each and gutta-percha was removed using following technique.

Group 1 – ProTaper Universal retreatment files with chloroform

Group 2– ProTaper Universal retreatment files without Chloroform

Group 3– Mtwo retreatment files with chloroform

Group 4 – Mtwo retreatment files without chloroform

#### Radiographic evaluation

Each root was radiographed mesio-distally and bucco lingually after the completion of the retreatment procedure. The area covered by residual radio-opaque material in the apical two-thirds of the root canal after the retreatment procedure was evaluated using Motic Images plus 2.0 morphometric software and expressed as a percentage of the area of the root canal as seen in a given radiographic projection. The area of the apical two thirds of the root canal, as measured in either the B-L or M-D projections, was considered as 100%. The total area of radio-opaque material in the apical two-thirds in each projection was measured and expressed as a percentage of the root canal area, as seen in the corresponding projection.

#### Microscopic evaluation

The teeth were grooved vertically on their mesial and distal surfaces using a high-speed diamond bur. The teeth were then mounted on a custom made stand and split longitudinally into halves, using a chisel and a mallet. The amount of remaining root filling material was then evaluated using a Stereo microscope at 10x magnification and photographed. The total area covered by residues in the apical two-thirds of both halves was measured and expressed as per cent of the total area of the root canal in the apical two thirds of the two halves of the root canal, as seen in the digital images.

#### Statistical analysis

The areas of root filling material residues remaining on the walls, as observed either microscopically or radiographically, were used to compare the various protocols, using ANOVA with repeated measures

## RESULTS

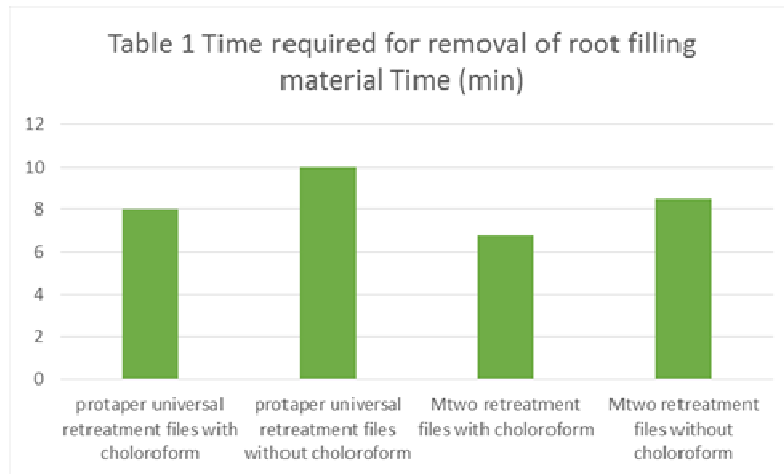
Time required for the completion of the procedure

Removal of root canal filling material using ProTaper universal retreatment files and chloroform took significantly longer than Mtwo retreatment files: 8.0( $\pm$ 2.8) min vs.6.8 ( $\pm$ 2.3) min respectively (P < 0.001, Table 1). Adding chloroform to assist with the mechanized methods prolonged the time required to accomplish the procedures. Nevertheless, the difference between procedures performed with and without chloroform was not significant.

There was also no significant difference between the time required for removal of root canal filling material using the Mtwo retreatment files as compared with the ProTaper files

	Time (min)
ProTaper universal retreatment files with chloroform	10.0±6.6
ProTaper universal retreatment files without chloroform	8.0±2.8
Mtwo retreatment files with chloroform	8.5±2.3
Mtwo retreatment files without chloroform	6.8±2.3

Table 1 Time required for removal of root filling material



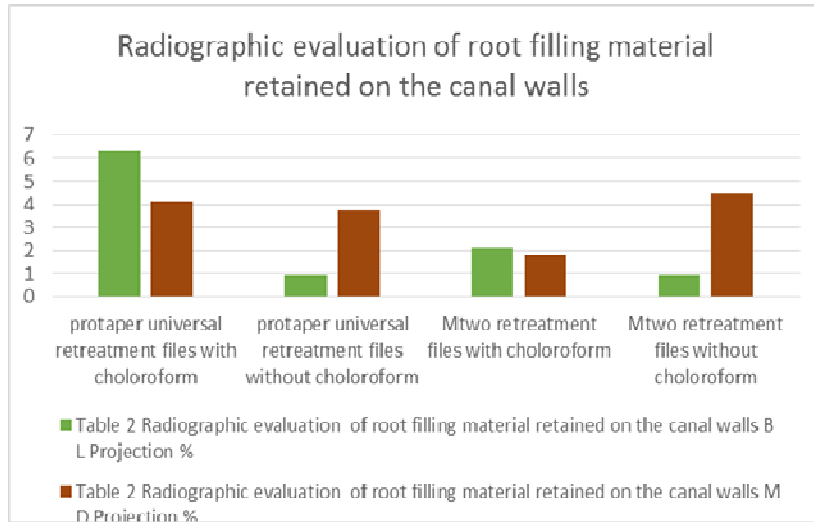
Graph 1 Time required for removal of root filling material

### Radiographic evaluation

Radiographic evaluation of root filling material left in the canal revealed no difference between the groups (Table 2).

ProTaper universal retreatment files left radio-opaque material that covered 6.3(±2.5) % of the root canal area in the B-L projection whilst the material left after the use of Mtwo retreatment files alone covered 0.9(±0.8)% (Table 2).

Table 2 Radiographic evaluation of root filling material retained on the canal walls



Graph 2:Radiographic evaluation of root filling material retained on the canal walls

**Microscopic evaluation**

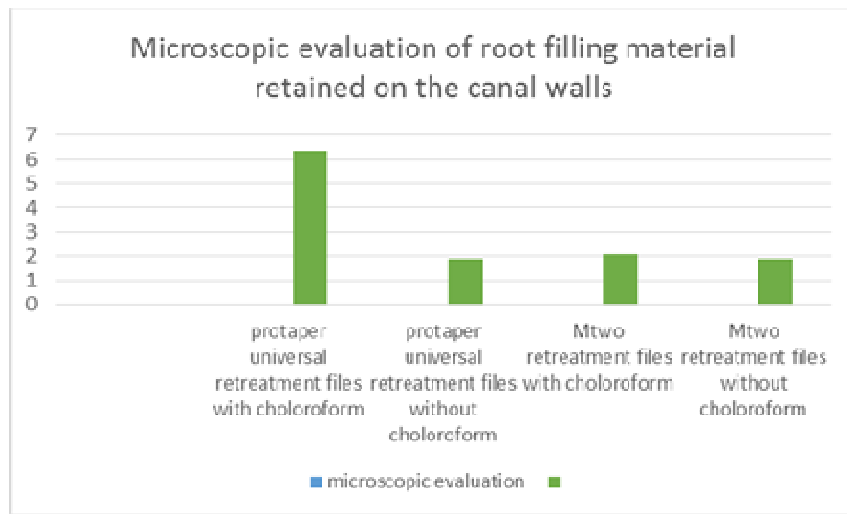
Microscopic evaluation revealed substantial amounts of root filling residues in all groups with no difference amongst them (Table 3). The canals treated with ProTaper universal retreatment files used with or without chloroform presented with 6.4(±3.6) % 1.9(±1.7) %, canal walls covered with residues, respectively and of the canal wall covered with residues.

	B- L Projection %	M-D Projection %
ProTaper universal retreatment files with chloroform	6.3±2.5	4.1±1.5
ProTaper universal retreatment files without chloroform	0.9±0.8	3.7±2.9
Mtwo retreatment files with chloroform	2.1±1.6	1.8±1.7
Mtwo retreatment files without chloroform	.9±.8	4.5±2.4

Those in which Mtwo retreatment files was used with or without chloroform had 2.1(±1.4) % and 1.9(±1.9) % the canal walls covered with residues, respectively (Table 3)

	Per cent of the canal wall covered with residue
ProTaper universal retreatment files with chloroform	6.4±3.6
ProTaper universal retreatment files without chloroform	1.9±1.7
Mtwo retreatment files with chloroform	2.1±1.4
Mtwo retreatment files without chloroform	1.9±1.9

**Table 3** Microscopic evaluation of root filling material retained on the canal walls



**Graph 3:** Microscopic evaluation of root filling material retained on the canal wall

A difference between radiographic and microscopic examination

Differences between B-L radiographs and microscopic examination were found in 33 of 50 samples (66%, Table 4). Similarity between B-L radiographs and microscopic examination was found in only 17/50 cases (34%). In 32/50 of the cases (64%), the residue scores were higher when submitted to microscopic compared with B-L radiographic examination. Furthermore, in 11 of the 50 cases (22%), residues labeled ‘clean’ on the B-L radiograph were instead labeled ‘Heavy’ when the same root canals were examined microscopically.

	R<M	R=M	R>M
ProTaper universal retreatment files with chloroform	8/15	0/15	7/15
ProTaper universal retreatment files without chloroform	4/15	0/15	11/15
Mtwo retreatment files with chloroform	10/15	0/15	5/15
Mtwo retreatment files without chloroform	10/15	1/15	4/15

**Table 4** Difference between B-L radiology and microscopic evaluation

B-L, bucco-lingual; R < M, Radiographic evaluation revealed less retained root canal material than did microscopy; R = M, Radiography in agreement with microscopy; R > M, Radiographic evaluation revealed more retained root canal material than did microscopy.

## DISCUSSION

Complete removal of pre-existing filling material from canals is a prerequisite for successful nonsurgical root canal retreatment (Schirrmeister et al. 2006c). This procedure can uncover residual necrotic tissues or bacteria that may be responsible for persistent periapical inflammation, and allow further cleaning and refilling of the root canal system (Stabholz& Friedman 1988, Schirrmeister et al. 2006d).<sup>16</sup>

In the presence of an endodontic failure, a non-surgical approach to the root canal system is preferable to a surgical procedure. The variability of the outcome of endodontic retreatment is related to various factors: the patient's age and types of teeth treated, the presence of alterations in the natural course of the root canals, the possibility of removing the coronal restorations to access the pulp chamber, the techniques used to remove the existing filling materials.<sup>45</sup>

Removal of filling material is an important factor in root canal retreatment because it allows for chemo mechanical re-instrumentation and re-disinfection of the root canal system, to date, complete removal of filling material has not been demonstrated to ensure success of root canal retreatment, and that remaining material will cause the retreatment to fail. However, removal of as much filling material as possible from inadequately prepared and filled root canal systems would appear to be essential to uncover remaining necrotic tissue or bacteria that may be responsible for periapical inflammation and persistent disease.<sup>45</sup>

Complete removal of these residues may increase the success of endodontic retreatment. Several reports have proposed techniques for removing gutta-percha and sealer from root canals. Various methods have been used in endodontic research to evaluate the efficacy of root filling removal including radiography and digitized images (Masiero& Barletta 2005, de CarvalhoMaciel&ZaccaroScelza 2006, Schirrmeister et al. 2006, Cunha et al. 2007, Gergi&Sabbagh 2007, Gu et al. 2009, Unal et al. 2009). However, they only provide two-dimensional information for a three-dimensional (3D) object. Other techniques include splitting the teeth longitudinally and visualizing them using a stereomicroscope or by using images obtained with a digital camera and using image analyzer software (de Oliveira et al. 2006, Ezzie et al. 2006, Giuliani et al. 2008, So et al. 2008, Tasdemir et al. 2008b), or making teeth transparent (Schirrmeister et al. 2006, Tasdemir et al. 2008a).<sup>2</sup>

In the current study ProTaper retreatment files were chosen as they save time and show lesser tendency of straightening, Zipping, ledging or perforation. The better performance of Pro Taper Universal retreatment files may be attributable not only to their design but also due to their cutting action. They have three progressive tapers and lengths. These features may enable the retreatment instruments to cut not only GP hut also a superficial layer of dentine during root filling removal. These files are used with crown-down technique until the working length is reached<sup>45</sup>. Similar

results were found in a study done by T.Tasdemir et al. where Pro Taper, H file, Mtwo and R-endo were used.<sup>46</sup>

The other system used in the present study was the Mtwo instruments which were elected as they have an S-shaped cross-section. An increasing pitch length in the apical-coronal direction and non-cutting safety tip. Therefore these instruments are characterized by a positive rate angle with two cutting edges which are claimed to cut dentine effectively. The initial reports concluded that Mtwo was successful in root canal retreatment as they have sharp blades. It is possible to cut through the canal and reach apical end-point whilst bypassing gutta-percha<sup>46</sup>

Adjunctive solvents like Chloroform effectively dissolve gutta-percha and allow quicker access to the working length and help to maintain the original route by facilitating instrumentation inside the obturation mass.<sup>46</sup> Chloroform was used as a solvent due to its known capacity for dissolving gutta-percha and its limited toxicity when used clinically (McDonald & Vire 1992). This solvent has been used in the majority of studies that evaluated gutta-percha and sealer removal using a similar methodology to the one employed in this study. (Mello et al 2009, Kfir et al 2012, Mollo et al 2012)<sup>5</sup> In the present study, the teeth were split longitudinally into halves, using a chisel and a mallet. The amount of remaining root filling material was then evaluated using a Stereo microscope at 10x magnification and photographed. The total area covered by residues in the apical two-thirds of both halves was measured and expressed as per cent of the total area of the root canal in the apical two thirds of the two halves of the root canal.

In this study in Group I when ProTaper universal retreatment files with chloroform were used it took significantly longer time ( $8.0 \pm 2.8$  min) than in Mtwo retreatment files when used with chloroform in Group III ( $6.8 \pm 2.3$  min) ( $P < 0.001$ ) (Table 1 Graph 1) Adding chloroform prolonged the time required to accomplish the procedures. As the chemically softened gutta-percha forms a fine layer and it adheres to the canal walls (Sae-Lim et al). This makes the removal of filling material even more difficult and time-consuming.<sup>5</sup>

In this study in In Group II ProTaper universal retreatment files were used without using chloroform ( $8.5 \pm 2.8$  min) took longer time and in Group IV- Mtwo retreatment files without chloroform took less time ( $6.8 \pm 2.3$  min) in removing gutta percha. ( $P < 0.001$ , (Graph 1, Table 1) Radiographic evaluation of root filling material left in the canal revealed no significant difference between the groups. In Group I when ProTaper universal retreatment files were used with chloroform left radio-opaque material that covered  $6.3 (\pm 2.5)$  % of the root canal area in the B-L projection and  $4.1 (\pm 1.5)$  % in M-D Projection whilst in Group III- Mtwo retreatment files were used with chloroform, the material left radio-opaque material that covered  $0.9 (\pm 0.8)$  % in B-L projection and  $3.7 (\pm 2.9)$  % in M-D Projection (Graph 2, Table 2).

In Group II when ProTaper universal retreatment files were used without chloroform, it left radio-opaque material that covered  $0.9 (\pm 0.8)$  % in B-L projection and  $2.9 (3.7)$  % in M-D Projection. In Group IV when Mtwo retreatment files were used without chloroform, it left radio-opaque material that covered  $0.9 (\pm 0.8)$  % in B-L projection and  $4.5 (\pm 2.4)$  % in M-D Projection (Graph 2, Table 2).



Microscopic evaluation revealed substantial amounts of root filling residues in all groups with no difference amongst them. In this study In Group I when ProTaper universal retreatment files were used with chloroform, the canal wall presented with 6.4( $\pm$ 3.6) % canal walls covered with residues and in Group III- Mtwo retreatment files with chloroform presented with 1.9( $\pm$ 1.7) % the canal wall covered with residues. (Graph 3, Table 3)

In Group II when ProTaper universal retreatment files were used without chloroform, presented with 2.1( $\pm$ 1.4) % the canal wall covered with residues and In Group IV when Mtwo retreatment files were used without chloroform the canal wall covered with residues presented with 1.9( $\pm$ 1.9) % the canal wall covered with residues. (Graph 3, Table 3)

When comparing the two NiTi instruments, it can be explained by the fact that the Mtwo retreatment files work on crown-down approach eliminates the filling material from the coronal third more effectively than the ProTaper retreatment system.<sup>46</sup> When used Mtwo NITI instruments for retreatment, the procedure can be completed more easily, quickly, and predictably but effective cleaning of the entire root canal is still challenging. Further studies are needed to assess the efficacy, maintenance of original canal morphology and safety of NiTi rotary instruments during retreatment and complicated root canal anatomy.

#### **CONCLUSION:**

In the present study, none of the techniques were efficient in removing all the obturating material from the canals. Mtwo retreatment files left significantly lesser gutta-percha and sealer in the root canals than the other systems. There were stastically significant difference between ProTaper retreatment files and Mtwo retreatment files. The Mtwo retreatment files without chloroform proved to be more efficient than ProTaper universal retreatment files. Radiography alone failed to detect all remaining root canal filling material, which could be detected using stereo microscopy.

#### **REFERENCES**

1. F. BarattoFilho, E. L. Ferreira & L. F. Fariniuk. Efficiency of the 0.04 taper Pro File during the retreatment of gutta-percha-filled root canals. *International Endodontic Journal*, 35, 651-654, 2002
2. N. Imura, A. S. Kato, G.-I. Hata, M. Uemura, T. Toda & F. Weine. A Comparison of the relative efficacies of four hand and rotary instrumentation techniques during endodontic retreatment. *International Endodontic Journal*, 33, 361–366, 2000
3. K. Marfisi, M. Mercade1, G. Plotino, F. Duran-Sindreu1, R. Bueno& M. Roig. Efficacy of three different rotary files to remove gutta-percha and Resilon from root canals. *International Endodontic Journal*, 43, 1022–1028, 2010
4. J. F. Schirrmeister, P. Hermanns, K. M. Meyer, F. Goetz & E. Hellwig. Detectability of residual Epiphany and gutta-percha after root canal retreatment using a dental operating microscope and radiographs – an ex vivo study. *International Endodontic Journal*, 39, 558–565, 2006.
5. Marcos de Azevêdo Rios, Alexandre MascarenhasVilela, Rodrigo Sanches Cunha, Rafael Cortez Velasco, Alexandre Sigrist De Martin, Augusto Shoji Kato, Carlos Eduardo da Silveira Bueno. Efficacy of 2 Reciprocating Systems Compared with a Rotary Retreatment System for Gutta-percha Removal. *Journal of endodontics*-Volume 40, Issue 4, Pages 543–546,2014

6. S. Zuolo, J. E. Mello Jr, R. S. Cunha, M. L. Zuolo & C. E. S. Bueno<sup>1</sup> .Efficacy of reciprocating and rotary techniques for removing filling material during root canal retreatment. *International Endodontic Journal*, 46,947-953, 2013
7. A. Mollo, G. Botti, N. Principi Goldoni, E. Randellini, R. Paragliola, M. Chazine, H. F. Ounsi & S. Grandini. Efficacy of two Ni-Ti systems and hand files for removing gutta-percha from root canals. *International Endodontic Journal*, 45, 1–6, 2012
8. I. Abramovitz, S. Relles-Bonar<sup>1</sup>, B. Baransi & A. Kfir. The effectiveness of a self-adjusting file to remove residual gutta-percha after retreatment with rotary files. *International Endodontic Journal*, 45, 386–392, 2012
9. R. P. Hussne, L. C. Braga, F. L. C. V. Berbert, V. T. L. Buono<sup>3</sup> & M. G. A. Bahia. Flexibility and torsional resistance of three nickel–titanium retreatment instrument systems. *International Endodontic Journal*, 44, 731–738, 2011
10. P. Zaslansky, P. Fratzl, A. Rack, M-K. Wu, P. R. Wesselink & H. Shemesh. Identification of root filling interfaces by microscopy and tomography methods. *International Endodontic Journal*, 44, 395–401, 2011
11. G. Fenoul, G. D. Meless & F. Peerez .The efficacy of R-Endo rotary NiTi and stainless steel hand instruments to remove gutta-percha and Resilon. *International Endodontic Journal*, 43, 135–141, 2010
12. Clovis Monterio Bramanate, Natasha Siqueira Fidelis, Tatiana Santos Assumpcao, Norberti Bernardineli, Roberto Brando Garcia, Alexander Silva Bramante And Ivaldo Gomes De Moraes Heat release ,time required, and cleaning ability of Mtwo R and Pro Taper universal retreatment systems in the removal of filling material. *Journal of endodontics* Volume 36, number 11, November 2010
13. M. J. Roggendorf, M. Legner, J. Ebert, E. Fillery, R. Frankenberger & S. Friedman .Micro-CT evaluation of residual material in canals filled with Activ GP or GuttaFlow following removal with NiTi instruments .*International Endodontic Journal*, 43, 200–209, 2010
14. S. D. Horvath, M. J. Altenburger, M. Naumann, M. Wolkewitz & J. F. Schirrmeister Cleanliness of dentinal tubules following gutta-percha removal with and without solvents: a scanning electron microscopic study. *International Endodontic Journal*, 42, 1032–1038, 2009
15. B. Aydin, T. Kose & M. K. C als, kan .Effectiveness of HERO 642 versus Hedstrom files for removing gutta-percha fillings in curved root canals: an ex vivo study. *International Endodontic Journal*, 42, 1050–1056, 2009
16. G. Celik Unal, B. Ureyen Kaya, A. G. Tac & A. D. Kececi. A comparison of the efficacy of conventional and new retreatment instruments to remove gutta-percha in curved root canals: an ex vivo study. *International Endodontic Journal*, 42, 344–350, 2009
17. L.-S. Gu, J.-Q. Ling, X. Wei & X.-Y. Huang. Efficacy of ProTaper Universal rotary retreatment system for gutta-percha removal from root canals. *International Endodontic Journal*, 41, 288–295, 2008
18. Mohammad Hammad, Alison Qualtrough, and Nick Silikas .Three-dimensional Evaluation of Effectiveness of Hand and Rotary Instrumentation for Retreatment of Canals Filled with Different Materials. *Journal Of Endodontics* —Volume 34, Number 11, November 2008
19. Tasdemir T1, Er K, Yildirim T, Celik D. Efficacy of three rotary NiTi instruments in removing gutta-percha from root canals. *International Endodontic Journal* Volume 41, Issue 3, pages 191–196, March 2008
20. Francesco Somma, Giuseppe Cammarota, Gianluca Plotino, Nicola M. Grande, and Cornelis H. Pameijer. The Effectiveness of Manual and Mechanical Instrumentation for the Retreatment of Three Different Root Canal Filling Materials. *Journal Of Endodontics* —Volume 34, Number 4, April 2008

21. Valentina Giuliani Roberto Cocchetti, and Gabriella Pagavino. Efficacy of ProTaper Universal Retreatment Files in Removing Filling Materials during Root Canal Retreatment. *Journal Of Endodontics* — Volume 34, Number 11, November 2008
22. Abdulhamied Y. Saad, Solaiman M. Al-Hadlaq, and Nasser H. Al-Katheeri. Efficacy of Two Rotary NiTi Instruments in the Removal of Gutta-Percha during Root Canal Retreatment. *Journal Of Endodontics*— Volume 33, Number 1, January 2007
23. E. Kosti, T. Lambrianidis, N. Economides & C. Neofitou .Ex vivo study of the efficacy of H-files and rotary Ni–Ti instruments to remove gutta-percha and four types of sealer. *International Endodontic Journal*, 39, 48–54, 2006
24. Jorg F. Schirrmeister, , Karl-Thomas Wrbas, , Katharina M. Meyer, Markus J. Altenburger, and Elmar Hellwig. Efficacy of Different Rotary Instruments for Gutta-Percha Removal in Root Canal Retreatment. *Journal of Endodontics* Volume 32, Number 5, May 2006
25. A. C. de Carvalho Maciel & M. F. Zaccaro Scelza. Efficacy of automated versus hand instrumentation during root canal retreatment: an ex vivo study. *International Endodontic Journal*, 39, 779–784, 2006
26. J. F. Schirrmeister, K. M. Meyer, P. Hermanns, M. J. Altenburger & K.-T. Wrbas Effectiveness of hand and rotary instrumentation for removing a new synthetic polymer-based root canal obturation material (Epiphany) during retreatment. *International Endodontic Journal*, 39, 150–156, 2006
27. O. Zmener, C. H. Pameijer & G. Banegas. Retreatment efficacy of hand versus automated instrumentation in oval-shaped root canals: an ex vivo study. *International Endodontic Journal*, 39, 521–526, 2006
28. Elie Ezzie, Alex Fleury, Eric Solomon, Robert Spears, Jianing He. Efficacy of Retreatment Techniques for a Resin-Based Root Canal Obturation Material. *Journal of Endodontics* — Volume 32, Number 4, April 2006
29. Daniel Pinto de Oliveira, Vicente Baroni Barbizam, Martin Trope, and Fabricio B. Teixeira Comparison Between Gutta-Percha and Resilon Removal Using Two Different Techniques in Endodontic Retreatment. *Journal Of Endodontics*—Volume 32, Number 4, April 2006
30. Schirrmeister JF, Wrbas KT, Schneider FH, Altenburger MJ, Hellwig E. Effectiveness of a hand file and three nickel-titanium rotary instruments for removing gutta-percha in curved root canals during retreatment. *Oral Surg Oral Med Oral Pathol Oral Radiol Endod.* Apr; 101(4):542-7 2006.
31. A. V. Masiero & F. B. Barletta Effectiveness of different techniques for removing gutta-percha during retreatment. *International Endodontic Journal*, 38, 2–7, 2005
32. M. HULSMANN & V. BIUHM. Efficacy, cleaning ability and safety of different rotary NiTi instruments in root canal retreatment. *International Endodontic Journal*, 37, 468–476, 2004
33. D Viducic, S Jukic, Z Karlovic, Z Bozic. Removal of gutta-percha from root canals using an Nd: YAG laser. *International Endodontic Journal* Volume 36, Issue 10, 670–673, October 2003
34. Kefah M. Barrieshi-Nusair. Gutta-percha Retreatment: Effectiveness of Nickel-Titanium Rotary Instruments Versus Stainless Steel Hand Files. *Journal Of Endodontics*—Volume 28, Issue 6, Pages 454–456
35. L. V. Betti & C. M. Bramante Quantec SC rotary instruments versus hand files for gutta-percha removal in root canal retreatment. *International Endodontic Journal*, 34, 514–519, 2001
36. M. HULSMANN & S. S. TOTZ Efficacy, cleaning ability and safety of different devices for gutta-percha removal in root canal retreatment. *International endodontic journal*, 30, 227–233, 1997
37. Mark N. McDonald, Donald E. Vire. Chloroform in the endodontic operatory. *Journal Of Endodontics*— Volume 18, Issue 6, 301–303, 1992
38. Gary J. Kaplowitz. Evaluation of gutta-percha solvents. *Journal Of Endodontics*—Volume 16, Issue 11, Pages 539–540, 1990

39. Dennis J. Wourms, A. Dean Campbell, M. Lamar Hicks, MScorrespondence1, George B. Pelleu, Alternative solvents to chloroform for gutta-percha removal. *Journal Of Endodontics*—Volume 16, Issue 5, Pages 224–226, 1990
40. ElieEzzie, Alex Fleury, Eric Solomon, Robert Spears, and Jianing He. Efficacy of Retreatment Techniques for a Resin-Based Root Canal Obturation Material. *JOE* — Volume 32, Number 4, April 2006
41. Kerem-EnginAkpınar ,DemetAltunbaş, AlperKuştarc. The efficacy of two rotary NiTi instruments and H-files to remove gutta-percha from root canals. *Med Oral Patol Oral Cir Bucal*. May 1; 17 (3):e506-11 2012.
42. Julia Elis Johann, JosuéMartos, Luiz Fernando Machado Silveira, Francisco Augusto Burkert Del Pino .Use Of Organic Solvents in Endodontics: A Review. *Clin. Pesq. Odontol., Curitiba*, v.2, n.5/6, p. 393-399, jul./d 2006
43. Chiara Pirani, Gian Andrea Pelliccioni, Silvia Marchionni, LucioMontebugnoli, Gabriela Piana, and Carlo Prati. Effectiveness of Three Different Retreatment Techniques in Canals Filled With Compacted Gutta-Percha or Thermafil: A Scanning Electron Microscope Study. *JOE* — Volume 35, Number 10, October 2009
44. Khaldoun AL-Naal, Mohammad Rekab Effect of passive ultrasonic irrigation on the removal of root canal filling during Retreatment procedures. *IAJD Vol. 4 – Issue 2*
45. Emreiriboz a and heenasazakovecoglu, comparison of protape and Mtwo retreatment systems in the removal of resin based root canal obturation materials during retreatment ,*AustEndod J*;40:6-11, 2014
46. Seema dixit,Pravinkumar,Supriyaagarwal,Ashutosh dixit, Comparative evaluation of effectiveness of ProTaper universal retreatment and Mtwo systems. *Indian journal of dental sciences* September,issue.3,vol:6,2014