

Original article

Nasogastric tube insertion revisited: An RCT of three techniques

Langpoklakpam Chaoba Singh , Shikhar More , Thanigai Arasu Elangovan , Dhananjaya BD ,
Nirmeen Fatima

Department of Anaesthesiology, New OT complex , Regional Institute of Medical Sciences , Lamphelpat, Imphal ,
Manipur – 795004

Corresponding author: Langpoklakpam Chaoba Singh

Abstract

Background: Insertion of nasogastric tubes is common in critically ill patients, but successful placement is often a challenge. Various techniques have been described in literature to aid in the insertion of nasogastric tubes, with varying success rates and no standardised technique exists. We hypothesised that a combination of guidewired nasogastric tube with anterior displacement of the cricoid cartilage may be superior to either of them alone.

Methods: 300 patients requiring ICU admission and nasogastric intubation were enrolled and randomised into three groups. Manual anterior displacement of the larynx was used as aid in the control group, and was compared with the use of a guidewire, and the combination of guidewire and cricoid displacement. Success rate in first and second attempts, time taken for successful placement and complications were observed and compared.

Results: There were no differences in demographic parameters in the three groups. First attempt success rate was significantly higher and total time taken was significantly shorter when both guidewire and cricoid displacement were used together as compared to cricoid displacement alone. The use of guidewire alone also had higher overall and first attempt success rate as compared to cricoid displacement technique.

Conclusion: Use of a guidewire in conjunction with anterior displacement of cricoid is a better technique compared to either of them alone.

Keywords: Nasogastric, tube, technique, cricoid, guidewire

Introduction

Nasogastric tube insertion is indicated for various reasons in the ICU, especially with the recent emphasis on early enteral feeding. Although it is thought of as a basic procedure, it can sometimes pose significant challenges even for the most experienced physician. Various factors contribute to the difficult nasogastric intubation like unconsciousness, inability to swallow, endotracheal tube in situ, head position, stiffness of the nasogastric tube etc. The most common site of impaction has found to be the pyriform sinus and the arytenoids cartilages.¹ Consequently various techniques have been described to aid the difficult intubation which include external manipulation of

the larynx², head positioning manoeuvres like neck flexion and lateral neck pressure¹, use of guidewires^{3,4}, stiffening of the nasogastric tube⁵ etc. These techniques have been often proven to be superior to the blind unaided method of insertion, but no standard approach exists which can be suitable for all patients. The ‘reverse Sellick’s manoeuvre’ or anterior displacement of the cricoid cartilage has been described and validated as a useful adjunct.⁶ There are very few studies which have evaluated the use of a stylet or guidewire in conjunction with anterior displacement of the larynx.

We hypothesised that a combination of guidewired nasogastric tube with anterior displacement of the

cricoid cartilage may be superior to either of them alone.

Materials and methods

After obtaining clearance from the institutional ethics committee, and obtaining an informed written consent from the family members, 300 patients requiring ICU admission and nasogastric intubation were enrolled into the study. The inclusion criteria were age between 18 and 65, GCS \leq 8, endotracheal tube in place and stable haemodynamic parameters. These patients were then randomised into three groups according to computer generated table of random numbers. In Group C, the cricoid cartilage of the patients were gently displaced anteriorly and a lubricated 14 F NG tube (Romolene, Romsons Industries, India) without guidewire was introduced through the selected nostril with head in neutral position. In Group W, a PTFE ureteral guidewire (0.89 mm, Terumo Corporation, Japan) was introduced into the 14F NG tube until it reached the tip of the tube. The NG tube was then passed through the selected nostril without external laryngeal manipulation and the head in neutral position. In Group B, both these techniques were combined and a 14 F NG tube was inserted with the guidewire and anterior displacement of the cricoid.

Nasal patency was ascertained by observing condensation of vapour from the expired air over a cold metal spatula. The nasogastric insertion procedure was carried out by third year anaesthesia

residents judged to be proficient in the said techniques.

The procedure was said to be successful after smooth passage of the tube and confirmed by auscultation. The time taken from the insertion of the tube into the nostril to auscultatory confirmation was measured using a stop watch. Number of attempts taken for successful insertion of was also documented. If the initial attempt was unsuccessful, the tube was withdrawn, cleaned and re-inserted. The technique was considered a failure if nasogastric intubation was not accomplished after two attempts. The NG tube was then inserted using a laryngoscope and Magill's forceps. Complications like bleeding and kinking were also noted.

All data was tabulated and analysed using SPSS for windows version 21 (IBM Corp, USA).

Results

There were no differences among the three groups in terms of demographic data (age and gender). The overall success rate after two attempts in Group B was 97% which was significantly greater than that of Group C, 82% ($p = 0.002$). The success rate in Group W was 90%, which was not significantly different from either Group B or C. Successful nasogastric intubation was achieved in the first attempt in 64% of the patients in Group C, significantly lower than that achieved in Group W (84% , $p = 0.002$ compared to Group C) and Group B (88%, $p = 0.000$ compared with Group B).

Medworld asia

Dedicated for quality research

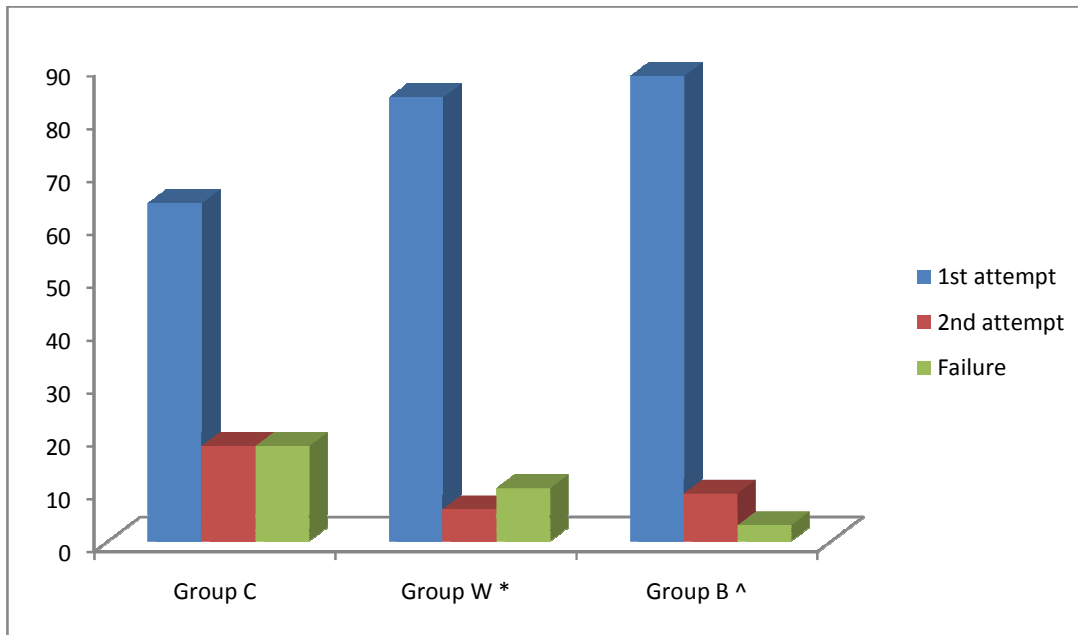


Figure 1. Success Rates in the three groups, Group C = control, Group W = guidewire, Group B = both guidewire + cricoid displacement

* - p value 0.002 and 0.2 respectively for successful insertion in first attempt and overall success rate compared to group C

^ - p * - p value 0.000 and 0.002 respectively for successful insertion in first attempt and overall success rate compared to group C

The total time taken for successful NG intubation in Group C was 60.23 ± 20.88 seconds, which was significantly longer than Group S (42.86 ± 10.06 sec, $p = 0.00$) and Group B (39.25 ± 9.62 sec, $p=0.00$). The incidence of bleeding and kinking were not significantly different among the three groups.

	Group C	Group S	Group B
Duration of insertion (s)	60.23 ± 23	42.86 ± 10.06 *	39.25 ± 9.62 ^
Bleeding	3	7	7
Kinking	7	2	1

Table 1. Total duration of insertion and complications

* - p value = 0.000 compared to group C

^ p value = 0.000 compared to group C

Discussion

Unaided nasogastric tube insertion in unconscious, intubated patients is known to have failure rates of upto 50 % in the first attempt.⁷ Incidence of complications like bleeding and haemodynamic disturbance increases with subsequent attempts.⁸ Various factors are responsible for the difficulties associated with NG tube insertion in critically ill

patients. The ability to swallow on instruction is absent in unconscious patients and in those with neuro-muscular diseases. The cuffed endotracheal tube in mechanically ventilated patients may act as a physical obstruction to the advancement of the tube in the oesophagus. During blind unaided NG tube insertion, the frequent sites of impaction are the pyriform sinuses, arytenoids cartilages and the

posterior pharyngeal wall.¹ Flexion of the neck, keeps the NG tube proximal to the posterior wall and helps in smooth passage into the oesophagus.² This too is not feasible in critically ill patients especially with head and neck trauma and raised intracranial pressure. The 'reverse Sellick's manoeuvre' or anterior displacement of the cricoids cartilage can be performed with the head in neutral position. It displaces the sites of impaction and opens the oesophagus wide for easy insertion of the tube.^{1,6} We chose this technique in our control group as it is widely popular among intensivists and anaesthetists and any demonstration of superiority to this technique would carry more meaning as compared to blind unaided insertion. Commercially available NG tubes are made of polyurethane, which are atraumatic and soften on exposure to body temperature.⁹ Several non-apposing eyes at the distal end has been thought to make the tube more prone to kinking.¹⁰ These tubes also retain the coiled shape of commercial packaging which may promote coiling in the mouth and pharynx.¹¹ 'Stiffening' of the NG tube using a variety of techniques has been shown to facilitate the NG intubation process. Cooling or freezing⁵ of the tube, a slipknot with an endotracheal intubation stylet¹⁰ and of various other guidewires and stylets^{2, 12,13} have all been used to achieve the same purpose. We used a ureteral stylet to impart stiffness to the NG tube to aid in the insertion.

References

1. Ozer S and Benumof JL. Oro- and nasogastric tube passage in intubated patients: fiberoptic description of where they go at the laryngeal level and how to make them enter the esophagus. *Anesthesiology* 1999; 91(1): 137–143.
2. Ghatak T, Samanta S and Baronia AK. A new technique to insert nasogastric tube in an unconscious intubated patient. *N Am J Med Sci* 2013; 5:68–70.
3. Appukutty J and Shroff PP. Nasogastric tube insertion using different techniques in anesthetized patients: a prospective, randomized study. *Anesth Analg* 2009; 109: 832–835.

The overall success rate with the reverse Sellick's manoeuvre in our study was 82%, which is similar to as described previously.⁶ Studies using guidewire techniques have described a success rate of 87%,¹² and similar observations have been made in the present study (90%). There are very few studies which have made use of the reverse Sellick's manoeuvre in conjunction with the guidewire technique. Kirtania et al¹³ have recently compared the combination of the reverse Sellick's and guidewire with neck flexion and lateral neck pressure. They observed a success rate of 99% with the combination technique which has been replicated in our study (97%). However, the combination of reverse Sellick's manoeuvre and guidewire has probably never been compared with either of them alone. It is observed in this study that anterior displacement of the cricoid when combined with a guidewire has significantly higher success rate with a shorter duration of procedure than cricoids displacement alone. Also compared to the guidewire alone, the combination technique had better success rate and shorter duration, although statistical significance could not be demonstrated. Thus, the combination of the reverse Sellick's manoeuvre with a guidewire is a better, safe and reliable technique of NG tube insertion in critically ill patients. These findings can be easily extrapolated to other situations like patients under anesthesia, unconscious patients and those with head and neck trauma.

4. Mahajan R, Gupta R and Sharma A. Insertion of a nasogastric tube using a modified ureteric guide wire. *J Clin Anesth* 2009; 21: 387–388.
5. Flegar M and Ball A. Easier nasogastric tube insertion. *Anaesthesia* 2004; 59: 197.
6. Parris WC. Reverse Sellick maneuver. *Anesth Analg* 1989; 68: 423.
7. Mahajan R, Gupta R. Another method to assist nasogastric tube insertion. *Can J Anaesth* 2005;52:652-3.
8. Chun DH, Kim NY, Shin YS, Kim SH. A randomized, clinical trial of frozen versus standard nasogastric tube placement. *World J Surg.* 2009;33:1789–92.
9. Boyes RJ, Kruse JA. Nasogastric and nasoenteric intubation. *Crit Care Clin.* 1992;8:865–78.
10. Tsai YF, Luo CF, Illias A, Lin CC, Hu HP. Nasogastric tube insertion in anesthetized and intubated patients: A new and reliable method. *BMC Gastroenterol.* 2012;12:99.
11. Kumar P, Girdhar KK, Anand R, Dali JS, Sheshadri TR. Nasogastric tube placement in difficult cases: A novel and simple maneuver. *J Anaesth Clin Pharmacol.* 2005;21:429–34.
12. Mandal MC, Dolai S, Ghosh S, Mistri PK, Roy R, Basu SR, Das S. Comparison of four techniques of nasogastric tube insertion in anaesthetised, intubated patients: A randomized controlled trial. *Indian J Anaesth* 2014;58:714-8
13. Kirtania J, Ghose T, Garai D, et al. Esophageal guidewire-assisted nasogastric tube insertion in anesthetized and intubated patients: a prospective randomized controlled study. *Anesth Analg* 2012; 114: 343–348.