

## Case Report

# Lymphoma or Disseminated MDR Tuberculosis with DIC: A Clinician's diagnostic dilemma

Kavita S Joshi, Smrati A Bajpai, Gajanan A Panandikar, A R Pazare

Seth G S Medical College, Parel, Mumbai, Maharashtra, India 400012.

Corresponding author: Dr Kavita S Joshi

---

### Abstract:

India is among one of the high burden country for tuberculosis, 1 609 547 new and relapse cases: 95 709 (6%) cases aged under 15 years in year 2014. A 13 year old boy had fever, weight loss, loss of appetite since 5 months and increasing dyspnoea from NYH-A class one to four over span of two months. A 13 year old boy had fever, loss of appetite since 5 months. Weight loss and increasing dyspnoea from NYHA class one to four over span of two months. He had swelling of feet since 15 days. On examination patient was in acute respiratory distress syndrome (ARDS) with shock, he had visible veins on chest and left medial forearm. Patient had pancytopenia. Liver function tests revealed transaminitis with normal bilirubin which was attributed to Antituberculous therapy (ATT) toxicity. His DIC workup was positive with high D-dimer, FDP and low fibrinogen. His serum Ferritin levels were done to rule out Hemo-phagocytic syndrome and was 8000 ng/ml (normal -70-435 ng/ml) Triglyceride normal, LDH – normal. Bone marrow examination was performed which revealed Myelodysplastic changes mostly reactive in nature with no granuloma.

---

### Introduction:

India is among one of the high burden country for tuberculosis, 1 609 547 new and relapse cases: 95 709 (6%) cases aged under 15 years in year 2014. A 13 year old boy had fever, weight loss, loss of appetite since 5 months and increasing dyspnoea from NYH-A class one to four over span of two months. He had swelling of feet since 15 days and had pancytopenia which on bone marrow examination revealed myelodysplastic changes of reactive nature. Patient was empirically started on anti-tuberculosis treatment but developed hepatitis hence anti-tuberculosis treatment (ATT) was stopped. On examination patient was in acute respiratory distress syndrome (ARDS) with shock, he had visible veins on chest and left medial forearm. His Contrast enhanced CT scan of Thorax revealed

Superior vena cava and multiple venous site thrombosis with vessel encasement by lymph nodes, various lymph node enlargements with fluffy nodular infiltrates in the lung, suggestive of lymphoma. Sputum line probe assay detected MDR tuberculosis. Patient was started on second line ATT and Biopsy of lymph nodes were planned but patient succumbed to his illness by the second week of development of ARDS. DIC is rarely been reported with disseminated tuberculosis. Early recognition and treatment of tuberculosis is essential and is fatal if not treated. Lymphoma should be considered as a strong differential in tuberculosis due to overlapping clinical presentation.

**Background:** Tuberculosis is a major health problem in developing countries. India is among one of the hi-

gh burden country for tuberculosis, 1, 609, 547 new and relapse cases: 95 709 (6%) cases aged under 15 years in year 2014.<sup>10</sup>

**Case Report:** A 13 year old boy had fever, loss of ap-petite since 5 months. Weight loss and increasing dy-spnoea from NYHA class one to four over span of t-two months. He had swelling of feet since 15 days. On examination patient was in acute respiratory distress syndrome (ARDS) with shock, he had visible veins on chest and left medial forearm. Patient had pancytopenia. Liver function tests revealed transaminitis with normal bilirubin which was attributed to Antituberculous therapy (ATT) toxicity. His DIC workup was positive with high D-dimer, FDP and low fibrinogen. His serum Ferritin levels were done to rule out Hemophagocytic syndrome and was 8000 ng/ml (normal 70-435 ng/ml) Triglyceride normal, LDH –normal. Bone marrow examination was performed which revealed Myelodysplastic changes mostly reactive in nature with no granuloma. Hence a further Contrast enhanced CT thorax, abdomen, CT pulmonary angiography (Figure 1,2,3&4) was done which showed thrombus in left jugular vein, brachiocephalic vein Superior vena cava, Right External and internal iliac vein and Right femoral vein. Enlarged homogenous lymphnodes at porta, supraclavicular, paratracheal, axillary, subcarinal region, it was ranging from 1-2cm. Right pleural effusion was present. There were 1-4mm nodules in interstitium. Lymph nodes were seen encasing the Superior Vena Cava, and internal iliac veins, Fluffy nodular opacities seen throughout lung parenchyma bilaterally. Findings suggestive of lymphoma with or without disseminated tuberculosis. In view of features of right sided cardiac failure with patient being in shock a 2-D echocardiography was also performed which revealed dilated cardiomyo-

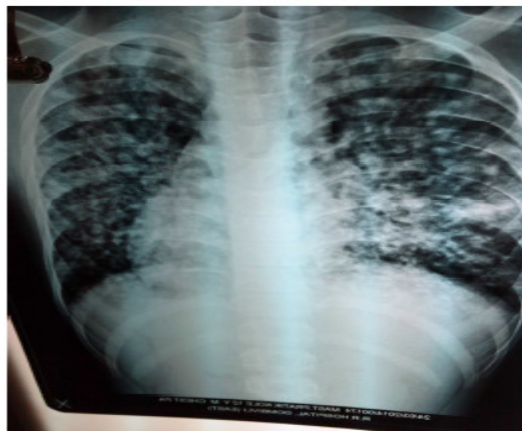
pathy with left ventricular ejection fraction of 20%. A sputum gene Xpert (line probe assay) was done which was positive for Mycobacterium tuberculosis resistant to Isoniazid and rifampicin. With the above history and investigations following differentials were formulated. Disseminated multidrug resistant tuberculosis with disseminated intravascular coagulation (DIC) with TB cardiomyopathy and ARDS, Lymphoma with disseminated tuberculosis with DIC and ARDS or disseminated tuberculosis with secondary Hemophagocytic syndrome. Patient was started on second line ATT and Biopsy of lymph nodes were planned. Patient was started on hepatosafe second line Anti Tuberculous therapy, supportive care and ventilation. He required inotropic support with intermittent diuretic bolus for failure. Patient had disseminated intravascular coagulation therefore he was transfused 6 units of platelet. When platelet count increased to 1 lakh / cubic mm, enoxaparin was started at 1mg/kg dosage BD. Patient remained on ventilator for two weeks and succumbed to his illness by the second week of development of ARDS.

#### **Discussion:**

The incidence of Tuberculosis (TB) is on the rise throughout the world. DIC is a rare but life threatening complication mostly seen in Miliary Tuberculosis.<sup>1</sup> Association of TB with hematologic abnormalities has been reported. Pancytopenia, in particular has proven to be a grave prognostic indicator in disseminated TB.<sup>2</sup> In a study of Wang et al. which included 833 patients with culture proven tuberculosis, 27 (3.2%) had tuberculosis-induced DIC with a mortality rate of 63.0%.<sup>3</sup> Mycobacterium tuberculosis cell wall components –mycolyl arabinogalactan peptide-glycan (m AGP), Phosphatidyl inositol Mannoside-6 (PIM-6) and Lipomannan (LM) were identified as factors responsible for tissue factor induction which

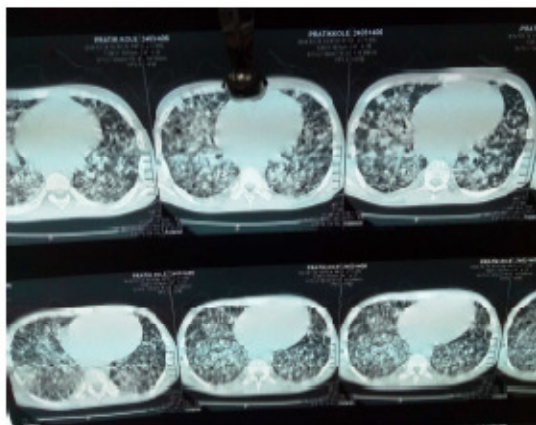
initiates coagulation cascade and hence DIC.<sup>4</sup>The incidence of severe complications, such as DIC and interstitial pneumonia (IP) is frequently found in stage IV or natural killer (NK) cell Lymphoma. This is due to elevated cytokine production by lymphoma cells, which can stimulate the expression of TF in blood cells or surrounding tissue.<sup>5</sup>As per Berkman et al, Pulmonary parenchymal disease occurs in 38% of Hodgkin lymphoma and 24% of Nonhodgkin lymphoma. Three distinct radiological patterns of pulmonary lymphoma are recognised: nodular, bronchovascular-lymphangitic and pneumonic-alveolar.<sup>6</sup>Our patient presented primarily with DIC with SVC and multiple venous site thrombosis and was treated with enoxaparin for thrombosis after platelet transfusion for thrombocytopenia. Concomitant presentation of TB and lymphoma is also a rare entity. A primary malignancy like Hodgkin's lymphoma may cause suppression of the cell-mediated immunity which predisposes to a concomitant TB infection. Misdiagnose or delay in diagnosis of both TB and Hodgkin's disease may occur because of similar signs and symptoms. Immunosuppression is the main cause of Mycobacterium infection in Hodgkin's disease and TB is the main cause of mortality in such cases. Some of the largest case series published by Kaplan *et al.* have reported 201 cases of malignancies complicated by TB of which there were higher chances of reactivation among patients with Hodgkin's disease.<sup>7</sup>It is hypothesised that mycobacterium tuberculosis cause's direct DNA damage and apoptosis inhibition, which increase mutagenesis of progeny cells, combined with angiogenesis favouring tumorigenesis. <sup>7</sup>Nuclear Imaging is functional metabolic imaging, which assesses the basal metabolic activity of inflammatory and neoplastic lesions can help to differentiate between TB and neoplasm. Thallium-201 chloride (TI-201) scanning is one

such scan. Conversely, inflammatory processes usually show an early increase in tracer uptake, but with reduced metabolic activity, or a washout pattern, on the delayed images. Interestingly, tuberculous lesions often show significant delayed activity or retention. CT imaging can also help distinguish tuberculous lymphadenopathy from neoplastic causes. In tuberculous infection, the nodes are usually multiple and large, averaging 2 to 3 cm in diameter. Peripheral enhancement with central areas of low attenuation or loculation are seen on contrast enhanced CT in the majority of cases. Conglomerate mixed density nodal masses may also occur, likely representing multiple confluent nodes with peri-nodal spread of inflammation. In contrast, lymphomatous adenopathy is characteristically associated with homogenous attenuation. Heterogeneity is characteristic of the caseous necrosis seen in tuberculous lymphadenopathy but not pathogenomonic.<sup>8</sup>Neoplastic involvement of the mesentery can be differentiated from tuberculous mesenteric involvement by the appearance of characteristic "sandwich" sign encasement of the superior mesenteric artery.<sup>9</sup>Likewise, although nodal calcification is highly suggestive of tuberculous disease, especially in endemic areas, it can also in non-Hodgkin's lymphoma after treatment with radiotherapy. Because of this overlap in imaging appearances between tuberculosis and malignancy, even in cases where the imaging and clinical features strongly suggest tuberculosis, the diagnosis requires histopathological and bacteriological confirmation.<sup>8</sup> Our patient Contrast enhanced CT Thorax and Abdomen was consistent with diagnosis of lymphoma with encasement of Superior vena cava by homogeneously enhancing lymph node. Biopsy and nuclear scan was planned for confirmation of lymphoma but patient succumbed to his disease.



Chest Xray  
1219x1625mm (72 x 72 DPI)

Figure 1: Chest Xray s/o ARDS



1625x1219mm (72 x 72 DPI)

Figure 2: HRCT Chest

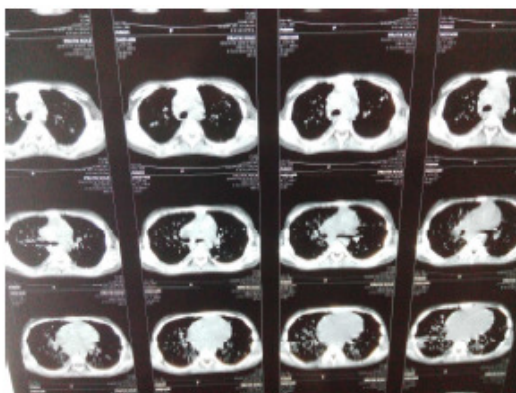


Figure 3: HRCT chest

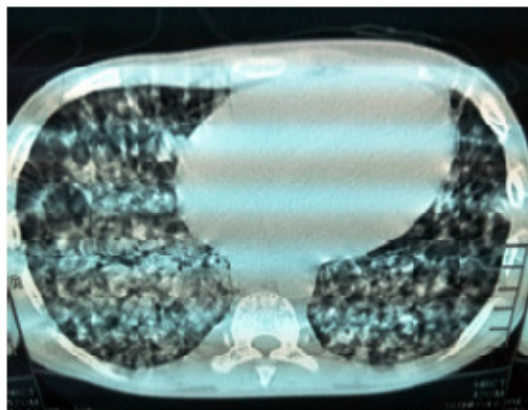


Figure 4: HRCT Chest

**Learning points:**

- DIC may occur in disseminated TB leading to thrombotic complications and can be fatal. Small volume plasma-pheresis may be beneficial in these cases.
- Lymphoma should be considered as a strong differential in tuberculosis due to overlapping clinical presentation.
- lymphoma TB co infection though rare should be sought in every patient of lymphoma with fever and constitutional symptoms
- Nuclear scan like thallium scan can serve as useful modality in differentiating lymphoma and TB

**References:**

1. Fujita M., Kunitake R., Nagano Y., Maeda F. Disseminated Intravascular Coagulation Associated with Pulmonary Tuberculosis, Internal Medicine March 1997, Vol. 36, No. 3
2. Michael J., Larry W. Survival of a patient with Pancytopenia and Disseminated Tuberculosis. Pancytopenia, Disseminated coagulation and Miliary tuberculosis. CHEST, 4 APRIL 1978, 73, Page-536-539
3. Wang JY, Hsueh PR, Lee LN, et al, Mycobacterium tuberculosis inducing disseminated intravascular coagulation-, Thromb Haemost 2005 Apr; 93(4):729-34

4. Kothari H, Rao L.V, Vankayalapati R, Pendurthi U, Mycobacterium tuberculosis Infection and Tissue Factor Expression in Macrophages ,PLOS ONE September 2012 | Volume 7 | Issue 9 | e45700
5. Sase T, Wada H, Yamaguchi M et al, Haemostatic abnormalities and thrombotic disorders in malignant lymphoma ,Thromb Haemost. 2005 Jan;93(1):153-9.
6. Berkman N., Breuer R., Kramer M. et al, Pulmonary involvement in lymphoma. Leukemia and Lymphoma 1996, Vol. 20, No. 3-4 , Pages 229-237.
7. Reddy et al.: A case of concomitant Hodgkin's lymphoma with tuberculosis, Lung India , Jan - Mar 2014 , Vol 31 , Issue 1 , page- 59-62
8. Amukotuwa S., Choong P, Smith P et al, S. Tuberculosis masquerading as malignancy: a multimodality approach to the correct diagnosis – a case report, International Seminars in Surgical Oncology 2005, 2:10
9. Dong P., Wang B. et al. Tuberculosis versus non-Hodgkin's lymphomas involving small bowel mesentery: Evaluation with contrast-enhanced computed tomography. World J Gastroenterol 2008 June 28; 14(24): 3914-3918
10. Who.int. N.p., 2016. Web. 10 July 2016.