

Original article

Incidence of bipartite zygomatic in East Indian population

Dr Banani Kundu, Dr Satabdi Sarkar, Dr Tanmay Sarkar, Dr Saurav Kundu,
Dr Pallab Kumar Saha, Dr Samanwita Basak

R G Kar Medical College & Hospitals, Khudiram Bose Sarani, Kolkata 700 004

Corresponding author: Dr Banani Kundu

Abstract

Introduction: Zygomatic is a very important facial bone for both cosmetic and functional aspect. Sometimes the zygomatic bone is divided horizontally by a sutureline into a larger upper part and a smaller lower part which is known as the bipartite zygomatic. Knowledge regarding the contour of zygomatic bone is very important for management of facial bone injuries. The object of the present study is to report the presence of the bipartite zygomatic in East Indian population.

Aims and objectives: Higher frequency of the bipartite zygomatic bone was observed in Asian continent specially in the eastern part than any other geographical regions. Our aim is to report the frequency of the morphological variation of the malar bone in East Indian population.

Observation and Result : Total 143 dry human skull were observed. Among them only three skulls showed This extra suture line on the zygomatic bone and it was present bilaterally.

Conclusion: Careful observation as well as knowledge of such sutural variations of the facial bone was very important for cosmetic surgeons during intervention.

Key Words: Zygomatic bone, horizontal suture, eastern India, facial injury

Introduction

The zygomatic bone or malar bone is present bilaterally in human skull. It articulates with the maxilla, the temporal bone, the sphenoid bone and the frontal bone. It forms the prominence of the cheek. It also contribute in the formation of the lateral wall and floor of the orbit, parts of the temporal and infratemporal fossa. It has two surfaces malar and temporal and four processes, the fronto-sphenoidal, orbital, maxillary, and temporal; and four borders. The *malar surface* is convex and presented a small aperture near its centre, for the passage of zygomatico-facial vessels and nerve. The antero-superior or orbital border is smooth, concave,

and forms a considerable part of the circumference of the orbit. The antero inferior or maxillary border is rough, and bevelled at the expense of its inner table, to articulate with the maxilla. The posterosuperior or temporal border, curved like an italic letter 'f' is continuous above with the commencement of the temporal line, and below with the upper border of the zygomatic arch. Sometimes an extra suture line may be seen on the malar surface. Os zygomaticumbipartitum is such type of a morphological variation where the zygomatic bone is divided by a horizontal suture into a larger upper part and smaller lower part. In extremely rare instances, there are sutures that divide the bone obliquely or into multiple components. E.Sa-

ndifort reported the first case of a complete division of thezygomaticbone in 1779 ¹(Hrdlic`ka, 1902). A large number of researchers had ob-served the divi-sion of the zygomaticbone, Oszygom-aticumbipart- itum in the era oflate 19th and the early 20th centur-y (Gruber, 1873, 1875, 1879)^{2,3,4} ,Hilgendorf (1879-)⁵ , Matiegka(1899)⁶ Le Double(1906)⁷,Koganei(1926)⁸ ,Soenen (1930)⁹.According to the previous study it was seen thatthe incidence was relatively high in East Asians includeng Japanese compared to the ot- her geographical popul-ations such as Europeans, Af- ricans, Oceanians, and the New W-orld peoples . Ho- wever, astatistical analysis of the frequency of the os- zygomaticumbipartitumin the populations throughout the world has not so far been documented. Careful observation of the morphology of the suture of the zygomatic bone is essential to differentiate it from the fr-acture lines which can results in long-term functional, cosmetic and psychological complicat- ions.The fractures rep-resent one of the more comm- on conditionsencountered today in our modern mechanized life. Etiologies vary from country to coun- try.The injury is usually due to direct impact and o-

Results and analysis

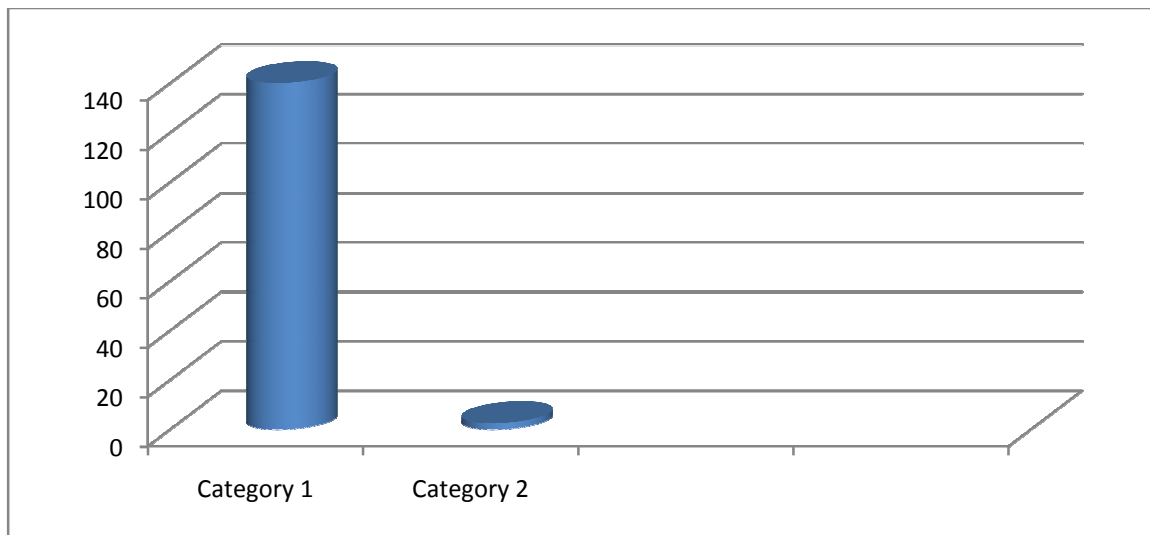


Table 1. Frequency distribution of bipartite zygomatic bone in the samples (sex combined)

ne of the common cause are sports injuries. Contact sports are more dangerous due to their nature, caus- ing extensive and multiple injuries.

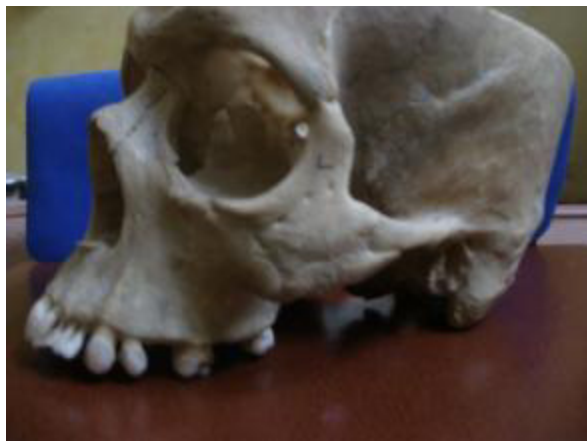Aims and objectives

Higher frequency of the bipartite zygomatic bone was observed in Asian continent specially in the eastern part than any other geographical regions. Subsaharan African populations showed the second pea in the frequency. Our aim is to report the frequency of this morphological variation of the malar bone in East Indian population.

Materials and methods

In the osteological museums of the different Medical Colleges of West Bengal 143 preserved dry skulls were examined. After careful study of those we found the suturalmorphological variation in the zygomatic bone among three dry skulls.. After proper inspection the suture was found on the anterior surface of the these three zygomatic bones of both sides which divides them into a larger upper part and a smaller lower part. No history regarding age, sex and race were available.

Total 143 dry human skull were observed. Among them only three skull showed This extra suture line on the zygomatic bone and it was present bilaterally. So we can conclude that bipartite zygomatic was present in 2.097% of east Indian Population.



Discussion

We have searched for extra suture line on zygomatic bones of all available dry skulls. But our study was unique in prospect of rarity that the suture line was shaped and present horizontally and bilaterally and it was complete. In 1926 Koganei did not find any complete division of the zygomatic bone in any skulls from Hokkaido. In the year 1998 another study of Hanihara T, Ishida H, Dodo Y on 327 dry zygomatic bones showed presence of complete suture in only 1-2% of cases. Similar study was conducted by various researchers on the other geographical areas like in the New World by Hrdlicka (1902, 1904)^{1,10} and Oettinger (1930)¹¹ Mongolians, Chinese, and Koreans by Ohnishi (1940)¹², Europeans by Martin & Saller (1959)¹³, North-west Indians by Bhargava et al. (1960)¹⁴ and Jeyasingh et al. (1982)¹⁵, sub-Saharan African Bantu speaking groups by De Villiers (1968)¹⁶ and Rightmire (1972)¹⁷ and the Bushman-Hottentot group by Klopfer (1943)¹⁸ and Wells (1947-48)¹⁹ Australian Aborigines by Pardoe (1984)²⁰ and for several populations around the world summarised by Hauser & De Stefano (1989)²¹. But there was no proper documentation regarding the

laterality and the pattern of the suture line on the malar surface of the zygomatic bone. Hanihara T, Ishida H and Dodo Y²² elucidated the following information in their study. (1) In each geographic area there may be a regional shift in the occurrence of bipartite zygomatic bone without any noticeable adaptive value. (2) With a few exceptions, the trait is not found in New World population's and Oceanians. So there may be little relationship between the expression of the bipartite zygomatic bone and different life styles or environmental factors. (3) Considering the above said factors along with the high interside correlation and the interregional clinal variation, it can be concluded that a genetic background is responsible for the occurrence of the division of the zygomatic bone. Embryologically the cause or formation of bipartite zygomatic bone may depend upon the number of ossification centres present in it [Bhargava et al (1960)¹⁴, Devillier (1968)¹⁶, Singh et al (1982)¹⁵]. However, there are considerable differences of opinion regarding the ossification of the zygomatic bone. In 1989 Hauser & De Stefano opined that the partitions of the zygomatic bone is not due to the developmental arrest of a primary anlage, it is because of modification

of the secondary appositions from which the definitive zygomatic bone develops. For proper embryological explanations more research works involving the different geographical area are required. The knowledge regarding the presence of the extra suture line is also important for management of the facial injuries. Now-a-days the craniomaxillofacial injuries are most commonly seen in sports related trauma and as well as in the road traffic accidents. Zygomatico-maxillary buttress is

very important as it connects the lateral maxillary alveolus to the zygomatic process of the temporal bone. This buttress gives the zygoma an intrinsic strength so that any impact to the cheek may cause fractures of the zygomatic complex at the suture lines, rarely of the zygomatic bone itself. Knowledge regarding the presence of bipartite zygomatic is important to the anatomists, radiologists and surgeons to avoid the confusion between the fracture line and the extra suture line.

Reference

1. Hrdlicka A (1902) New instances of complete division of the malar bone, with notes on incomplete division. *The American Naturalist* 36, 273±294.
2. Gruber W (1873) Nachtragen zum zweigetheilten Jochbeine ± Os zygomaticum bipartitum ± ohne oder mit Vorkommen des Kiefer-Schlafenbogens. *Archiv für Anatomie und Physiologie*, 208±240.
3. Gruber W (1875) Ein Nachtrag zum Vorkommen des zweigetheilten Jochbeins ± Os zygomaticum bipartitum ± beim Menschen. *Archiv für Anatomie und Physiologie*, 194±201.
4. Gruber W (1879) Fußer Nachtrag zum Vorkommen des Os zygomaticum bipartitum und Zurückweisung des Praedicates 'Os japonicum' für dasselbe. *Virchow Archiv für pathologische Anatomie und Physiologie* 78, 190±194.
5. Hilgendorf F (1879) Das Os japonicum betreffend. *Archiv für pathologische Anatomie und Physiologie* 78, 190±194.
6. Matiegka H (1899) Über das 'Os malare bipartitum'. *Anatomischer Anzeiger* 16, 546±557.
7. LE Double AF (1906) Variations des Os de la Face de l'Homme. Paris: Vigot Freres.
8. Koganei Y (1926) Suture of zygomatic bone. *Zinruigaku Kenkyu (Anthropological Study)* 16, 470±487.
9. Soenen R (1930) Zwei bisher nicht veröffentlichte Fälle von 'Os malare bipartitum' aus der anthropologischen Sammlung des anatomischen Instituts in Bonn. *Anatomischer Anzeiger* 70, 320±324.
10. Hrdlicka A (1904) Further instances of malar division. *The American Naturalist* 38, 361±366.
11. Oettking B (1930) The Jesup North Pacific Expedition XI, Craniology of the North Pacific Coast. New York: G. E. Stechert.
12. Ohnishi M (1940) Anthropologische Untersuchungen über das Jochbein an Mongolen, Chinesen, und Koreanern. *Journal of the Anthropological Society of Nippon* 55, 263±296.
13. Martin R, Saller K (1959) *Lehrbuch der Anthropologie, Band II*. Stuttgart: Gustav Fischer.
14. Bhargava KN, Garg TC, Bhargava SN (1960) Incidence of Os japonicum (bipartite zygomatic) in Madhya Pradesh skulls. *Journal of Anatomical Society of India* 9, 21±23.
15. Jeyasingh P, Gupta CD, Arora AK, Saxena SK (1982) Study of Os japonicum in Uttar Pradesh crania. *Anatomischer Anzeiger* 152, 27±30.
16. De Villiers H (1968) *The Skull of the South African Negro*. Johannesburg: Witwatersrand University Press.
17. Rightmire GP (1972) Cranial measurements and discrete traits compared in distance studies of African Negro skulls. *Human Biology* 44, 263±276.
18. Klopper AII (1943) A report on a collection of skulls from Kruidfontein, Prince Albert district, Cape Province. *South African Journal of Science* 40, 240±245.

19. Wells LH (1947±48) Bipartite zygomatic bones in South African Native skulls. South African Science 4, 84±85.
20. Pardoe C (1984) Prehistoric morphologic variation in Australia. Ph.D. Thesis, Canberra: The Australian National University.
21. Hauser G, de Stefano GF (1989) Epigenetic Variants of the Human Skull. Stuttgart: E. Schweizerbart.
22. Hanihara T, Ishida H and Dodo Y (1998) Os zygomaticum bipartitum: frequency distribution in major human populations. J. Anat. (1998), 192, pp. 539±555