

## Case Report

# Bilateral Variations in the Branching Pattern of the Axillary Artery in a Single Cadaver

**Dr. Purnendu Rang<sup>1</sup>, Dr. Parijat Mukherjee<sup>2</sup>, Dr. Aradhana Sanga<sup>3</sup>, Dr. Arunima Nag (Ray)<sup>4</sup>, Dr. Champak Kumar Dev<sup>5</sup>, Dr. Dipankar Bhoumik<sup>6</sup>, Dr. Saikat Kumar Dey<sup>7</sup>, Prof. (Dr.) Sudeshna Majumdar<sup>8</sup>**

1. Junior Resident, Department of Anatomy, North Bengal Medical College, Sushrutanagar, Darjeeling – 734012. West Bengal, India.
2. Junior Resident, Department of Anatomy, North Bengal Medical College, Sushrutanagar, Darjeeling – 734012. West Bengal, India.
3. Junior Resident, Department of Anatomy, North Bengal Medical College, Sushrutanagar, Darjeeling – 734012. West Bengal, India.
4. Junior Resident, Department of Anatomy, North Bengal Medical College, Sushrutanagar, Darjeeling – 734012. West Bengal, India.
5. Demonstrator, Department of Anatomy, North Bengal Medical College, Sushrutanagar, Darjeeling – 734012. West Bengal, India.
6. Assistant Professor, Department of Anatomy, North Bengal Medical College, Sushrutanagar, Darjeeling – 734012. West Bengal, India.
7. Junior Resident, Department of Anatomy, North Bengal Medical College, Sushrutanagar, Darjeeling – 734012. West Bengal, India.
8. Professor and Head of the Department of Anatomy, North Bengal Medical College, Sushrutanagar, Darjeeling – 734-012.

**Corresponding author:** Prof. (Dr.) Sudeshna Majumdar

---

## Abstract

In May, 2016, while doing the routine dissection for MBBS Students, in the Department of Anatomy, North Bengal Medical College, West Bengal, Bilateral variations were found in the Axillary Artery of a seventy year old female cadaver. The axillary artery divided into anterior and posterior branches at the lateral border of the pectoralis minor muscle in the axilla bilaterally. The anterior branch continued distally to become the radial artery in the forearm. The posterior branch gave origin to the anterior and the posterior circumflex humeral arteries and the subscapular artery. This branch ran in the arm distally to become the ulnar artery in the forearm. This case report will enhance our knowledge in gross and clinical Anatomy. Moreover, the variations in the branching pattern of axillary artery are important for radiologists, vascular surgeons and also for traditional Surgery in the upper limb.

**Key Words:** Axillary artery, anterior and the posterior circumflex humeral arteries, subscapular artery, radial and ulnar arteries.

---

## Introduction

The axillary artery, a continuation of the subclavian artery, begins at the outer border of the first rib and

ends normally at the inferior border of teres major, where it becomes the brachial artery. Its direction varies with the position of the limb. At first deep, it

subsequently becomes superficial, when it is covered only by the skin and fasciae. Pect-oralis minor crosses it and so divides it into three parts, which are proximal, posterior and distal to the muscle [1].

**The branches of the axillary artery** are one from the first part (**superior thoracic artery**), two from the second part (**thoraco-acromial, lateral thoracic arteries**) and three from the third part (**subscapular, anterior and poste-rior circumflex humeral arteries**) [1].**The superior thoracic artery** is a small vessel, runs anteromedially above the medial border of pectoralis minor [1].**The thoraco-acromial artery** is a short branch, at first overlapped by pe-ctoralis minor, then skirting its medial border pierces the clavipectoral fascia to divide into pectoral, acromial, clav-icular and deltoid branches [1]. **The lateral thoracic artery** follows the lateral border of pectoralis minor, pass-es to the deep surface of pectoralis major as far distally as the fifth intercostals space [1]. **The subscapular artery** is the largest branch of the axillary artery, usually arises from the third part of the axillary artery at the distal (inferior) bor-der of subscapularis. At the inferior scapular angle, it anastomoses with the lateral thoracic, intercostal arteries and the deep branch of the transverse cervical artery. Approximately 4 cm from its origin, the subscapular artery divides into the **circumflex scapular and thoracodorsal arteries** [1].**The circumflex scapular artery**, the larger of the tw-o terminal branches of the subscapular artery, curves backwards around the lateral border of scapula, traversing a tr-iangular space between subscapularis above, teres major below and the long head of the triceps laterally to enter the infraspinous fossa [1].**Thoracodorsal artery** follows the lateral margin of the scapula, posterior to the lateral thoracic artery, between latissimus dorsi and serratus anterior

[1].**Anterior circumflex humeral artery** arises from the lateral side of the axillary artery at the distal border of subscapularis. It runs horizontally behind coracobrachialis and the short head of biceps, anterior to the surgical neck of the humerus to continue laterally under the long head of biceps and deltoid and to anastomose with the posterior circumflex humeral artery [1].**The posterior circumflex humeral artery** is larger than the anterior, arises at the distal border of subscapularis and runs backwards with the axillary nerve through a quadrangular space, which is bounded by subscapularis, the capsule of the shoulder joint and teres minor above, teres major below, the long head of triceps medially, and the surgical neck of the humerus laterally. It curves round the humeral neck and gives off a descend-ing branch that anastomoses with the deltoid branch of the profunda brachii artery and with the anterior circumflex humeral and acromial branches of the supra-scapular and thoraco-acromial arteries [1].**Variants** - The branches of the axillary artery exhibit considerable variat-ions. In up to one-third of cases, the subscapular artery can arise from a common trunk with the posterior circumflex humeral artery. Occasionally, the sub scapular, circumflex humeral and profunda brachii arteries arise in common; in this case, branches of the brachial plexus surround this common vessel instead of the axillary artery [1].**Brachial artery** is the continuation of the axillary artery, begins at the distal (infe-rior) border of the teres major and ends ab-out a centimetre distal to the elbow joint (at the level of the neck of the radius) by dividing into radial and ulnar arte-ries. **Variants** : Occasionally, the artery divides more proximally into two trunks that reunite. Frequently, it divides more proximally than usual into radial, ulnar and common

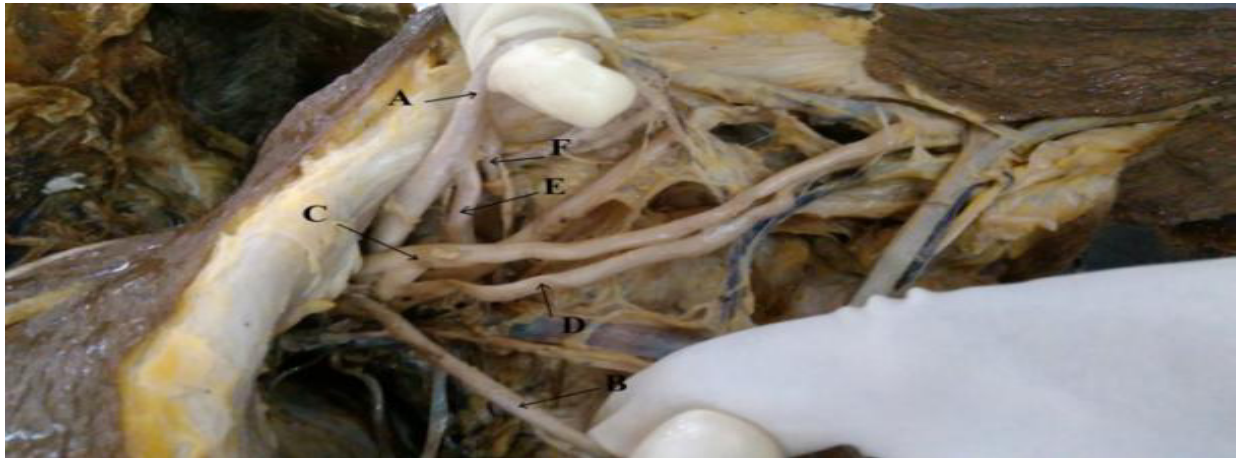interosseous arteries. Most often, the radial branches arise proximally, leaving a common trunk for ulnar and common interosseous arteries [1].

#### Materials and methods

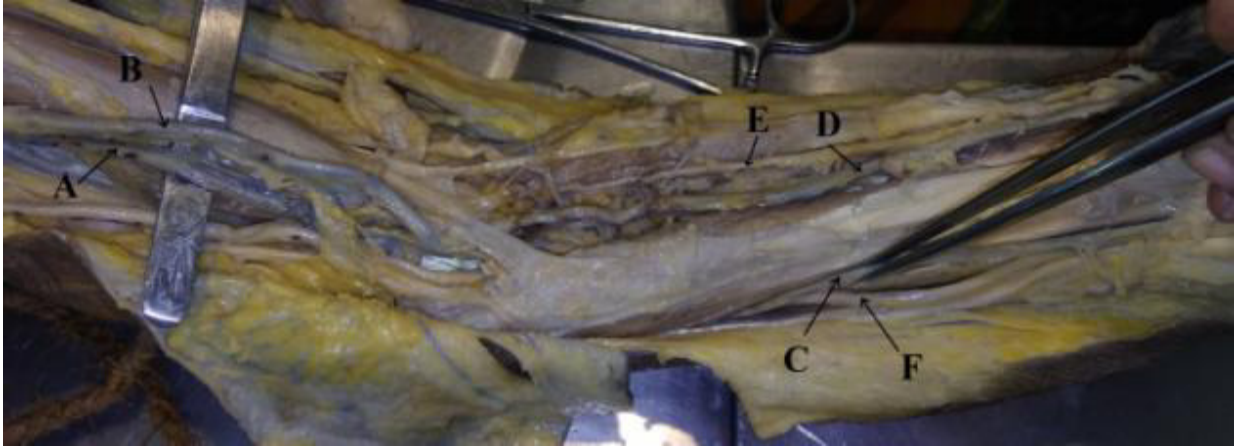
During the routine dissection for undergraduate students in the Department of Anatomy, North Bengal Medical College, West Bengal, bilateral variations were found in the branching pattern of the axillary artery of a seventy year old female cadaver. Dissection was done minutely in both the upper limbs and structures were observed in details. Relevant photographs were taken.

#### Observations

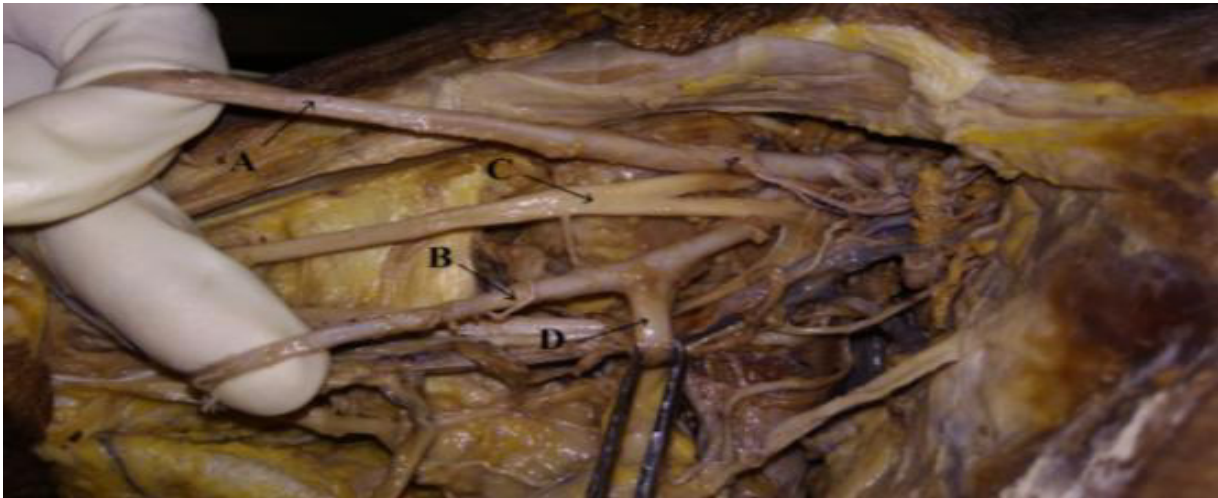The axillary artery divided into anterior and posterior branches at the lateral border of the pectoralis minor in the axilla in both the upper limbs of the female cadaver concerned. The anterior and posterior divisions were almost same in caliber. Median nerve was lying in between two divisions. The anterior branch continued distally to become the radial artery in the forearm. The anterior (very small) and the posterior circumflex humeral arteries and the subscapular artery arose from the posterior branch. This branch ran distally in the arm, gave origin to the arteria profunda brachii and ran further distally to become the ulnar artery in forearm.



**Figure 1.** The left sided Axillary artery has been divided into posterior (A) and anterior divisions (B); the subscapular (E) and posterior circumflex humeral (F) arteries arose from the posterior division (A). The Median nerve (C), arising by two roots and the Ulnar nerve (D) have been labeled also.

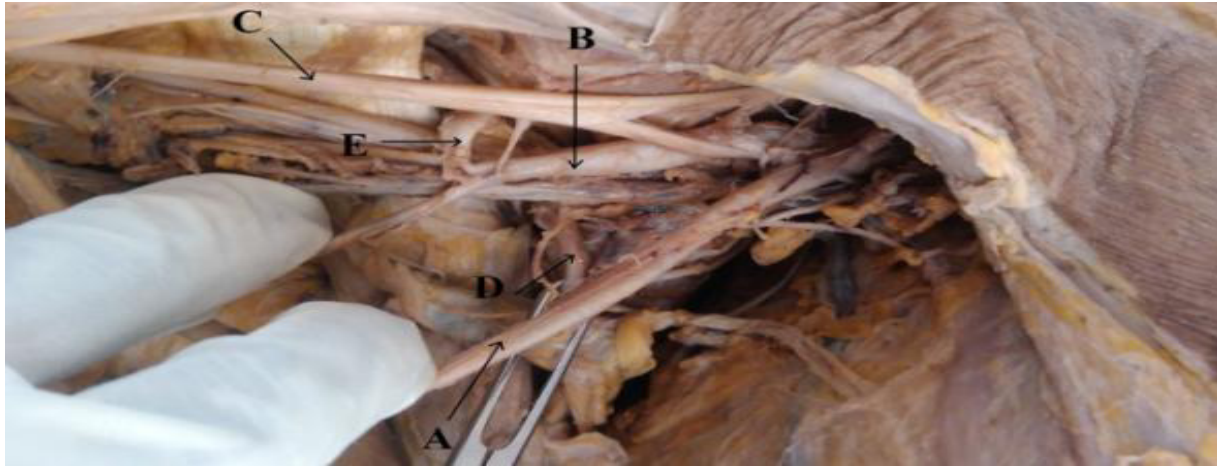

**Figure – 2.** The anterior (B) and posterior (A) divisions of the left sided axillary artery in the arm are visible here. The anterior division (B) has been continued in the forearm as the radial artery (D), accompanied by the superficial branch of the radial nerve (E) , whereas the posterior division has been continued in the forearm as the ulnar artery



(C), accompanied by the ulnar nerve (F).

**Figure – 3.** The right sided Axillary artery has been divided into anterior (A) and posterior divisions (B); the subscapular (D) artery arose from the posterior division (B). The Median Nerve (C) , arising by two roots is present between 'A' and 'B'.



**Figure – 4.** The right sided Axillary artery has been divided into anterior (A) and posterior divisions (B); the subscapular (D) artery and the posterior circumflex humeral (E) artery arose from the posterior division (B). ‘D’ ran on the posterior wall of the axilla and ‘E’ went to enter the quadrangular space. The two roots of the Median Nerve (C) , encircled ‘B’.

#### Discussion

**Embryological Consideration:** The axillary artery develops from the proximal part of axial artery which is derived from lateral branch of 7th intersegmental artery. The developmental variations may be due to unusual primitive path of vascular plexus, persistence of normally obliterated vessels, disappearance of normally retained vessels, incomplete development, fusion and absorption of the parts usually prominent [2, 3].

**General Discussion :** In 2009 Baral et al described a case where, the first part of the right axillary artery did not give any branch, the second part gave off two branches - (a) thoracoacromial artery and (b) a large common trunk from which the lateral thoracic, thoracodorsal, subscapular, posterior circumflex scapular arose and then the trunk continued as posterior circumflex humeral artery. From the third part of the axillary artery only the anterior circumflex humeral artery arose [4]. In a case stated by Komala and Aruna (2010) bilateral variations were found in the branching pattern of the axillary artery of a 50 year old male cadaver. A large trunk arose

from the 2<sup>nd</sup> part of the axillary artery and gave off the lateral thoracic, subscapular and posterior circumflex humeral arteries; the anterior circumflex humeral artery could not be traced [5].

2013, Yohann and Ravindran stated a case where on the right side, the axillary artery bifurcated behind the pectoralis minor into two trunks – superficial and deep [6]. The median nerve was formed by the union of the two roots between these trunks. The deep trunk trifurcated in the upper arm into subscapular artery, a common trunk which gave origin to anterior and posterior circumflex humeral arteries, a branch that ran distally that gave rise to profunda brachii artery. The superficial trunk continued as the brachial artery and it bifurcated at the level of head of radius into radial and ulnar arteries [6]. In 2014, Rani et al described a case where after giving off usual branches, the second part of the left axillary artery bifurcated into a medial and a lateral divisions posterior to the pectoralis minor muscle [7]. The medial division was of larger caliber, supplied pectoralis major and minor muscles and continued as the brachial artery. The lateral division passed

between the two roots of the median nerve and divided further into medial and lateral branches. Posterior circumflex humeral and subscapular arteries arose from the medial branch of this lateral division which continued as arteria profunda brachii to reach the spiral groove along with the radial nerve [7].

In 2015, Sanga et al stated a case with variations in the branching pattern of second part of left axillary artery [3]. The second part gave its usual thoracoacromial branch but the lateral thoracic artery was replaced by a trunk. This trunk gave the lateral thoracic artery supplying the upper 2-3 digitations of serratus anterior, a muscular branch supplying lower digitations of serratus anterior, an accessory subscapular artery crossing above the thoracodorsal nerve supplied the subscapularis muscle. The trunk itself continued as the thoracodorsal artery. The third part of the axillary artery was found to give the usual branches [3]. In 2016, Saha et al found a case with unilateral variation of axillary artery. On the right side, this artery divided into superficial and deep branches (superficial and deep brachial arteries) in its third part. The superficial brachial artery ran radially and the deep brachial artery medially. The anterior and the posterior circumflex humeral arteries and the subscapular artery also arose from the third

### References

- 1- Standring S, Birch R, Lambert SM. (editors). In: Gray's Anatomy, The Anatomical Basis of Clinical Practice. Shoulder Girdle and Arm. 41<sup>st</sup> Edition. Elsevier. 2016; p.827-830.
- 2- Arey LB, Developmental Anatomy. A Textbook and Laboratory Manual of Embryology, In: Development of arteries. 6th edition; Philadelphia. W B Saunders Co; 1957, p.375 – 7
- 3- Sanga A, Roy S, Mondol M, Kar M, Saha PK, Baske A, Dey SK, Majumdar S. Variation in the branching pattern of axillary artery: Thoracodorsal Pedicle. Indian Journal of Basic and Applied Medical Research; December 2015: Vol.-5, Issue- 1, P. 270-274.
- 4- Baral P, Vijayabhaskar P, Roy S, Kumar S, Ghimire S, Shrestha U. Multiple arterial anomalies in upper limb, N Kathmandu University Medical Journal (2009), Vol. 7, No. 3, Issue 27.

part in addition. The deep brachial arteries gave origin to the arteria profunda brachii at a lower level in arm and became the ulnar artery in the forearm, whereas, the superficial brachial artery became the radial artery in the forearm [8]. This case has close similarity with the present case.

**Clinical Importance :** Superior extremity is a common site for surgical and invasive procedures. The Arteries of upper extremities show a large number of variations [3]. Awareness about details and topographic anatomy of variations of axillary artery may serve a useful guide for radiologists, cardiologists, general and vascular surgeons to prevent diagnostic errors and to avoid complications during surgical procedures [8, 9]. The variations should be kept in mind while performing bypass operation between the axillary artery and subclavian artery in case of subclavian artery occlusion [8].

### Conclusion

This case will augment our knowledge in gross and clinical Anatomy and has the clinical importance for the surgeons, cardiologists and radiologists.

### Acknowledgement

We are grateful to all the members of the Department of Anatomy, North Bengal Medical College, Sushrutnagar, West Bengal, India, for their kind cooperation to complete this study.

- 5- Komala N, Aruna N. Variations in the branching pattern of the axillary artery with its clinical importance. *Anatomica Karnataka* , 2010, Vol 4 (2) : 67-70.
- 6- Rani P, Dhurandhar D, Chauhan R. Frequency of abnormal branching pattern of axillary artery: a cadaveric study. *International Journal of Research in Medical Sciences*; 2014 Feb; 2(1):67-70
- 7- Yohannan DG, Ravindran VL. Bifurcation of axillary artery – an unusual case. *International Journal of Anatomical Variations*; 2013, 6: 161–164.
- 8- Saha PK, Ghosal T, Mukherjee P, Baske A, Mondal M, Majumdar S. An unusual Axillary Artery Variation- Case report. *International Journal of Anatomy and Research*, 2016, Vol 4 (1): 2047-51
- 9- Gonzalez-Compta X. Origin of the radial artery from the axillary artery and associated hand vascular anomalies. *Journal of Hand Surg.* 1991;16A:293– 296.