

Original article:

Assessment of Post- Surgical Complications in Anti-Coagulated Patients Undergoing Arthroscopy: A Retrospective Analysis

Dr. Kamlesh Jaswani,

Associate Professor, Department of Orthopaedics, NKP Salve Institute of Medical Sciences and Research Centre, Nagpur, Maharashtra, India.

Corresponding Author:

Dr. Kamlesh Jaswani, Associate Professor, Department of Orthopaedics, NKP Salve Institute of Medical Sciences and Research Centre, Nagpur, Maharashtra, India.

Abstract

Background: In high risk patients on warfarin therapy planned to undergo orthopaedic surgery might require discontinuance of warfarin preoperatively. Hence; we planned the present study to assess the patients undergoing simple arthroscopic procedures while remaining on warfarin therapy.

Materials & Methods: The present study included assessment of 30 patients who underwent arthroscopic surgery. In all these selected patients, the orthopaedic surgeon took the decision of continuation of warfarin therapy during the peri-operative therapy. Complete reviewing of the follow-up details of all the patients up to one year was done. All the data were compiled, summarized and assessed by SPSS software.

Results: Out of 14 patients undergoing knee arthroscopic procedure, 2, 7 and 5 patients underwent irrigation along with debridement, partial meniscectomy and partial meniscectomy and debridement respectively. Among 16 subjects undergoing shoulder arthroscopic procedures, 4, 5, 4 and 3 patients underwent irrigation along with debridement, extensive debridement (biceps tenotomy), extensive debridement along with subacromial decompression and Subacromial decompression along with mini-open rotator cuff repair respectively. Prolonged effusion was observed in 3 patients while prolonged ecchymosis was seen 4 patients.

Conclusion: It might be safer to continue warfarin patients undergoing arthroscopic procedure.

Key words: Arthroscopy, Anti-coagulated, Complications

INTRODUCTION

With the expanding number of arthroscopic strategies playing out each year, it is normal there will be a related increment in patients displaying as possibility for arthroplasty who require constant anticoagulation optional to therapeutic comorbidities.^{1,2} The purposes behind this primarily incorporate a background marked by past Deep venous thrombosis, pulmonary embolism, atrial fibrillation, synthetic heart valve, thrombophilia, and cardiovascular sidestep surgery or stent strategies.^{3,4} Consensus rules for the perioperative administration of these high-risk

patients prescribe discontinuance of warfarin preoperatively, crossing over with low-sub-atomic weight heparin while the prothrombin time standardizes, at that point continuing treatment after surgery.⁵⁻⁸ A worry with this training has been our clinical perception of expanded perioperative blood misfortune and furthermore hematomas, which could conceivably be identified with hindered wound recuperating and the subsequent extra surgery to deplete real hematomas.⁹⁻¹¹ Hence; we planned the present study to assess the patients undergoing simple arthroscopic procedures while remaining on warfarin therapy.

MATERIALS & METHODS

The present study was conducted in the department of orthopaedic surgery of the medical institution and included assessment of 30 patients who underwent arthroscopic surgery. Ethical approval was taken from institutional ethical committee before starting of the study. Inclusion criteria for the present study included:

- Patients undergoing knee or shoulder arthroscopic procedure,
- Patients with abnormal international normalized ratio of less than 1.3
- Patients who were on warfarin therapy during the peri-operative period,
- Patients in whom complete data records along with follow-up details were available.

In all these selected patients, the orthopaedic surgeon took the decision of continuation of warfarin therapy during the peri-operative therapy. Complete reviewing of the follow-up details of all the patients was done. Following information and data of all the patients was collected:

- Medical reason for starting of anti-coagulant therapy,
- Diagnosis of knee/ shoulder injury,
- INR levels at the time of surgery,
- Type of anaesthesia given to the patients,
- Details of the surgical procedure performed,
- Complications occurring intra-operatively and post-operatively.

All the data were compiled, summarized and assessed by SPSS software. P-value of less than 0.05 was taken as significant.

RESULTS

Graph 1 and Graph 2 shows the type of knee and shoulder arthroscopic surgery performed in patients. Out of 14 patients undergoing knee arthroscopic procedure, 2, 7 and 5 patients

underwent irrigation along with debridement, partial meniscectomy and partial meniscectomy and debridement respectively. Among 16 subjects undergoing shoulder arthroscopic procedures, 4, 5, 4 and 3 patients underwent irrigation along with debridement, extensive debridement (biceps tenotomy), extensive debridement along with subacromial decompression and Subacromial decompression along with mini-open rotator cuff repair respectively. Table 1 shows complications occurring in patients during surgical procedures. Prolonged effusion was observed in 3 patients while prolonged ecchymosis was seen 4 patients.

DISCUSSION

One of the commonly prescribed groups of medications in a variety of medical conditions including cardiac pathologies, pulmonary emboli, and hyper-coagulable state are the anti-coagulants.⁸⁻¹⁰ These agents might impose problems for the surgeon while performing surgical procedures on patients prescribed on such medications.¹¹ Hence; we planned the present study to assess the patients undergoing simple arthroscopic procedures while remaining on warfarin therapy.

In the present study, we observed minor haematological complications in patients undergoing arthroscopic procedure, which didn't affected the prognosis of the patients significantly (Table 1). Flanigan DC et al evaluated the postoperative complications encountered for patients undergoing simple arthroscopic procedures while on warfarin. We hypothesized that anticoagulated patients undergoing simple arthroscopic procedures would have few surgical bleeding complications. Arthroscopic procedures performed over a 10-year period on warfarin-anticoagulated patients were retrospectively evaluated. Data collected included the procedure and orthopedic problem, the type of anesthesia, the medical condition requiring anticoagulation, the international normalized ratio (INR) at surgery, and all postoperative complications (bleeding, hematoma, delayed healing, prolonged

postoperative course, infection, and medical complication). Twenty-four patients met the inclusion criteria. All had abnormal INR levels at time of surgery. Four patients were operated on emergently for septic joints, and 20 patients had elective arthroscopic procedures (10 knees, 10 shoulders). There were no major intraoperative bleeding problems. Seven patients had minor postoperative surgical complications: 2 prolonged effusions and 5 prolonged ecchymosis. No medical complications were seen. Oral warfarin appeared to be a safe alternative to manipulating anticoagulation during the preoperative period for simple arthroscopic procedures. Minor bleeding complications consisting of ecchymosis were seen, but no medical complications were identified.¹² Al-Belasy FA et al evaluated the local hemostatic effect of n-butyl-2-cyanoacrylate (Histoacryl; B. Braun, Melsungen, Germany) glue in warfarin-treated patients who undergo outpatient oral surgery without a change in their level of anticoagulation. Thirty consecutive warfarin-treated patients randomly assigned to study and control groups and 10 patients who had never been on anticoagulant therapy serving as the negative control group were included in this trial. Before multiple teeth extractions, all patients had a prothrombin time and the international normalized ratio (INR) determined. To gain hemostasis and primary closure, gelatin sponge and multiple interrupted resorbable sutures were used in the control and negative control groups, and Histoacryl glue and the minimal numbers of interrupted resorbable sutures were used in the study group. Postoperatively, patients were to contact the oral surgeon if abnormal bleeding occurred. Patients who did not have postoperative bleeding were seen on the 10th postoperative day. Local hemostasis was obtained immediately in study patients and only after 10 to 20 minutes in the control and negative control patients. In relation to bleeding complications, there were no cases of postoperative bleeding requiring treatment in both the negative

control patients and study patients. In the control patients, 5 cases had postoperative spontaneous bleeding that required treatment. This difference was statistically significant. No patient had wound infection and the healing process appeared to be normal. Multiple extractions can be performed in patients taking oral anticoagulant therapy without a change in their level of anticoagulation provided an efficient local hemostatic measure is instituted. And, in this regard, Histoacryl glue, used as a topical adhesive over approximated wound edges, is an effective and easily applicable local hemostatic for oral surgery in such patients.¹³

Sanders DL et al performed a retrospective case note analysis of consecutive patients who underwent elective inguinal hernia repair at the Plymouth Hernia Service between 1999 and 2007. All patients on therapeutic oral anticoagulation with Warfarin were selected. Data analysis was of complications and patient-related, hernia-related, and surgery-related variables. International normalising ratio (INR) was measured on the day preceding surgery. A total of 49 patients had been operated on whilst anticoagulated with Warfarin. The mean age of the patients was 75 years (range 44-96 years). Thirty patients were on Warfarin for atrial fibrillation, seven for previous PE, three for previous DVT, and nine for mechanical heart valves. Forty patients had a desired INR range of 2-3, and nine a desired range of 3-4. Forty-five (91.8%) patients had no complications or mild bruising requiring no further management. Three (6.1%) patients developed haematomas requiring surgical management and there was one death of unrelated cause. An INR of greater than 3 increased the risk of postoperative haematoma ($P = 0.03$). None of the other measured patient-related, hernia-related, or surgery-related variables predicted complications ($P > 0.05$). Patients can safely undergo inguinal hernia repair whilst on Warfarin as long as the INR is less than 3.¹⁴ Duong TM et al compared withholding warfarin therapy with low-dose (2.5 mg) oral vitamin K therapy in excessively anticoagulated patients without bleeding complications. Twenty-eight

men were matched according to initial international normalized ratio (INR) and INR goal ranges. The retrospective arm of the study consisted of chart reviews of over anticoagulated patients whose warfarin doses were held until therapeutic INR values were reached.

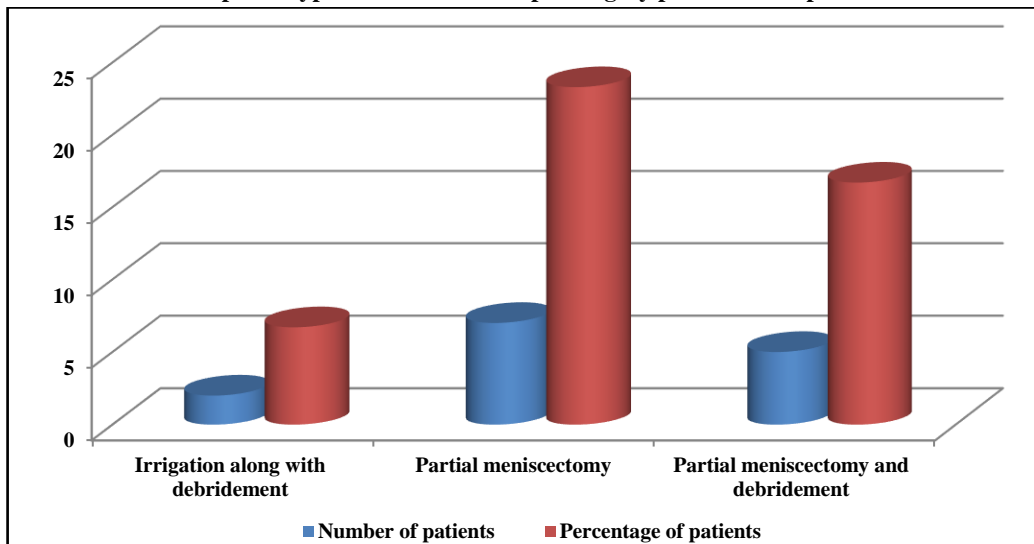
The prospective arm included overanticoagulated patients who were administered a single 2.5-mg dose of oral vitamin K. Mean days to therapeutic INR values were 2.3+/-0.6 and 1.4+/-0.6 (p=0.001), and mean reduction in INR 1 day after treatment intervention was 1.32+/-0.79 and 3.46+/-1.31 (p<001)

U for the withholding and vitamin K groups, respectively. Compared with withholding the warfarin dose, administration of 2.5 mg of oral vitamin K to excessively anticoagulated patients receiving warfarin significantly reduced the time required to reach a therapeutic INR as well as final INR.¹⁵

CONCLUSION

From the above results, the authors concluded that it might be safer to continue warfarin patients undergoing arthroscopic procedure. However, future studies with larger study group are required.

Graph 1: Type of knee arthroscopic surgery performed in patients



Graph 2: Type of shoulder arthroscopic surgery performed in patients

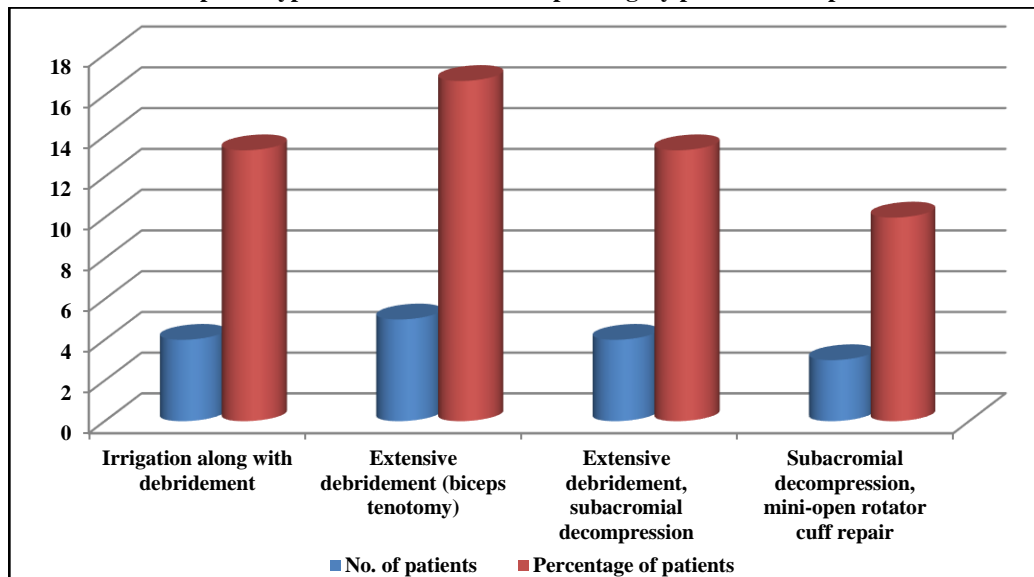


Table 1: Complications occurring in patients during surgical procedure

Complications	Number of patients	INR levels
Prolonged effusion	3	1.8, 2.0, 2.1
Prolonged ecchymosis	4	1.7, 2.0, 2.3, 2.8
Medical complications (thrombosis, embolism and others)	0	-

References

1. Kurtz SM, Ong KL, Schmier J, Mowat F, Saleh K, Dybvik E, Karrholm J, Garellick G, Havelin LI, Furnes O, Malchau H, Lau E. Future clinical and economic impact of revision total hip and knee arthroplasty. *J Bone Joint Surg Am.* 2007;89(Suppl):144–151.
2. Lieberman JR, Wollaeger J, Dorey F. The efficacy of prophylaxis with low-dose warfarin for prevention of pulmonary embolism following total hip arthroplasty. *J Bone Joint Surg Am.* 1997;79:319–325.
3. Morris A, Elder MJ. Warfarin therapy and cataract surgery. *Clin Experiment Ophthalmol.* 2000;28:419–422.
4. Otley CC, Fewkes JL, Frank W, Obricht SM. Complications of cutaneous surgery in patients who are taking warfarin, aspirin, or nonsteroidal anti-inflammatory drugs. *Arch Dermatol.* 1996;132:161–166.
5. Pelligrini VD, Donaldson CT, Farber DC. Prevention of readmission for venous thromboembolic disease after total hip arthroplasty. *ClinOrthopRelat Res.* 2005;441:56–62.
6. Rigg J, Jamrozik K, Myles P. Epidural anesthesia and analgesia and outcome of major surgery: a randomized trial. *Lancet.* 2002;359:1276–1282.
7. Seyfer AE, Seaber AV, Dombrose FA, Urbaniak JR. Coagulation changes in elective surgery and trauma. *Ann Surg.* 1981;193:210–213.
8. Srinivasan AF, Rice L, Bartholomew JR, Rangaswamy C, LaPerna L, Thompson JE, Murphy S, Baker K. Warfarin-induced skin necrosis and venous limb gangrene in the setting of heparin-induced thrombocytopenia. *Arch Intern Med.* 2004;164:66–70.
9. Sutherland CJ, Schurman JR. Complications associated with warfarin prophylaxis in total knee arthroplasty. *ClinOrthopRelat Res.* 1987;219:158–162.
10. Wahl MJ. Myths of dental surgery in patients receiving anticoagulant therapy. *J Am Dent Assoc.* 2000;131:77–81.
11. Warwick D, Whitehouse S. Symptomatic venous thromboembolism after total knee replacement. *J Bone Joint Surg Br.* 1997;79:780–786.
12. Flanigan DC1, Muchow R, Orwin J, Graf B. Arthroscopy on anticoagulated patients: a retrospective evaluation of postoperative complications. *Orthopedics.* 2010 Feb;33(2):82-6.
13. Al-Belasy FA1, Amer MZ. Hemostatic effect of n-butyl-2-cyanoacrylate (histoacryl) glue in warfarin-treated patients undergoing oral surgery. *J Oral Maxillofac Surg.* 2003 Dec;61(12):1405-9.
14. Sanders DL1, Shahid MK, Ahlijah B, Raitt JE, Kingsnorth AN. Inguinal hernia repair in the anticoagulated patient: a retrospective analysis. *Hernia.* 2008 Dec;12(6):589-92; discussion 667-8.
15. Duong TM1, Plowman BK, Morreale AP, Janetzky K. Retrospective and prospective analyses of the treatment of overanticoagulated patients. *Pharmacotherapy.* 1998 Nov-Dec;18(6):1264-70.