

Original article:

Pelviureteric Junction Obstruction evaluation by Ethylenedicysteine Versus Diethylenetriamine Pentaacetic Acid In Technetium Tc 99m in Diuretic Renography

Dr. Prarthan N Joshi , Dr. Kuldeep Aggarwal , Dr. Rakesh Janna , Dr. Vivek Gowda

Dept. of Urology, M. S. Ramaiah Medical College , Bengaluru , Karnataka , India

Corresponding author: Dr. Prarthan Joshi

Abstract:

Introduction: L,L-ethylenedicysteine is a relatively novel carrier of technetium Tc 99m, which has a lower affinity to plasma albumin relative to diethylenetriamine pentaacetic acid. In diuretic renography done for PUJ Obstruction we compared 99mTc-EC scan with 99mTc-DTPA scan.

Materials and Methods: Fifty patients of PUJ Obstruction were randomized for diuretic renographies by 99mTc-EC and 99mTc- DTPA. Here counts of radioisotope per pixel in the target and background tissues were measured as primary endpoint. Also secondary end point clearance half-life of these two radiopharmaceuticals were measured and compared.

Results: A similar mean count of radioisotope per pixel in the target tissue was noted between 99mTc-EC and 99mTc-DTPA scans, interestingly in the background tissue, it was less for 99m Tc-EC ($P < 0.05$). Target-background ratio was higher for 99mTc-EC scan (3.87 ± 2.41 versus 2.76 ± 1.34 ; $P < .001$). Renal clearance half-life of radioisotope was shorter for 99m Tc-EC scan than 99mTc-DTPA scan (58.15 ± 15.17 minutes versus 78.65 ± 19.99 minutes; $P = .033$). When considering uremic patients results were similar with a serum creatinine level $> 2\text{mg/dL}$ as cut off value.

Conclusion: Target-background ratio of radiopharmaceutical uptake rates in diuretic Renography turned out to be a reliable indicator of the higher resolution of 99mTc-EC than 99mTc-DTPA scans. While looking at clearance rates 99mTc-EC was better compared to 99mTc-DTPA. The advantage here is decreased radiation, which can be argued specially in pediatric population.

Keywords: Radioisotope renography, kidney function, diethylenetriamine pentaacetic acid L,L-ethylenedicysteine, radiopharmaceutical, ureteral obstruction

Introduction

Today, the need of hour in evaluation PUJ obstruction cases is less use of invasive and expensive methods. Diuretic renography is an unavoidable portion of armamentarium in the measurement of the kidney function while evaluating the upper urinary tract system. Current standard radiopharmaceutical for diuretic renography is technetium Tc 99m diethylene-triamine pentaacetic acid (99mTc-DTPA). But, notwithstanding its easy application and widespread clinical use, the background of images (especially in uremic patients and severely hydronephrotic kidneys) is obscured due to high uptake of radioactive substance by the liver and the spleen. Hence DTPA might not provide required anatomic resolution for clinical judgment and decision-making in significant number of PUJ obstruction cases. There are

alternatives in form of invasive methods, which are notorious for imposing high expenses to patients and forces the subjects to accept the risks of anesthesia as well as iatrogenic injury to the urinary tract. One of the most important cause of obscured images on ^{99m}Tc -DTPA renogram is tight protein binding of ^{99m}Tc -DTPA to plasma albumin and its tendency to be absorbed in the GI tract.¹ So, an argument can be made to use radiopharmaceuticals with weaker protein binding and lower visceral uptake. One such pharmaceuticals, which has recently been popularized, is technetium Tc 99m L,L-ethylenedicysteine¹ Here, we compared the results of diuretic renography using ^{99m}Tc -EC and ^{99m}Tc -DTPA in similar cohort of patients.

Materials and Methods

From April 2014 to March 2015, a total of 78 consecutive patients with PUJ obstruction who had referred to our center were considered. Those meeting the inclusion criteria were screened for exclusion criteria. Randomization was done with single blinded computer generated randomizing sequence.

Inclusion criteria:

- PUJ obstruction diagnosed by intravenous urography

Exclusion criteria:

- Acute pyelonephritis
- High fever
- Sepsis
- Recurrent cases of PUJ obstruction
- Previously treated with internal or external diversion
- Pyonephrosis
- Bilateral PUJ obstruction

All of the patients gave written informed consent and ethical committee clearance was obtained. Either ^{99m}Tc -EC or ^{99m}Tc -DTPA with F-0 protocol performed diuretic renography. A serum creatinine level higher than 2 mg/dL was considered as uremic.

Following parameters were examined

- Uptake rate of the radiopharmaceutical in kidney
- Uptake rate of the radiopharmaceutical background tissue
- Target-background ratio of uptake
- Clearance half-life of radio-pharmaceutical from the kidneys.

The collected data were analyzed using SPSS software (Statistical Package for the Social Sciences, version 11.5, SPSS Inc, Chicago, Ill, USA). Paired t test was used to compare the uptake parameters of each scan. Continuous variables were demonstrated as means \pm standard deviations and a P value less than .05 was considered significant.

Results

Fifty patients were enrolled in this study and were randomized into two groups of twenty-five. Twenty two of the patients were men and

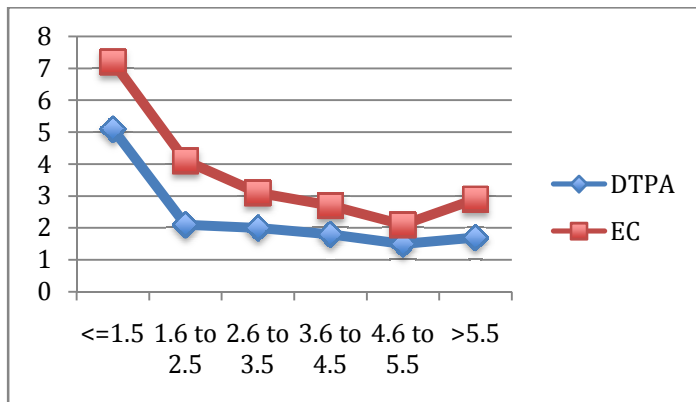
Twenty eight were women. Mean age of the patients was 31 ± 6 years. Mean serum level of creatinine was 3.1 ± 1.2 mg/dL. The serum level of creatinine was 2 mg/dL or less in 31 patients and greater than 2 mg/dL in 19. Mean counts of radioisotope per pixel in the groups of patients are shown in Table number 1. Target-background ratio was higher in $^{99m}\text{Tc-EC}$ scan (3.87 ± 2.41 versus 2.76 ± 1.34 ; $P < .001$). In both nonuremic and uremic patients, this ratio was significantly higher for $^{99m}\text{Tc-EC}$ scan (Table 1, Figure 1). Renal clearance half-life of the radioisotope was shorter for $^{99m}\text{Tc-EC}$ scan than $^{99m}\text{Tc-DTPA}$ scan (58.15 ± 15.17 minutes versus 78.65 ± 19.99 minutes; $P = .033$). In nonuremic patients, renal clearance half-life of the radioisotope substance was shorter for $^{99m}\text{Tc-EC}$ scan (22 ± 8.27 minutes versus 28.20 ± 10.5 minutes; $P = .088$), and it was 71.90 ± 23.31 minutes versus 103.13 ± 35.72 minutes in uremic patients ($P = .051$)

Table no. 1

	$^{99m}\text{Tc-EC}$	$^{99m}\text{Tc-DTPA}$	P-value
All patients			
Target tissue	86.14 ± 55.14	88.64 ± 51.47	0.75
Back ground tissue	24.25 ± 12.85	42.87 ± 21.87	0.002
Target-backgrond	3.87 ± 2.41	2.76 ± 1.34	<0.001
Patients with serum creatinine of 2 mg/dL or less			
Target tissue	99.04 ± 52.78	119.21 ± 51.28	0.13
Back ground tissue	19.64 ± 11.85	33.78 ± 27.21	0.871
Target-backgrond	5.81 ± 1.74	4.15 ± 1.58	0.024
Patients with serum creatinine greater than 2 mg/dL			
Target tissue	84.53 ± 44.52	88.54 ± 54.21	0.58
Back ground tissue	30.74 ± 10.12	46.24 ± 23.5	0.017
Target-backgrond	2.84 ± 1.52	1.89 ± 0.74	0.005

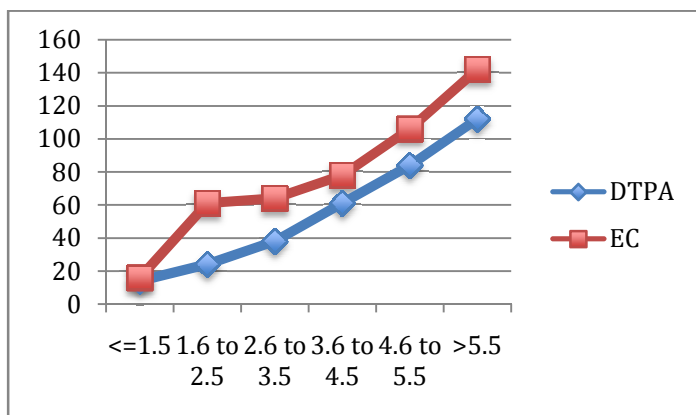
Graph no. 1

Comparison of target background ratio of ^{99m}Tc-EC and ^{99m}Tc-DTPA uptake according to serum creatinine levels



Graph no. 2

Comparison of ^{99m}Tc-EC and ^{99m}Tc-DTPA renal clearance half-life according to serum creatinine levels



Discussion

Technetium Tc 99m DTPA is an appropriate radiopharmaceutical for the evaluation of the kidney and glomerular filtration by diureticrenography. Of other characteristics of this radiopharmaceutical are low-dose radiation exposure to patient, reasonable cost, and availability. However, it is not suitable for the assessment of the renal cortex. Technetium Tc99m EC is a tubular radiopharmaceutical. L,L-ethylenedicysteine easily binds to 99mTc in laboratory conditions and room temperature.²In this study, we showed that there is no significant difference between the uptake rate of the radioactive substance in the kidney tissue for 99mTc-EC and 99mTc-DTPA scans. In contrast, the mean rate of radioactive substance uptake in the background tissue was considerably less in 99mTc-EC scan; this could be due to the less protein binding and the weak binding of EC to red blood cells which eventually lead to a faster excretion of

the radiopharmaceutical from the kidney.³ Das and colleagues compared ^{99m}Tc-EC scan and ^{99m}Tc-DTPA scan in a prospective study. In patients with a normal renal function, the results of these two scans were not significantly different, but ^{99m}Tc-EC scan had a higher imaging resolution and a faster clearance. In another group of patients who had an increased serum level of creatinine to a maximum of 3 mg/dL reduction in glomerular filtration had confounded the background of the images and lack of sufficient resolution in images were significant in ^{99m}Tc-DTPA scan, whereas in ^{99m}Tc-EC scan, the images had a higher resolution, radioactive concentration in background tissue was less, and retention and concentration time of radioactive substance in the kidneys were shorter.⁴ In a study by Eftekhari and colleagues⁵ 23 patients underwent diuretic renography with-EC and ^{99m}Tc-DTPA. The mean serum creatinine level of the patients was 4.5 ± 4.11 mg/dL. This finding shows that patient's creatinine level has similar effects on the absorption of these two radiopharmaceuticals, and what may actually cause a high resolution on imaging in ^{99m}Tc-EC scans, especially in uremic patients, is the lower hepatobiliary excretion of this radiopharmaceutical. Stoffel and colleagues evaluated the safety and pharmacokinetics of iodine I 125 orthoiodohippurate (125I-OIH), ^{99m}Tc-MAG3, and ^{99m}Tc-EC. In their study, the clearance of Tc-EC and ^{99m}Tc-MAG3 averaged 71% and 52% distribution of 125I-OIH and ^{99m}Tc-EC whereof that of 125I-OIH, respectively. Volumes of almost equal (%20 of body weight). The reasons were lower plasma protein binding (31% versus 50% to 70%), lower erythrocyte binding (%2 versus %5), and lower extra renal clearance of ^{99m}Tc-EC which reduces its volume of distribution.^{1,7}

Conclusion

Our study showed that target-background ratio of radiopharmaceutical uptake rates in diuretic renography can support the higher resolution of ^{99m}Tc-EC than ^{99m}Tc-DTPA scan. We also came across faster clearance of ^{99m}Tc-EC than ^{99m}Tc-DTPA. This can help clinician reduce radiation in pediatric population. It can be believed that ^{99m}Tc-EC can better depict the kidney in comparison with ^{99m}Tc-DTPA.

References

1. Verbruggen AM, Nosco DL, Van Nerom CG, Bormans GM, Adriaens PJ, De Roo MJ. Technetium-99m-L,L-ethylenedicycysteine: a renal imaging agent. I. Labeling and evaluation in animals. *J Nucl Med.* 1992 ;33:551-7.
2. Stoffel M, Jamar F, Van Nerom C, et al. Evaluation of technetium-99m-L,L-EC in renal transplant recipients: a comparative study with technetium-99m-MAG3 and iodine-125-OIH. *J Nucl Med.* 1994;35:1951-8.
3. Kabasakal L, Turoglu HT, Onsel C, et al. Clinical comparison of technetium-99m-EC, technetium-99m-MAG3 and iodine-131-OIH in renal disorders. *J Nucl Med.* 1995;36:224-8.
4. Das BK, Misra M, Gambhir S, Mittal BR, Banerjee SN. Comparative study of ^{99m}Tc-cystine and ^{99m}Tc-DTPA as renal agents. *Indian J Nucl Med.* 1992;7:34-9.
5. Eftekhari M, Vakili A, Alavi MS. Clinical evaluation of ^{99m}Tc Ethylenedicycstein for renal function study and comparison with ^{99m}Tc DTPA. *Iran J Nucl Med.* 1380;3:6-11.
6. Zakko S, Mrhac L, Al-Bahri J, Al-Shamsi H, Lootah S, Benjamin RJ. Biliary excretion of Tc-^{99m} EC in renal studies. *Clin Nucl Med.* 1998;23:417-9.
7. Kabasakal L, Halac M, Yapar AF, et al. Prospective validation of single plasma sample ^{99m}Tc-ethylenedicycysteine clearance in adults. *J Nucl Med.* 1999;40:429-31.