

Original article:

Comparative study of surgical technique of sutureless, gluefree pterygium excision surgery with conjunctivo-limbal auto-graft versus pterygium excision surgery with sutured conjunctivo-limbal auto-graft

¹Dr. Divyesh Ranpara, ²Dr. Abhay Lune, Professor, ³Dr. Gaurav Brahmhatt, ⁴Dr. Saurabh Oza, ⁵Dr. Nikhil Toshniwal

¹Department of Ophthalmology, ²Department of Ophthalmology, ³Resident, Department of Ophthalmology, ⁴Resident, Department of Ophthalmology, ⁵Resident, Department of Ophthalmology
Corresponding author: Dr. Divyesh Ranpara

ABSTRACT:

Introduction: To evaluate new surgical technique of sutureless-gluefree conjunctivo-limbal autograft transplantation (CLAT) after primary pterygium excision surgery with sutured conjunctivo-limbal autograft transplantation (CLAT). Compare surgical time, post-operative comfort, pain and complications between two types of surgeries.

Material & method: The study included 100 eyes of 100 patients with primary pterygium. They were divided into two groups. Group A – 50 patients with pterygium excision surgery with sutureless-gluefree conjunctivo-limbal autograft (CLAG). Group B – 50 patients with pterygium excision surgery with sutured CLAG. In both the groups surgical timing was noted and they were examined up to six months post-operatively regarding pain, comfort and complications like graft loss, graft dehiscence, graft retraction and recurrence.

Results: Mean time taken for the surgery for Group 1 was 25.78 ± 4.43 mins as compared to Group 2 was 53.88 ± 7.63 mins. Graft dehiscence occurred in 2/50(4%) patients of group 1 as well as 2/50(4%) in group B. Graft retraction occurred in 7/50(14%) patients of Group 1 and 6/50(12%) in group 2. Group 1 had 1/50(2%) loss of graft. Graft recurrence rate was 6/50(12%) in group 1 and 5/50(10%) in group 2.

Conclusion: New surgical technique of pterygium excision surgery with sutureless-gluefree CLAT is easy, safe, cost-effective and less time consuming. It is more comfortable to patients and surgeons.

Key words: Primary Pterygium, Conjunctivo-limbal autograft.

INTRODUCTION

Pterygium has been described as an ophthalmic enigma¹ as much is still unknown about this condition commonly seen as ocular surface disease. Pterygium is a pinkish triangular wedge-shaped or wing shaped degenerative growth of subconjunctival tissue encroaching over cornea. It proliferates as a vascularized granulomatous tissue to invade the corneal surface destroying superficial corneal epithelium, underlying basement membrane, underneath structure bowman's layer and superficial layers of stroma. It can occur either

unilateral in one eye or bilateral in both eyes. It can also occur in both sides nasal and temporal in one eye. It is an ocular surface disease and its prevalence varies from 0.7% to 31% in different geographical regions.² Incidence is more towards tropical and subtropical areas between 30 degrees latitude north and south of the equator area.³ Incidence also varies in different areas of India. It has become a significant eye problem in rural areas as a result of long duration of ocular sun exposure, heat, dust and fumes due to outdoor work^{4,5}. It is more common in dark people than in

whites.⁶ Major predisposing factors for occurrence of Pterygium are the hot and dry climate and long exposure to ultraviolet rays (UV rays).

Recurrence is a main problem with pterygium surgeries. The rate of recurrence widely depends on various factors like degree of inflammation of pterygium, vascularization and major factor is type of surgery been performed. This has been significantly reduced by placing conjunctivo-limbal autograft after pterygium excision. The rate of recurrence with sutures is approximately 15%, while it is approximately 10-15% with glue. Recently, a new technique of using fibrin of patient's own blood present at the graft bed to fix the graft has been introduced.⁷ Sutures and glue being foreign materials are associated with complications such as infection, granuloma formation, chronic inflammation, hypersensitivity reactions, recurrence and foreign body sensation and pricking pain to the patient. This technique is also cost effective and requires lesser surgical time as compared to the techniques using sutures or glue. In this study, we aim to find out whether this new technique of a suture less, glue-free graft is associated with complications such as graft dehiscence, graft retraction, loss of graft, recurrence and post-operative comfort.

AIMS AND OBJECTIVES

- To evaluate new surgical technique of suture less - glue free surgery to affix the conjunctivo-limbal auto-graft after pterygium excision.
- To compare post-operative complications of loss of graft, graft dehiscence and recurrence of pterygium between suture less, glue-free conjunctivo-limbal auto-graft and sutured conjunctivo-limbal auto-graft.
- Compare surgical time and post-operative comfort between sutureless-gluefree

conjunctivo-limbal auto-graft and sutured conjunctivo-limbal auto-graft.

MATERIALS AND METHOD

- **Type of study:** Prospective interventional Study
- **Place of study:** Dr. D.Y. Patil Medical College, Hospital and Research Centre, Pimpri, Pune-411018
- **Period of study:** July 2015 to September 2017
- **Sample size:** 100 eyes
- **Ethical committee clearance:** Institute Ethics committee clearance was obtained before the start of study.
- **Informed Consent:** Written & informed consent was obtained from all patients on the previous day of the surgery and were explained about complications of surgery and anaesthesia.
- **Inclusion Criteria:**
 - Patients with primary pterygium.
 - Gender – Both
 - Age 20 to 70 years
- **Exclusion Criteria:**
 - Pseudopterygium
 - Ocular surface infections
 - Previous pterygium surgery
 - History of any bleeding abnormalities
 - Anti-coagulant therapy

Source of data: Patients with pterygium fulfilling the inclusion and exclusion criteria - attending outpatient department at Dr. D. Y. Patil Medical College & Hospital, Pimpri, Pune.

Method of Data collection: Data was collected from all the patients according to proforma including symptoms such as redness, foreign body sensation, itching, irritation, watering, duration of fleshy growth, decrease of vision or blurring of vision, detailed history of progression, occupational history, history of systemic diseases and history of

any medication. Followed by detailed ocular examination was done of all patients include:

- ⊙ Visual acuity using Snellen's chart and Jaeger's chart.
- ⊙ Best corrected visual acuity.
- ⊙ Slit lamp bio-microscopy.
- ⊙ Fundus examination by direct and indirect ophthalmoscope.
- ⊙ Slit lamp bio-microscopy by +78D or +90D lens.
- ⊙ Intra ocular pressure by Perkin's hand held tonometer.
- ⊙ Sac syringing.

The clinical parameters that were studied are:

1. Site of pterygium – Nasal / Temporal / Nasal+Temporal
2. Laterality – Unilateral / Bilateral.
3. Grade or Size of pterygium – measured from limbus to cornea.
 - Grade I — crossing the limbus up to 2mm.
 - Grade II — 2 mm beyond limbus up to pupil margin or up to 4 mm from limbus.
 - Grade III — between pupillary margin and pupillary center.
 - Grade IV — beyond pupillary center.
4. Type of pterygium – Progressive / Atrophic.
5. Occurrence of pterygium – Primary / Recurrent.
6. Presence of Stocker's line.
7. Presence of Fuch's spots.

All 100 patients fitting in inclusion and exclusion criteria were randomly categorized into two groups without any specification like age, sex, or grade of pterygium.

1. **Group 1:** 50 eyes of patients operated as Pterygium excision surgery with suture

less, glue-free conjunctivo-limbal auto-graft.

2. **Group 2:** 50 eyes of patients operated as Pterygium excision surgery with sutured conjunctivo-limbal auto-graft.

Anaesthesia given in both groups was Peribulbar block -limbal auto-graft.

Surgical steps for group 1: The body of the pterygium was dissected 2-3 mm from the limbus from canthal side down to the bare sclera and reflected over the cornea. The pterygium head and cap was avulsed from cornea followed by careful excision of the corneal remnants. Wherever possible, haemostasis was allowed to occur spontaneously without the use of cautery. Superotemporal conjunctivo-limbal graft was used as superior conjunctiva is extensive and protected from sunlight. Careful dissection between graft conjunctiva and Tenon's capsule was done while fashioning the 1 mm oversized conjunctivo limbal graft (CLAG). Then carefully graft was transferred to the recipient site. The limbal edge of the graft was carefully positioned at the host limbal tissue edge. To ensure that the residual bleeding does not lift the graft, small central haemorrhages were tamponade with direct compression using non-tooth forceps. The graft was transplanted to recipient site scleral bed and tucked in carefully and spread over the bare sclera and all margins of graft were tucked in the surrounding conjunctiva. Pressure was applied on the graft by back of the forceps with blunt part for 5-10 mins to affix the graft to scleral bed. The stabilization of the graft was tested centrally and on each free edge with the help of cotton wick to ensure firm adherence to the sclera. Eye pad was given and removed after 18 to 20 hours after surgery.

Surgical steps for group 2: Same surgical steps are done as done in type 1 surgery except CLAG was

taken 0.5 mm oversized and The four corners of graft were anchored to recipient site conjunctiva and sutured with absorbable vicryl suture no 10.0. First of all two limbal corners were sutured in episclera and then into the conjunctiva. Then other graft margins are sutured to adjacent conjunctiva to close the wound edges. 6 to 8 suture were taken according to size of the graft and necessity.

All patients were examined on post-operative day 1, after 1 week, 3 weeks, 6 weeks, 12 weeks and 24 weeks of surgery.

All patients were started on

- Topical antibiotics and steroids 4 to 6 times a day and tapered over 6 – 8 weeks.
- Lubricant drops 5-6 times a day for 6 weeks.
- Systemic antibiotic given were Tab ciprofloxacin 500mg twice a day for 5 days along with antacids.
- Nonsteroidal anti-inflammatory tablet paracetamol 500mg twice a day for 5 days.
- Supplementary drugs were given are Vitamin C tablets and Multivitamin B complex.

Operative time in both groups was noted. Post-operative pain was assessed by taking patient's feedback on a Likert's pain scale of 1 to 10. In both groups post-operative condition and complications were compared like graft dehiscence, graft retraction, graft loss, graft stability, post-operative pain, comfort, foreign body sensation and recurrence for the 6 months.

All patients were questioned about intensity of post-operative pain, discomfort and foreign body sensation up to 6 months. According to their answers and chemosis and hyperemia of the

conjunctival graft after surgery, they were graded into 4 groups as:

- A. Grade 0 = Nothing or no pain, discomfort and FB sensation with no chemosis or hyperemia.
- B. Grade 1 = Mild pain, discomfort, chemosis, hyperemia.
- C. Grade 2 = Moderate pain, discomfort, hyperemia, chemosis, FB sensation.
- D. Grade 3 = Severe pain, discomfort, FB sensation, marked chemosis and hyperaemia.

The overall satisfaction level of the surgery in all patients was asked after 3 weeks and it was categorised in 4 groups as:

- A. Group 1 = Unsatisfied
- B. Group 2 = Low satisfaction
- C. Group 3 = Moderate satisfaction
- D. Group 4 = High satisfaction

Surgical time taken in both groups, post-operative condition of patient's eye and post-operative complications data was collected and statistical analysis was done using chi square chart. Follow up of the patients was done up to 6 months.

OBSERVATIONS AND RESULTS

The pterygium was located nasally in all eyes for both groups that we operated in our case study. Range of patient's age in both groups was from 20 to 70 years. There were 63 males and 37 females enrolled in this study. The two groups were clinically similar regarding the size of the pterygium.

Table 1 Showing mean surgical time in both groups

Group	N(100)	Minimum Surgical time(mins)	Maximum Surgical time(mins)	Mean time with SD(mins)
1	50	18	35	25.78 ± 4.43
2	50	40	70	53.88 ± 7.63

Table 1 show us mean surgical time in group 1 is 25.78 ± 4.43 minutes and 53.88 ± 7.63 minutes in group 2, which is higher comparing to group 1.

Table 2 showing post-operative grading of complications at day 1

Grade of complication at day 1	Group 1	Group 2	Total
Grade 1	34	30	64
Percentage %	68%	60%	64%
Grade 2	14	14	28
Percentage %	28%	28%	28%
Grade 3	2	6	8
Percentage %	4%	12%	8%
Total	50	50	100
Percentage %	100%	100%	100%

Rows 2-9 have been clubbed for statistical analysis, Value of p is 0.325

Table 2 and shows us grading and percentage of post-operative complications like pain, discomfort, foreign body sensation, graft edema and congestion among each group. Higher the grade of post-operative complications at day 1 there is higher complications. Thus in group 1 there are less number of cases having grade 3 complications. There are almost similar percentage of grade 2 and grade 1 complications in both groups.

Table 3 showing post-operative grading of complications at week 1

Grade of complication at week 1	Group 1	Group 2	Total
Grade 0	30	22	52
Percentage %	60%	44%	52%
Grade 1	19	23	42
Percentage %	38%	46%	42%
Grade 2	1	5	6
Percentage %	2%	10%	6%
Total	50	50	100
percentage%	100%	100%	100%

Rows 2-9 have been enrolled for statistical analysis, Value of p is 0.118

Table 3 shows us that 60% patients from group 1 had grade 0 complications at the end of week 1 as compared to 44% in group 2. Surgical group 2 had 46% grade 1 and 10% grade 2 complications as compared to group 1 which had 38% grade 1 and 2% grade 2 complications. So at the end of week 1 there were lesser complications in group 1 and more in group 2.

Table 4 showing post-operative grading of complications at week 3

Grade of complication at week 3	Group 1	Group 2	Total
Grade 0	43	39	82
Percentage %	86%	78%	82%
Grade 1	7	9	16
Percentage %	14%	18%	16%
Grade 2	0	2	2
Percentage %	0%	4%	2%
Total	50	50	100
Percentage %	100%	100%	100%

Rows 2-9 have been enrolled for statistical analysis, Value of p is 0.294

Table 4 shows us that 86% patients from group 1 had grade 0 complications at the end of week 3 as compared to 78% in group 2. Surgical group 1 had 14% grade 1 and 0% grade 2 complications as compared to group 2 which had 18% grade 1 and 4% grade 2 complications. So at the end of week 3 there were lesser complications in group 1 and more in group 2.

Table 5 showing percentage of graft dehiscence in each group

Graft dehiscence	Group 1	Group 2	Total
Yes	2	2	4
Percentage %	4%	4%	4%
No	48	48	96
Percentage %	96%	96%	96%
Total	50	50	100
Percentage %	100%	100%	100%

Rows 2-5 have been enrolled in statistical analysis, Value of p is 1.000

Table 5 and chart 1 shows rate of graft dehiscence in both groups. Group 1 and group 2 shows similar graft dehiscence rate 4%.

Chart 1 showing rate of graft dehiscence in both groups

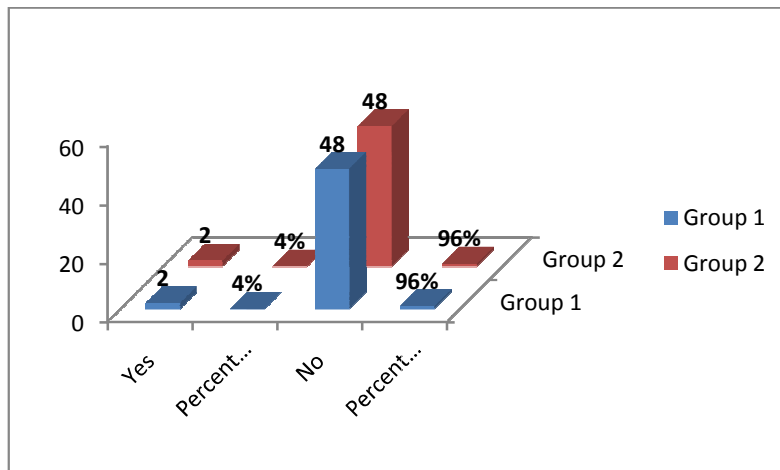


Table 6 showing percentage of graft retraction in each group

Graft retraction	Group 1	Group 2	Total
Yes	7	6	13
Percentage %	14%	12%	13%
No	43	44	87
Percentage %	86%	88%	87%
Total	50	50	100
Percentage %	100%	100%	100%

Rows 2-5 have enrolled for statistical analysis, Value of p is 0.766

Table 6 and chart 2 shows graft retraction rate in both groups. Group 1 shows 14% and group shows 12% graft retraction rate. There is not much significant difference in both groups.

Chart 2 showing graft retractions in both groups

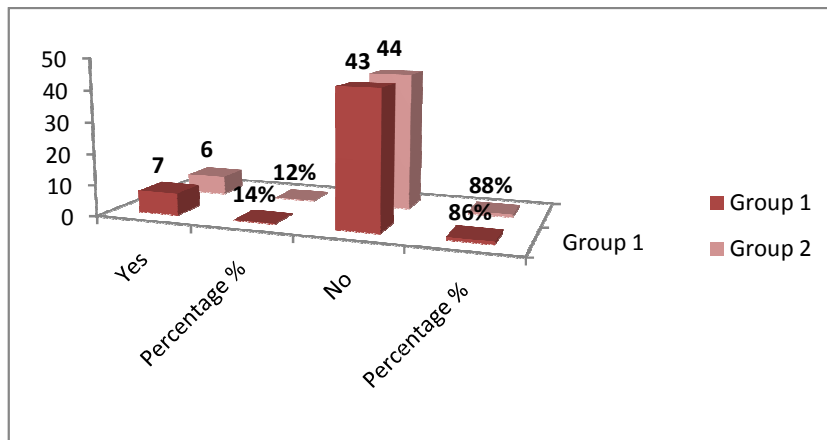


Table 7 showing percentage of graft loss in each group

Graft loss	Group 1	Group 2	Total
Yes	1	0	1
Percentage %	2%	0%	1%
No	49	50	99
Percentage %	98%	100%	99%
Total	50	50	100
Percentage %	100%	100%	100%

Rows 2-5 have been enrolled for statistical analysis, Value of p is 0.315

Table 7 and chart 3 shows graft loss rate in each group. 1 case of graft loss was noted in group 1(2%) while there was no case of graft loss post-surgery in group 2(0%).

Chart 3 showing graft losses in both groups

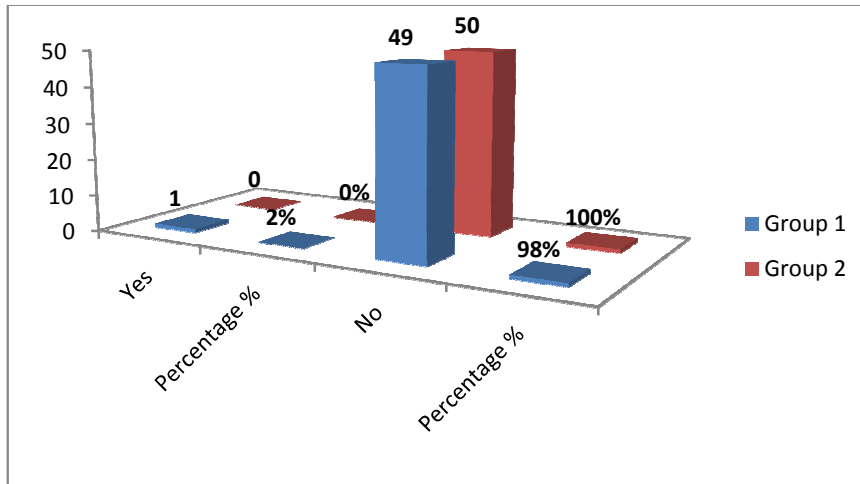


Table 8 showing percentage of recurrence in each group

Recurrence	Group 1	Group 2	Total
Yes	6	5	11
Percentage %	12%	10%	11%
No	44	45	89
Percentage %	88%	90%	89%
Total	50	50	100
Percentage %	100%	100%	100%

Rows 2-5 have been enrolled for statistical analysis, Value of p is 0.749

Table 8 and chart 4 shows recurrence rate in both groups within 6 months of period after surgery. Group 1 showed 6 cases of recurrence (12%) and group 2 showed 5 cases of recurrence (10%). Recurrence rate in both groups does not show much difference.

Chart 4 showing recurrence rates in both groups at 6 months

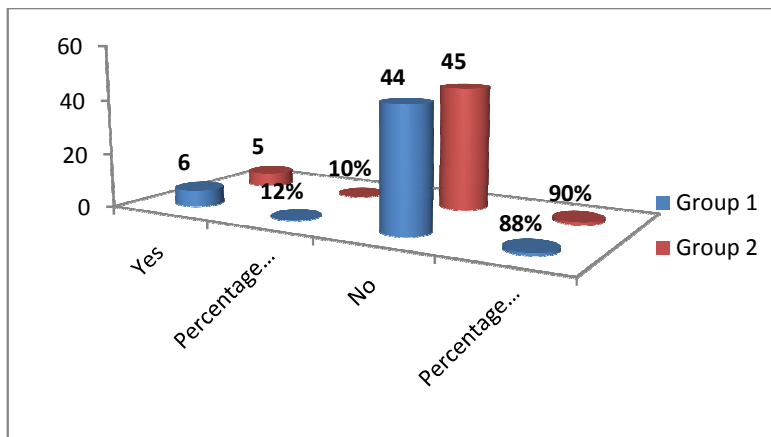


Table 9 showing satisfaction level in each group at the end of 6 months

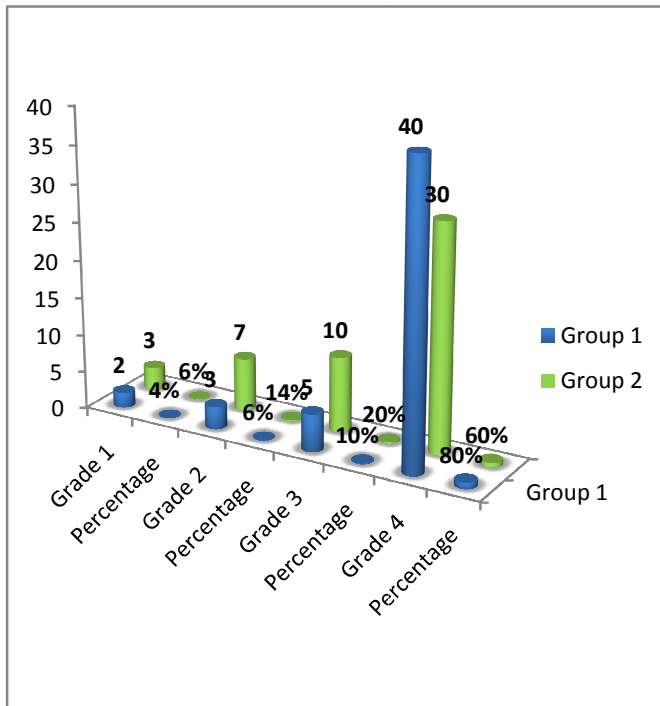
Overall Satisfaction at six months	Group 1	Group 2	Total
Grade 1	2	3	5
Percentage %	4%	6%	5%
Grade 2	3	7	10
Percentage %	6%	14%	10%
Grade 3	5	10	15
Percentage %	10%	20%	15%
Grade 4	40	30	70
Percentage %	80%	60%	70%
Total	50	50	100
Percentage %	100%	100%	100%

Rows 2-9 have been enrolled in statistical analysis

Value of p is 0.180

Table 9 and chart 5 shows percentage of overall satisfaction level in both groups after the end of six months. There were more highly satisfied patients in group 1(80%) then group 2(60%) and less low satisfied patients in group 1(6%) then group 2(14%). There were 2(4%) patients in group 1 and 3(6%) in group 2, who were unsatisfied after 6 months of surgery because of post - operative complications.

Chart 5 showing overall satisfaction levels after 6 months in both groups.



DISCUSSION

In our study we compared the two techniques of sutureless and glue free conjunctivo- limbal autograft (CLAG) (group1) with the sutured conjunctivo-limbal autograft (group2) in primary pterygium surgery. The recurrence rate (12%) in group 1 was comparable to group 2 (10%) p value is 0.749-not significant. Massaoutiset al.¹⁰ in his study stated that the concept of surgical success in pterygium surgery can be defined as the provision of a white cosmetic conjunctiva, with no persistent symptoms and a low recurrence rate (less than 10%). The recurrence rate in our study 12% and 10% in group 1 and group 2 respectively agrees with the Massaoutiset al.'s criteria. The recurrence rate is also near about the Malik et al.¹¹ study who reported recurrence rate of 2.5% using a similar procedure of sutureless and glue free graft. Graft dehiscence is a recognized complication of technique using autologous blood to affix the graft in pterygium surgery. Foroutan et al.⁹ reported

13.33% rate of graft dehiscence using autologous blood and attributed this to a low concentration of thrombin and fibrinogen in autologous glue (blood) compared to a commercial preparation. In our study graft dehiscence occurred in 2 eyes (4%) in group 1 and in group 2. P value is 1.000, not significant. The four cases in group 1 and 2 were due to either eye trauma, or a patient rubbing his eye vigorously and inclusion of tenon's capsule with the graft. Hence, we instruct patients to use a protective shell and not to rub the eye in the 1st week post-operatively. Additionally, meticulous dissection of thin donor limbal conjunctival autograft free of tenon's capsule is mandatory for successful graft uptake. Graft retraction was reported by Tan⁸ in his study. He advocated subconjunctival fibrosis and recommended meticulous dissection of sub-epithelial graft tissue during pterygium excision. Foroutan et al.⁹ reported 20% of cases with graft retraction in his study. In our study graft retraction occurred in 7 eyes out of 50 (14%) eyes in group 1

and 6 eyes (12%) in group 2. P value is 0.766, not significant. All the cases of graft retraction were due to conjunctival chemosis and edema and were resolved with conservative treatment except one case in group 1 which progressed to graft dehiscence and was sutured with 10/0 nylon. In comparison, Wit et al.⁷ in his study reported no graft displacement. According to Dr. Mitra⁸, "The main disadvantage of this technique is the risk of graft loss in the immediate postoperative period." In a study by Dr. Mitra⁸, 19 patients underwent sutureless glue-free graft fixation and were followed-up for 6 months. Of these 19 patients, 17 had primary, and two had recurrent pterygium. In our study there was only one case of graft loss immediately after 2 days of period in group 1. Group 2 showed no graft losses. P value is 0.315.

There was no formation of pyogenic granuloma in both groups and no cyst formation occurred in either group. Though these outcomes indicate that complications related to sutures are more common in group 2 despite using 10/0 nylon which induces minimal reaction and were removed after 2 weeks with some discomfort and foreign body sensation post-operatively. We also noted that some patients were not co-operative at the slit lamp during suture removal.

In our study we noted grading and percentage of post-operative complications like pain, discomfort, foreign body sensation, graft edema and congestion among each group. Higher the grade of post-operative complications at day 1 there is higher complications. Thus in group 1 there are less number of cases having grade 3 complications. There are almost similar percentage of grade 2 and grade 1 complications in both groups on day 1. There were 60% patients from group 1 who had grade 0 complications at the end of week 1 as compared to 44% in group 2. Surgical group 2 had

46% grade 1 and 10% grade 2 complications as compared to group 1 which had 38% grade 1 and 2% grade 2 complications. So at the end of week 1 there were lesser complications in group 1 and more in group 2. There were 86% patients from group 1 who had grade 0 complications at the end of week 3 as compared to 78% in group 2. Surgical group 1 had 14% grade 1 and 0% grade 2 complications as compared to group 2 which had 18% grade 1 and 4% grade 2 complications. So at the end of week 3 there were lesser complications in group 1 and more in group 2. So at the end of 3 weeks mostly all the patients were having no complications. It further reduced with increasing time from 3 weeks up to 24 weeks.

The mean operative time in group 1 was 25.78 ± 4.43 mins as compared to Group 2 was 53.88 ± 7.63 min. The difference in surgical time is due to its dependency upon the technique. The time taken with the technique using sutures to affix the graft is more as compared to glue and suture less and glue-free technique. These times are comparable however they are longer than other studies^{7,12} using fibrin glue which reported average operative time of 16 mins (range 14–16) and 30 mins (range 20–39) in suture group and reported $14(\pm 1.4)$ mins in suture-less and glue free conjunctival autograft. In our study all the surgeries were not done by any particular pair of surgeons or a single surgeon, so time taken for surgery also varies with technique and skill of operating individuals. Our study was conducted over three years of duration, we believe it was worthwhile to provide the patients with the benefits of suture-less and glue free conjunctival limbal autograft.

Our results confirmed significantly lower post-operative signs and symptoms including pain, FB sensation, photophobia, hyperemia and chemosis at all visits in the first post-operative month as well as

significantly higher overall patient satisfaction in group 1 compared to group 2. Percentage of overall satisfaction level in both groups after the end of six months were, there were more highly satisfied patients in group 1(80%) then group 2(60%) and less low satisfied patients in group 1(6%) then group 2(14%). There were 2(4%) patients in group 1 and 3(6%) in group 2, who were unsatisfied after 6 months of surgery because of post - operative complications. P value is 0.180. None of our patients developed any further serious complications such as scleral necrosis, scleral thinning, graft necrosis, symblepharon, excessive bleeding, medial rectus muscle injury, or globe perforation.

CONCLUSION

In this study we compared two surgical techniques of conjunctivo-limbal autograft transplantation (CLAT) after pterygium excision. We compared two groups of patients who underwent pterygium excision surgery. Group 1 – patients who underwent pterygium excision surgery with conjunctivo-limbal autograft (CLAG) with no glue, no suture and only patient's own autologous fibrin blood, were highly satisfied post - surgery. They experienced lesser grade of post-operative pain, discomfort, foreign body sensation and they also showed lesser inflammation, graft edema and lid swelling. They also showed faster healing and recovery.

REFERENCES

1. D Coster: Pterygium:An ophthalmic enigma.Br J Ophthalmol 1995;79.4:304-305.
2. McCarty CA, Fu CL, Taylor HR. Epidemiology of Pterygium in Victoria, Australia Br J Ophthalmol 2000; 81: 289-92.
3. West S, Munoz B. Prevalance of Pterygium in Latinos: Proyecto VER. British Journal Ophthalmology 2009; 93(10): 1287-90.
4. Singh MM, Murthy GV, Venkataraman R. A study of ocular morbidity among elderly population in rural central India. IJO 1997; 45(1): 61-65.

As compared to that, group - 2 patients who underwent pterygium excision surgery with conjunctivo-limbal autograft transplantation using absorbable sutures experienced more or excessive pain, foreign body sensation and discomfort. They showed higher inflammation, congestion, graft edema and subconjunctival hemorrhage. Therefore satisfaction level in these patients after surgery was low.

But, post – operative complications like graft dehiscence, graft retraction and graft loss are comparatively similar or around near in both groups. Recurrence rate in both techniques is also around near, group 1 showed 12% and group 2 showed 10% recurrence within six months of duration, which is acceptable.

So this new technique of affixing conjunctivo-limbal autograft with patients' own blood without using any kind of foreign material like sutures or fibrin glue is more preferred as it is cheaper, more faster or less time consuming, no requirement of surgeon's fine skill of suturing and no need of affording fibrin glue.

Thus, considering all the aspects this new technique can be more preferable for patients as well as surgeons and long duration of follow up should be done.

5. McCarty CA, Lee SE, Livingston PM, Bissinella M, Taylor HR. Ocular exposure to UV-B in sunlight: the Melbourne visual impairment project model. *Bull World Health Organ.* 1996; 74(4):353-360.
6. Luthra R, Leske MC. Frequency and risk factors for pterygium in Barbados Eye study. *Arch Ophthalmol* 2001; 119:1827-32.
7. Wit D, Athanasiadis I, Sharma A, Moore J. Sutureless and glue-free conjunctival autograft in pterygium surgery: A case series. *Eye (Lond)* 2010; 24:1474-7.
8. Tan D. Conjunctival grafting for ocular surface disease. *Curr Opin Ophthalmol* 1999; 10: 277–81.
9. Foroutan A, Beigzadeh F, Ghaempanah MJ, Eshghi P, Amirizadeh N, Sianati H, et al. Efficacy of autologous fibrin glue for primary pterygium surgery with conjunctival autograft. *Iranian J Ophthalmol* 2011; 23: 39–47.
10. Massaoutis P, Khemka S, Ayliffe W. Clinical outcome study of a modified surgical technique for pterygium excision. *Can J Ophthalmol* 2006; 41: 704–8.
11. Malik KPS, Goel R, Gupta SK, Kamal S, Malik VK, Singh S. Efficacy of sutureless and glue free limbal conjunctival autograft for primary pterygium surgery. *Nepal J Ophthalmol* 2012; 4(8): 230–5.
12. Bahar I, Weinberger D, Dan G, Avisar R. Fibrin glue versus vicryl sutures for conjunctival closure. *Cornea* 2006; 25(10):1168–72.