

## Case report:

### Chewing Paan - a rare cause of phyto bezoar with isolated small bowel obstruction

<sup>1</sup>Dr.S.N. Somashekhar , <sup>2</sup>Dr.Reethesh.R. Shetty\*

<sup>1</sup>Professor of Surgery , <sup>2</sup>Junior Resident

Dept of General Surgery , JJMMC , Davangere , India

Corresponding author : Dr.Reethesh.R. Shetty

#### Abstract:

Phytobezoars are very rare cause of mechanical small bowel obstruction accounting for 0.4-4% of cases, primary phytobezoar of small intestine without a parent bezoar of stomach is exceedingly rare. We report an unusual case of 44 year old man with no previous abdominal surgery and no significant medical history, who presented with an acute episode of small bowel obstruction due to phytobezoar secondary to betel leaves pan.

**Key words:** Small bowel obstruction; Phytobezoar

#### Back Ground

Acute small bowel obstruction is a common condition encountered in general surgery practice. Stomach is the most common site for bezoars, which can migrate into small bowel loops and may cause obstruction. Isolated presentation of ileal bezoars in the absence of a parent bezoar in stomach and without history of gastric surgery or underlying pathology is extremely rare phenomenon.<sup>1</sup> Phytobezoars are very rare causes of mechanical small bowel obstruction accounting for only 0.4-4% of all mechanical small bowel obstruction<sup>8</sup>, with only five cases reported from India.<sup>2</sup>

#### Case Report

A 44 year old gentleman was seen at emergency room with complaints of pain abdomen and distension from 2 days associated with non bilious vomiting and constipation. There was no history of surgery of abdomen in the past or any other co-morbidities. On examination patient was dehydrated with a pulse rate of 110/min and blood pressure of 100/70 mm Hg. Abdomen examination revealed a distended abdomen - predominantly in the centre with sluggish bowel sounds, per rectal examination was positive for fecal stain. A working diagnosis of subacute intestinal obstruction was made and patient was resuscitated. Radiological workup showed dilated small bowel loops with air fluid levels on erect x-ray abdomen and dilated loops of jejunum and ileum with

minimal ascites on USG abdomen. Patient taken up for laparotomy.

Laparotomy showed - dilated small bowel loops involving distal jejunum & proximal ileal loops. A mass of 3x3 cm was palpated at the terminal ileum causing obstruction to the lumen. Enterotomy was done and bezoar of betel leaves with arecanut pieces were noted. Piece meal extraction and decompression of the bowel was done, enterotomy closed in two layers abdomen closed with tube drain, postoperative period was uneventful.

In the post-operative recovery time when a directed history was obtained from patient and family members, it was revealed that a day prior to onset of complaints patient had consumed many pieces of betel leaves - pan, which was not revealed at presentation presuming it to be irrelevant. Psychiatry /dietary opinions were taken prior to discharge. Patient was followed up to 6 months post-operatively, there was no complaints of recurrence.

#### Discussion

The term bezoar comes from Arabic "Badzehr" or from Persian "Panzer" meaning counter poison or antidote.<sup>3</sup> Bezoars are defined as abnormal concretions of undigested or partially digested material in gastro intestinal tract, named according to the predominant component material<sup>4</sup>. The most common type -

trichobezoar contains hair, phytobezoar is made of plant substances contains large amount of indigestible material like cellulose, tannin and lignin. Persimmon fruit ingestion is the most common worldwide reported cause of phytobezoar. The other type of bezoar reported include pharmaco bezoar due to drug like cholestyramine or antacids, lactobezoars in infants due to condensed milk and occupational bezoars like cotton bezoar in tailors as observed by Chintamani et al.<sup>1</sup>

Bezoars can occur in any part of gastro intestinal tract but are commonly reported in stomach, usually in the presence of predisposing factors like previous surgery of stomach, excessive fiber consumption, poor dentition, insufficient mastication, diabetic gastroparesis, medications affecting gastric motility and psychiatric ailment as noted by Salemis et al.<sup>5</sup>. Bezoars of small bowel are extremely rare, and occur secondary to migration of a gastric bezoar, isolated presentation in the ileum without a parent bezoar in the stomach is very rare.

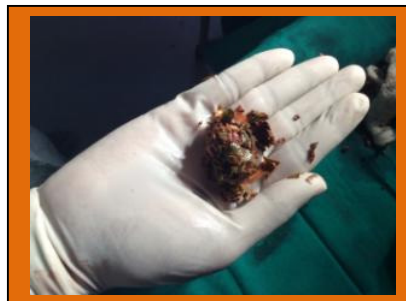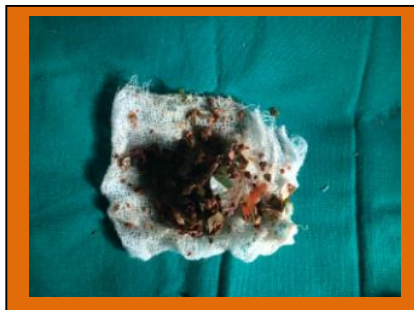
Most common site for phytobezoars in the small bowel is 50-70 cms proximal from the ileocaecal valve<sup>6</sup> due to narrow anatomical location, slow motility and water absorption causing hardening of phytobezoar<sup>6</sup>. Bezoars in the gastric or colonic region are at times detected incidentally, majority of small bowel bezoars present as acute intestinal obstruction with pain abdomen, distension, nausea, vomiting and constipation, in those with history of abdominal surgery in the past making it difficult to differentiate it from adhesions induced obstruction<sup>7</sup>. Phytobezoars show a distinctive geographic clustering of cases with most reports from countries of Mediterranean region and seasonal predilection for autumn and winter months<sup>2</sup>. Imaging studies are helpful in the evaluation and pre-operative

diagnosis. X-ray abdomen will show features of small bowel obstruction pattern and occasionally outline of bezoar can be made out-which is difficult to differentiate from abscess or faeces within colon. Ultra sonogram of abdomen has a diagnostic rate of 88-93%, but is operator dependent and obscured by distended bowel gas.<sup>8</sup> CT abdomen has diagnostic rate of 65-100%) for detection with added advantage of defining extent and complications of bezoars<sup>9</sup>. The defining feature suggestive of phytobezoar is a well defined intraluminal mass with mottled gas appearance associated with an encapsulating wall<sup>9</sup>.

Operative management is the main stay of treatment. Manual fragmentation and pushing it toward caecum can be tried, if not successful enterotomy with extirpation is to be done. Resection and anastomosis is mandated if local complications are present<sup>10</sup>. As one third of cases are associated with multiple intestinal bezoars, thorough exploration is advised to rule out concomitant gastric or intestinal bezoars<sup>5</sup>. As Cases are known, to recur in patient with predisposing conditions, prevention is the strategy including advice regarding proper chewing of food, plenty of liquids with meals and avoidance of high fiber diet<sup>8</sup>.

#### Conclusion

It is rare for phytobezoar secondary to betel leaves (Pan) without a concomitant parent bezoar in stomach. This was an operative surprise since patient did not give any contributory history and presentation was essentially as a case of acute intestinal obstruction. Surgery is the treatment of choice in phytobezoar induced obstruction of small bowel and dietary modification is the best way of prevention.



## References

- 1) Chintamani, et al. Cotton Bezoar-rare cause of intestinal obstruction: case report. BMC surg 2003 Sep 4;3:5.
- 2) AlokTiwari et al - Phytobezoar: a rare causes of acute small bowels obstruction in an innocent abdomen. ABCD A & q B & as Cir Dig 2013; 26 (4): 342-343.
- 3) Shah. D, Desai AB, Isolated Ileal bezoar causing small bowel obstruction-BMJ case Reports 2012; 10.1136.
- 4) Andrus CH, Ponsky JL-Bezoars: Classifications, pathophysiology and treatment. AM J gastroeterol 1988: 83; 476-8.
- 5) Salemis NS et al. Acute surgical abdomen due to phytobezoar induced ileal obstructions. The journal of emergency medicine. 2013: 44 (1) e21-e23.
- 6) AnupamaPujar et al. Phytobezoar: A rare cause of small bowel obstruction. Journal of Clinical and Diagnostic Research, 2013 Oct 7 (10); 2298-2299.
- 7) Oh HS, Namgunget,al- Bezoar induced small bowel obstruction. Journal of the Korean society of coloploctology -2012: 28 (2) 89-93.
- 8) Teng HC, Nawadi O et al, Phytobezoar; an unusual cause of intestinal obstruction. Biomedical Imaging and interventional journal 2005: 1 (1).
- 9) Delabrousse E et al. small bowel bezoar versus small bowel faeces: CT evolution. American Journal of Roentgenology 2008 Nov. 191 (5) 1465-68.
- 10) Bedioui et al: A Report of 15 cases of small bowel obstruction secondaryto phytobezoars: predisposing factors and diagnostic difficulties.Gastroenterologie Clinique etBiologique. 2008; 32 (6-7) 596-600.