

Case report

Hoffmann's syndrome: An atypical neurological manifestation of hypothyroidism

Dr. Prinesh Varghese, Dr. Keni Ravish Rajiv , Dr. Uthaya Sankar

Department of General Medicine, Sri Manakula Vinayagar Medical College and Hospital, Madagadipet, Pondicherry- 605107

Corresponding author: Dr. Prinesh Varghese

Abstract:

The neurological manifestations of hypothyroidism are very unusual to see as initial symptoms and they usually occur late in the course of disease. Muscle hypertrophy is an extremely rare finding in hypothyroid patients. Hypothyroidism presenting as muscle stiffness and muscle pseudo hypertrophy in adults is known as Hoffmann's syndrome. Laboratory investigation in hypothyroid myopathy generally shows increased levels of muscle enzyme. The electrophysiological study may reveal features suggestive of myopathy, neuropathy or mixed pattern. The symptoms and also the serum levels of enzymes return to normal with hormone replacement therapy. We report a case of hypothyroidism with calf muscle hypertrophy and proximal myopathy as the initial symptoms.

Introduction:

Thyroid gland plays an important role in growth, development and metabolic functions of the body. The classic features of hypothyroidism are weight gain, fatigue, constipation, cold intolerance, depression, myxedema, hoarseness of voice and bradycardia.

Features ranging from delayed relaxation of deep tendon reflexes to myopathy can be seen as neuromuscular manifestation. Various types of myopathies are seen in association with hypothyroidism like atrophic form, Myasthenic syndrome, Polymyositis like syndrome, Hoffmans syndrome, and Kocher-Debre-Semelaigne syndrome seen in infants with cretinism.

The common features of myopathy due to hypothyroidism include proximal muscle weakness, muscle cramps, myoedema on percussion, and rarely development of muscle hypertrophy.^[1] Severity of myopathy correlates with the duration and the degree

of thyroid hormone deficiency. Hoffmann's syndrome is an uncommon but specific form of hypothyroid myopathy, which causes proximal muscle weakness and hypertrophy of muscles. Muscular hypertrophy with muscle stiffness is reported in less than 10% of hypothyroid patients.^[2] Hypothyroidism presenting with initial neurological manifestations is very unusual and rare. We report a case of Hoffman's syndrome and this case shows that Hoffmans syndrome, being one of the reversible and treatable causes of myopathy, if diagnosed and treated early has a good prognosis and decreased morbidity.

Case Report

A 23 years old male patient presented with 6 months history of difficulty in using his all four limbs. He noticed difficulty in squatting, getting up from sitting position, dismounting from bed, difficulty in climbing stairs and difficulty in lifting his hands above shoulders. The symptoms progressed insidiously affecting his activities of daily living.

There was no h/o easy fatigability, cold intolerance, loss of appetite, weight gain, or lower limb edema. There was no h/o sensory disturbance, cranial nerve dysfunction, bowel/bladder disturbance or muscle cramps/stiffness.

On examination the patient was moderately built and nourished. His pulse was 66 beats/min regular and blood pressure was 110/80 mmHg with no postural drop. He was pale and had thickened skin with dry coarse hair and alopecia.

Neurological examination revealed normal higher functions and cranial nerves. Muscle power of 4/5 in all four limbs with predominant proximal muscle weakness, and normal tone. There was bilateral hypertrophy of calf muscles. Deep tendon reflexes were diminished including the ankle jerks. Coordination was normal. Sensory system, bowel/bladder functions were normal. Examination of his spine revealed no deformity or tenderness. The rest of the systemic examination was normal.

His initial laboratory investigation showed hemoglobin 9.6g/dl, normocytic normochromic anemia. Renal functions, serum electrolytes, Liver function tests, serum calcium, and urine examination was normal. Thyroid function tests revealed T3 levels of 0.41 pg/dl (normal 0.97- 1.69 pg/dl), a T4 of 0.99 ng/dl (normal 5.53-11.0 ng/dl) and TSH level of 87.9 mIU/ml (normal 0.465-4.68 mIU/ml). Thyroid peroxidase antibody (TPOAb) was positive. Creatine phosphokinase levels were elevated with a value of 820 IU/l (normal <140 U/l). The chest X-ray, ECG and 2D Echocardiography were normal. Electromyography (EMG) showed myopathic motor unit potentials (MUAPs) with small amplitude and duration in the proximal muscles. The nerve conduction study was normal. The muscle biopsy was deferred as the patient was unwilling.

A diagnosis of Hypothyroid Myopathy(Hoffmans syndrome), etiology Hashimotos Thyroiditis was made. The patient was started on oral thyroxin replacement, 100 µg of L-Thyroxin once daily. Patient was followed up weekly and physiotherapy was started. His thyroid profile and muscle enzymes repeated after 8 weeks showed progressive improvement. There was also improvement in his power and patient could climb stairs without support and lift hands above head with minimal difficulty. The patient was advised to continue medications and follow up regularly.

Discussion:

Hoffmann's Syndrome was initially described by Hoffmann in 1897 in a post thyroidectomy patient who developed stiffness and difficulty in relaxation of the muscles following surgery.^[3] The initial presentation of proximal myopathy and pseudo hypertrophy of limb muscles is very uncommon. About 95% of the cases of thyroid insufficiency is mainly due to primary hypothyroidism.

The main cause is Hashimoto's thyroiditis,^[4] which is an autoimmune chronic thyroiditis characterized by increased levels of thyroid peroxidase antibodies (TPOAb) and thyroglobulin antibodies (TgAb). TgAb and TPOAb are seen in almost 100% of patients with Hashimoto's thyroiditis.^[4] The cause of pseudo hypertrophy in Hoffman's syndrome remains complex and needs more exploration. An increase in connective tissue, increase in size and the number of muscular fibers is said to be one of the mechanisms.^{[5],[6]} There is also change in muscle fibers from fast twitching type II to slow twitching type-I fibers,^{[6],[7]} abnormalities in oxidative enzymatic activity and hypertrophy due to accumulation of glycosaminoglycans.^[7] The tongue, arm and leg muscles are usually involved. The

muscle hypertrophy and muscle weakness usually recede following treatment with thyroid hormones.

Elevated level of creatinine phosphokinase is found in thyroid myopathy. The levels may be 10-100 times greater than normal in some patients.^[1] The CPK is the best biochemical marker of myopathies.^[1] CPK is also elevated in other non neuromuscular conditions like hypothyroidism, trauma, and alcohol. There is no relation between the level of CPK and muscle weakness. The CPK levels will fall back to normal following treatment with L- thyroxine but it may take weeks and even months to years in some patients. The electrophysiological study in hypothyroid myopathy may show findings compatible with neurogenic, myogenic, or a mix of those patterns. The EMG findings compatible with myogenic pattern are diminished duration, and amplitude of motor unit potentials.^[8] The voluntary muscle contraction results in early recruitment of short action motor units, spontaneous fibrillations and complex repetitive discharges.^[8] The nerve conduction studies (NCS) may show entrapment neuropathies and axonal sensory motor polyneuropathy.

Our patient presented with predominant proximal muscle weakness and hypertrophy of calf muscles. His CPK levels were elevated 4 times the normal, and TPOAb titers were also elevated. EMG showed myopathic motor unit potentials (MUAPs) with small amplitude in proximal muscles. Nerve conduction study was normal. The patient was started on L- thyroxine (100 µgms once a day) and discharged from hospital. The patient on follow up after 8 weeks of oral thyroxine showed decreased CPK enzyme levels and improvement in muscle power with mild reduction in muscle bulk.

Conclusion:

Hoffmann's syndrome has good prognosis if it is diagnosed at an early onset and treated appropriately. The initial presentation with neurological manifestations can be difficult to diagnose as calf muscle hypertrophy can be present in other diseases like Duchenne & Becker's muscular dystrophy, Amyloidosis, and Focal myositis. There is a significant improvement in course of the disease if proper treatment is given at the right time. Majority of the cases will improve with thyroid hormone replacement alone.

Literature review shows only few such cases reported in India, particularly in our region. This case report shows that Hoffmans syndrome though a rare case presentation of hypothyroidism has a good prognosis with timely diagnosis and appropriate management.

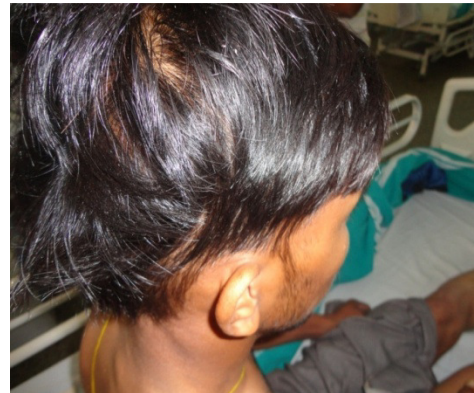

FIG 1: Coarse Hair with Alopecia

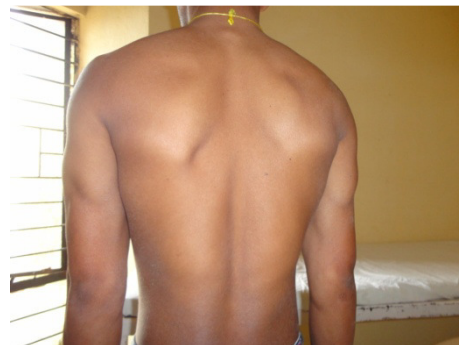

FIG 2A: Hypertrophy of Arm Muscles

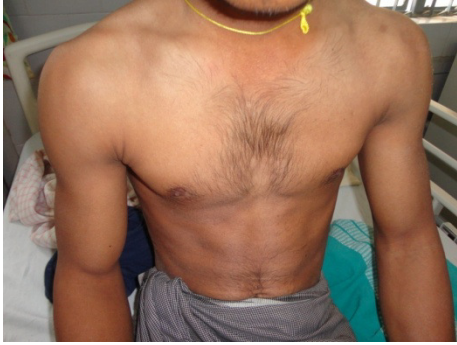

FIG 2B: Hypertrophy of Arm Muscles

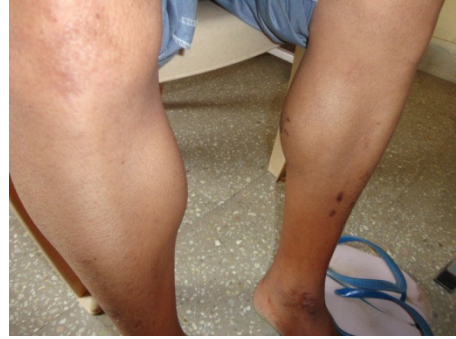

FIG 3A: Hypertrophy of Calf Muscles

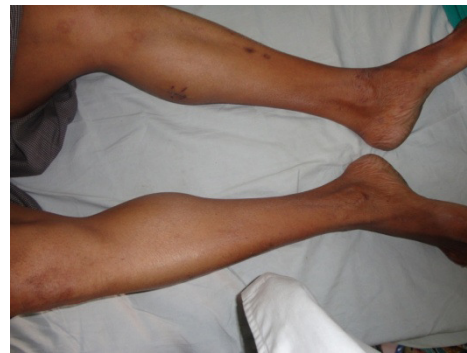


FIG 3B: Hypertrophy of Calf Muscles

References:

- 1) Scott KR, Simmons Z, Boyer PJ. Hypothyroid myopathy with a strikingly elevated serum creatine kinase levels. *Muscle Nerve* 2002;26:141-4.
- 2) Deepak S, Harikrishnan, Jayakumar B. Hypothyroidism presenting as Hoffman's syndrome. *J Indian Med Assoc* 2004;102:41-2.
- 3) Sidibe EH, Diop AN, Thiam A, Diagne PM, Sarr A, Toure M, *et al.* A Hoffmann's Syndrome in hypothyroid myopathy. Report of a case in an African. *Joint Bone Spine* 2001;68:84-5.
- 4) Reed Larsen P, Henry MK, Shlomo Melmed, Kenneth SP. The thyroid gland. In *Williams textbook of endocrinology*, 11thEd. Philadelphia: W.B. Saunders Company; 2008. p. 325.
- 5) Vasconcellos LF, Peixoto MC, de Oliveira TN, Penque G, Leite AC. Hoffman's syndrome: Pseudohypertrophic myopathy as initial manifestation of hypothyroidism. Case report. *Arq Neuropsiquiatr* 2003;61:851-4.
- 6) Udaya kumar N, Ramesh kumar AC, Srinivasan AV: Hoffmann syndrome: Presentation in hypothyroidism. *J Postgrad Med* 2005;51:332-3.

- 7) Ozdag MF, Eroglu E, Ulas UH, Ipekdal I, Odabasý Z, Vural O. Early diagnosis and treatment reverse clinical features in Hoffmann's syndrome due to hypothyroid myopathy: A case report. *Acta Neurol Belg* 2005;105:212-3.
- 8) Duyff RF, Van den Bosch J, Laman DM, van Loon BJ, Linssen WH. Neuromuscular findings in thyroid dysfunction: A prospective clinical and electrodiagnostic study. *J Neurol Neurosurg Psychiatr* 2000;68:750-5.