

Case report

Stress-induced hemorrhagic duodenal ulcer after successful helicobacter pylori eradication

¹Dr.Vijay Kumar Saboo,² Dr.Neha Saboo

¹Senior surgeon in Get Well Hospital and Research Center, Sikar

²Assistant professor in RUHS College of Medical Sciences , Sikar

Corresponding author : Dr.Vijay Kumar Saboo

Abstract

Introduction: Helicobacter pylori infection is a major cause of duodenal ulcers, and Helicobacter pylori eradication drastically reduces ulcer recurrence. It has been reported, however, that psychological and severe physical stress is closely associated with duodenal ulceration even in Helicobacter pylori -negative patients.

Case presentation: We report the cases of a 50 year old female who developed psychological stress-induced hemorrhagic duodenal ulcers, in whom Helicobacter pylori had been successfully eradicated.

Conclusion: Our cases strongly suggest that not only physical but also psychological stress is still an important pathogenic factor for peptic ulceration and accordingly that physicians and surgeon should pay attention to the possible presence of psychological stress in the management of patients with peptic ulcers.

Key word : stress, duodenal ulcer

Introduction

Idea[2], Gray and French[1] and their associates have postulated a neuroendocrine mechanism where by both physical and mental stress can produce a hypersecretion of gastric juice in the stomach leading to the formation of duodenal ulcer or exacerbations in pre-existing lesions.

Since Selye [3] reported that stress induces gastrointestinal ulcers, stress has been a major pathogenic factor for peptic ulceration.. Chen et al. [4] examined 32 non-Hp and non-NSAID duodenal ulcer cases and reported that 15.6% of the cases were closely associated with psychophysical stress. In 2009, Wong et al. [5] revealed that patients with Hp-negative idiopathic bleeding ulcers, in the pathogenesis of which mental stress might play an important role, had a high risk of mortality and recurrent bleeding. Along these lines, we report the case of one patients with psychological stress-

induced hemorrhagic gastric ulcers in whom helicobacterpylori had been successfully eradicated.

Case report

A 50 year-old female visited our hospital seven years ago because of repeated tarry stools. In the previous year, she had developed a gastric ulcer and underwent helicobacterpylori eradication therapy. She did not take NSAIDs or aspirin or drink alcohol, but she smoked an average of 20 cigarettes daily. Before she noticed tarry stools, she had been requested to edit a booklet for a public health and community meeting. She was computer-illiterate and totally unaccustomed to such a task. She reported that her smoking pattern, including the number of cigarettes per day, was unchanged during the stressful period. Laboratory data demonstrated mild anemia (haemoglobin 11.1 g/dL), elevated BUN (33.1 mg/dL) and normal gastrin (25 pg/mL), suggesting the possible presence of gastrointestinal bleeding.

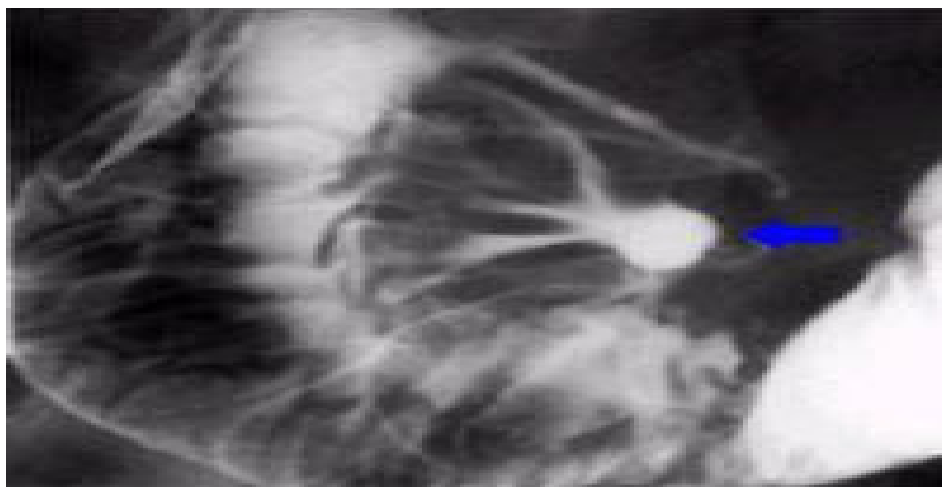

Figure 1-double contrast upper gastrointestinal series of anterior wall duodenal ulcer .

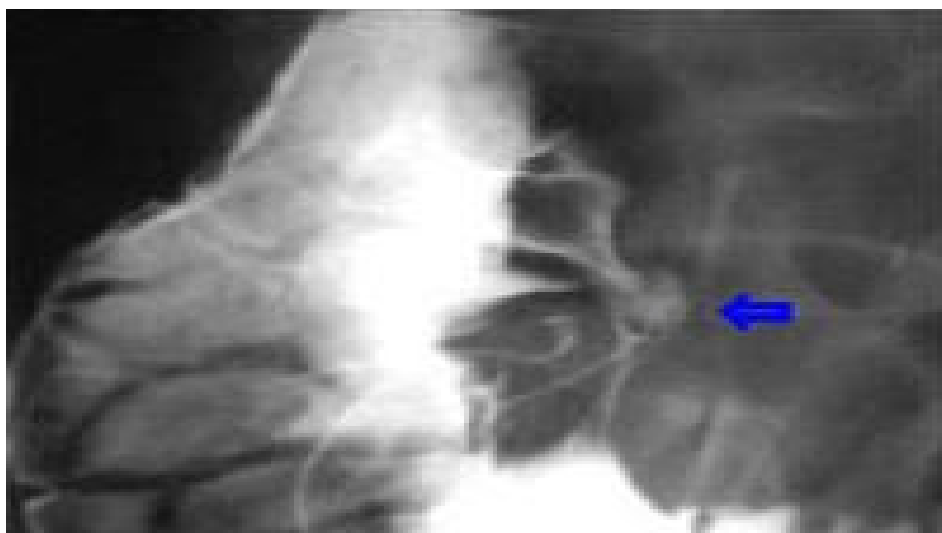


Figure 2..double contrast upper gastrointestinal series , lateral view of anterior wall ulcer

Esophagogastroduodenoscopy revealed a recurrent gastric ulcer without active bleeding.

The absence of Hp infection was confirmed by negative ¹³C-urea breath test, histology and helicobacter pylori antibody. At operation the pylorus was noted to be scarred and slightly deformed. An ulcer in the posterior wall of the duodenum could be palpated through the anterior duodenal wall. A pyloroduodenotomy was made and large, dark red clots as well as bright arterial blood was aspirated. A 2-cm, posterior wall, deep, duodenal ulcer with spurting arterial bleeding was noted.

The vessel in the ulcer base was ligated. The pyloroduodenotomy was closed in a vertical axis as a pyloroplasty and a parietal cell vagotomy done. After a convalescence of 12 days she was discharged, eating five small feedings a day.

.The psychological assessment of the patient profile demonstrated that she was strict with regard to punctuality and had a strong sense of responsibility. These characteristics forced her to complete the task in which she was inexperienced by the deadline. It was therefore considered that his intense emotional stress resulted in his recurrent gastric ulcer.

Discussion

Duodenal and gastric ulcers share the same set of complications, including pain, intractability, perforation, obstruction, and bleeding[6]. Most patients with perforated duodenal ulcers are treated surgically. This is because morbidity and mortality in the average patient are reduced by prompt surgical treatment. What procedure should be done is dependent on two important factors: whether there is a prior history of duodenal ulcer disease for 3 months or more, and evaluation of the patient's overall health, including the duration and degree of peritoneal contamination found at operation[7]. With regard to the first factor, those patients with no history of ulcer disease or with disease of less than 3 months' duration require only simple closure of the perforation[8]. This is because most of these patients, for reasons that are not understood, will have no further difficulty from duodenal ulcer disease. This is particularly true if an acute exacerbating factor has been identified that can be eliminated (e.g., NSAID intake). By contrast, those patients with a history of greater than 3 months will have a highly likely (70–90%) chance of having further severe ulcer complications if the ulcer is simply closed.[8-10] For these reasons, surgeons have sought for prognostic factors that would suggest the safety and effectiveness of a definitive ulcer operation at the time of operation for perforation. These prognostic factors are age (<65), duration of perforation (<6 hours), and degree of contamination (minimal to moderate). Under these circumstances a definitive ulcer operation can be done. A parietal cell vagotomy with simple closure of the ulcer is best, as it has the lowest mortality and morbidity rate, while effectively curing the ulcer in 85–90% of patients.[11]

The term *peptic ulcer disease* is used to connote the benign ulceration of both the stomach and duodenum, as these disease processes share many

features in common, namely, symptoms of epigastric distress or pain related to meals and a favorable response obtained with antacid therapy[12]. Duodenal and gastric ulcers share the same set of complications, including pain, intractability, perforation, obstruction, and bleeding.

The cause of duodenal ulcers is unknown. It is often erroneously attributed to excessive acid production of the stomach. In fact, most patients with duodenal ulcer do not secrete excessive quantities of acid. Acid secretion deservedly receives attention because it can be effectively controlled by medication, and control of acid secretion leads to healing of the ulcer[13]. Current therapy is so effective that earlier complications from ulcer disease, such as intractable pain, bleeding, perforation, and obstruction, are less frequently encountered. Although it is well-established that *Hp* infection is the most important pathogenic factor in peptic ulceration, it has been reported that ulcer recurrence occurs even after *Hp* eradication[5]. The mechanism by which ulcer recurrence takes place in *Hp*-negative patients remains to be clarified, but psychological stress may be associated with its recurrence.

Bleeding is the deadliest complication of duodenal ulcer and of gastric ulcer, accounting for almost all mortality in the surgical treatment of this disease.[9] It has also been demonstrated that psychophysical stress contributed to duodenal ulcer formation among 12.7% of *Hp*-negative ulcer patients [4].

Since Selye [1] reported that stress produced the same symptoms, that is, peptic ulcer, adrenal hypertrophy and thymus atrophy, stress has been considered an important factor in the pathogenesis of ulcer formation. In fact, it has been well-documented that physical stress encountered in the intensive care unit can induce peptic ulcer bleeding

among Hp-negative patients [10-12]. On the other hand, our patients developed hemorrhagic gastric ulcers due to psychological stress rather than to physical pathologies. In other words, our findings strongly indicate that not only physical but also psychological stressors can cause ulcer bleeding in spite of Hp negativity.

Conclusion

In conclusion, our case reports suggest that psychological stress is still an important clinical factor for peptic ulceration. In the management of patients with peptic ulcer, physicians should pay attention to the possible presence of psychological stress as well as physical causes.

References

1. French J.D., R.L. Langneier, R.W. Portter and H.J. Movius: Extra vagal influences on gastric HCL secretion, Induced by stress stimuli surgery, 34:621, 1953
2. Gray, S.J., Jr, Benson, Jr, R.W., Rifenstein and H.M. Spiro: Chronic Stress and peptic ulcer, effect of corticotrophin and cortisone on gastric secretion.
3. Selye H: A syndrome produced by diverse noxious agents. Nature 1936, 138:32-33.
4. Chen TS, Chang FY: Clinical characteristics of Helicobacter pylori-negative duodenal ulcer disease. Hepatogastroenterology 2008, 55:1615-1618.
5. Wong GL, Wong VW, Chan Y, Ching JY, Au K, Hui AJ, Lai LH, Chow DK, Siu DK, Lui YN, Wu JC, To KF, Hung LC, Chan HL, Sung JJ, Chan FK: High incidence of mortality and recurrent bleeding in patients with Helicobacter pylori-negative idiopathic bleeding ulcers. Gastroenterology 2009, 137:525-531.
6. Friedman M, Rosenman RH: Association of specific overt behavior pattern with blood and cardiovascular findings; blood cholesterol level, blood clotting time, incidence of arcus senilis, and clinical coronary artery disease. J Am Med Assoc 1959, 169:1286-1296.
7. Laine L, Hopkins RJ, Girardi LS: Has the impact of Helicobacter pylori therapy on ulcer recurrence in the United States been overstated? A meta-analysis of rigorously designed trials. Am J Gastroenterol 1998, 93:1409-1415.
8. Miwa H, Sakaki N, Sugano K, Sekine H, Higuchi K, Uemura N, Kato M, Murakami K, Kato C, Shiotani A, Ohkusa T, Takagi A, Aoyama N, Haruma K, Okazaki K, Kusugami K, Suzuki M, Joh T, Azuma T, Yanaka A, Suzuki H, Hashimoto H, Kawai T, Sugiyama T: Recurrent peptic ulcers in patients following successful Helicobacter pylori eradication: a multicenter study of 4,940 patients. Helicobacter 2004, 9:9-16.
9. Aoyama N, Kinoshita Y, Fujimoto S, Himeno S, Todo A, Kasuga M, Chiba T: Peptic ulcers after the Hanshin-Awaji earthquake: increased incidence of bleeding gastric ulcers. Am J Gastroenterol 1998, 93:311-316.
10. Schilling D, Haisch G, Sloat N, Jakobs R, Saggau W, Riemann JF: Low seroprevalence of Helicobacter pylori infection in patients with stress ulcer bleeding: a prospective evaluation of patients on a cardiosurgical intensive care unit. Intensive Care Med 2000, 26:1832-1836.
11. Halm U, Halm F, Thein D, Mohr FW, Mössner J: Helicobacter pylori infection: a risk factor for upper gastrointestinal bleeding after cardiac surgery? Crit Care Med 2000, 28:110-113.

12. Robert R, Gissot V, Pierrot M, Laksiri L, Mercier E, Prat G, Villers D, Vincent JF, Hira M, Vignon P, Charlot P, Buruoa C: Helicobacter pylori infection is not associated with an increased
13. Surgery. 1953 Nov; 34 (5):902–903. DRAGSTEDT LR, WOODWARD ER, et al. Secretary ... Stress and Duodenal Ulcer