

Case Report:

A rare anomaly: absence of slips of extensor digitorum tendon for little finger and presence of bifurcation of extensor digiti minimi tendon for little finger

¹ Dr SOMA SAHA, ²Dr SOUMEDHIK DEY , ³Dr AKHTAR UZZAMAN, ⁴Dr SUMITA DUTTA ,
⁵ Dr ANIRBAN SADHU

¹Associate Professor, Calcutta National Medical College , Kolkata

²Assistant Professor, NRS Medical College , KOLKATA

³Associate Professor, Calcutta National Medical College , Kolkata

⁴Associate professor, Calcutta National Medical College , Kolkata

⁵ Associate Professor, R. G. Kar Medical College Hospital, Kolkata

Corresponding author: Dr Soumedhik Dey

Abstract:

The extensor digitorum muscle (EDM) originates from the lateral epicondyle of the humerus via the common extensor tendon, the adjacent intermuscular septa and the antebrachial fascia^{1,2}. It divides distally into four tendons which pass in a common synovial sheath with the tendon of extensor indicis, through a tunnel under the extensor retinaculum and diverge on the dorsum of the hand, one to each finger^{1,2}. The tendon to the index finger is accompanied by the extensor indicis which lies medial (ulnar) to it. The tendon of the extensor digiti minimi attach to little finger with a slip of extensor digitorum tendon. During routine dissection , it has been found that there is presence of three digitorum tendon for index, middle and ring finger, but not for little finger. Also observed that extensor digiti minimi tendon bifurcates and attaches to little finger.

Key word: tendon, extensor digitorum, hand, surgery.

Introduction:

The tendon of extensor digitorum (ED) may be deficit occasionally they are double or tripled in one or more finger with the incidence of such variation more common in index or middle finger(1,2). It is very uncommon to find a bifurcation extensor digiti minimi(EDM) tendon and also absence of ED tendon slip in little finger as observed in this case. To best of our knowledge, even literature do not describe such incidence. Anatomical knowledge of such variation should be considered while performing tendon graft surgeries in hand.

Material and method:

During a routine dissection for undergraduate student in C.N.M.C., we observed a case of 72 years old male cadaver in the department of anatomy, absence of ED tendon for little finger and

bifurcation of EDM tendon was observed in both hand and specimen was photographed(fig1, 2 and 3). The anomalous tendon was also compared to normal arrangement of ED tendon.

Observation and result:

During routine dissection of back of forearm and dorsum of hand in a 72 year old male cadaver we found that there was bifurcation of extensor digiti minimi(EDM) tendon and also absence of ED tendon slip in little finger . The extensor digitorum muscle (EDM) originates from the lateral condyle of the humerus via the common extensor tendon, the adjacent intermuscular septa and the antebrachial fascia^{1,2}. It divides distally into four tendons which pass in a common synovial sheath with the tendon of extensor indicis, through a tunnel under the extensor retinaculum and diverge on the dorsum of the hand, one to each finger^{1,2}.

The tendon to the index finger is accompanied by the extensor indicis (EI) which lies medial (ulnar) to it. The tendon of the extensor digiti minimi (EDM) attach to little finger with a slip of extensor digitorum tendon.

At a distance 2 cm from the extensor retinaculum, the ED tendon exhibited normal arrangement for the index , middle and ring finger, anomalous for the little finger and EDM shows bifurcation for little finger. So ED tendon has three slips. All tendon were inserted into the extensor expansion as usual.

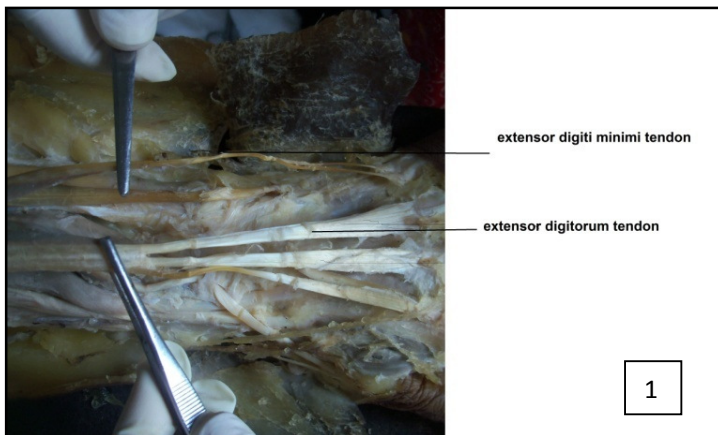
Discussion:

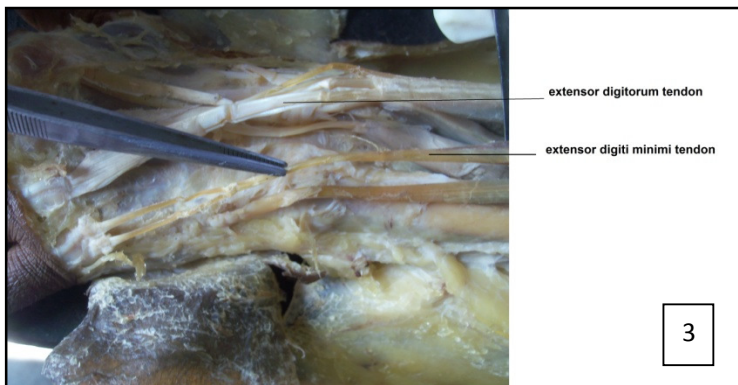
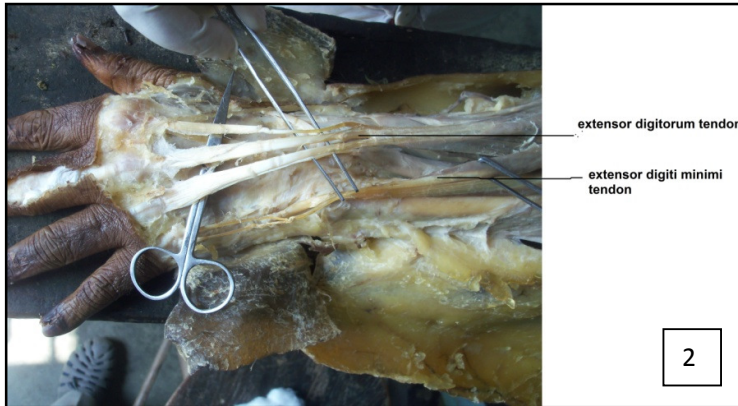
The tendon of ED may exhibit variation in terms of number. The tendon of extensor digitorum (ED) may be deficit occasionally they are double or tripled in one or more finger with the incidence of such variation more common in index or middle finger(1,2).there are double or tripled tendon for the long finger, single or double tendon for the little finger and occasionally double tendon for little finger(3). It was observed previously three slips to the EDM and a separate tendon of ED for little finger.(4) .Zilber S and Oberlin C detected that ED muscle with single tendon to index and middle finger with absence of many tendon in ring

finger(5).Srijit Das reveals additional quadruped tendon for the little finger (6) .Considering to earlier study this study is a rare entity which describes one ED tendon for each digit i.e.index, middle and ring finger with absence of ED tendon for little finger and presence of bifurcation of EDM tendon .Usually, these are found during dissection or hand surgery ,Many time these variation are asymptomatic, thereby lower chance for detection(7). It should be reminded that any successful tenosynovectomy in the treatment of de Quervains disease requires an adequate anatomical knowledge on the extensor tendons (10). Prior anatomical knowledge of the tendons may help in planning tendon graft surgeries. There is synovitis for tendon of 4th and 5th digit and EPL tendon were observed in rheumatoid arthritis in 30% cases(9). So anatomical knowledge is required for surgeries of ED tendon in the present study, we observed absence of ED tendon for index, middle and ring finger and bifurcation of EDM tendon for little finger.

Conclusion:

The present study reported absence of ED tendon for little finger other than three finger and presence of bifurcation of EDM tendon for little finger. This type of anatomical knowledge helps in tendon graft surgeries in the hand.





References:

1. Williams PL et al. Grays Anatomy. The Anatomical Basis of Medicine and Surgery. 38th Edition. Edinburgh, Churchill Livingstone 1997, p. 849-850.
2. Sinnatambay CS. Last's Anatomy. Regional and Applied. 10th Edition, Edinburgh, Churchill Livingstone, 2001, p. 71-72.
3. von Schroeder HP, Botte MJ. Anatomy of the extensor tendons of the fingers: variations and multiplicity. J Hand Surg Amer 1995; 20 (1):
4. Seradge H, Tian W, Baer C. Anatomic variation of the extensor tendons to the ring and little fingers: a cadaver dissection study. Amer J Orthop 1999; 28 (7): 399-401.
5. Zilber S, Oberlin C. Anatomical variations of the extensor tendons to the fingers over the dorsum of the hand: a study of 50 hands and a review of the literature. Surg 2004; 113 (1): 214-221.
6. Das S, Sulaimann I, Latiff A. The additional tendon of the extensor digitorum muscle of the hand: an anatomical study with a clinical significance. Bratisl Lek Listy 2008; 109(12): 584-586
7. Nayak SR, Krishnamurthy A, Prabhu LV, Jiji PJ, Ramanathan L, Kumar S. Multiple supernumerary muscles of the arm and its clinical significance. Bratisl Lek Listy 2008; 109 (2): 74-75.
8. Shiraishi N, Matsumura G. Identification of two accessory muscle bundles with anomalous insertions in the flexor side of the right forearm. Okajimas Folia Anat Jpn 2007; 84 (1): 35-42.
9. Nevasier RJ, Wilson JN, Gardner MM. Abductor pollicis longus transfer for replacement of first dorsal interosseous. J Hand Surg Amer 1980; 5: 53-57.