

Original article:

Optical coherence tomography assisted macular thickness profile in high myopia

Abdul Waris , Mousami Malakar , S N Askari , H Ashraf , Adil Asagar

Department of Ophthalmology, J N Medical College , Aligarh , Uttar Pradesh , India

Corresponding author: Adil Asagar

Abstract

Aims: To study the correlation of high myopia with macular thickness by optical coherence tomography.

Methods and Material: The macular thickness of 50 highly myopic eyes and 40 control (emmetropic) eyes from a north Indian patients was measured using the Fourier domain optical coherence tomography (FD OCT). All highly myopic patients selected for the study had a spherical equivalent of $> -6.0D$ and IOP < 21 mmHg. None of the patients included in the study had evidence of concomitant ophthalmic disease and none had undergone refractive surgery.

Results: The overall mean macular thickness in the myopic groups and control were $262.98 (\pm 24.98) \mu m$ and $290.92 (\pm 11.54)$ respectively. The total macular thickness was less in myopic eyes as compared to emmetropic eyes. But in contrast, the central foveal thickness was $265.43 (\pm 32.69) \mu m$ in myopes and $235.95 (\pm 21.91) \mu m$ in emmetropes. The para and peri foveal retinal thickness was significantly thin in myopic eyes as compared to emmetropic eyes. Whereas central foveal thickness more in the myopes.

Conclusions: Total macular thickness was significantly decreased in myopic eyes as compared to emmetropic eyes. However central (foveal) thickness was significantly high in high myopes as compared to emmetropes. Central foveal thickness increase in high myopes may be confused with retinoschisis / retinal edema. There is therefore a need to have a macular thickness normogram for high myopes of a given population group to avoid wrong interpretation.

Key-words: Macular thickness, OCT (optical coherence tomography), Myopia.

Introduction

Myopia affects a significant proportion of population, particularly in the Asian countries. Few studies have evaluated possible structural changes in the retina in individuals with moderate to high myopia without clinically overt retinal disease.¹ Eyes with refractive error $-6D$ or more are said to be high myopia.² The histopathological changes that accompany high myopia are well documented.³⁻⁵ Contrary to histologic findings and clinical observations that retinal thinning or chorioretinal atrophy is more common in myopia,⁶⁻⁸ The correlation between average macular thickness and myopia has been found to be insignificant in previous *in vivo* imaging (nerve fibre analyser) studies.^{9,10}

Since its introduction in 1991 by Huang *et al*¹¹ the optical coherence tomography (OCT) has become one of the most widely used equipment for assessing the fovea and peripapillary nerve fibre layer in diseases like macular edema, central serous retinopathy, clinically significant macular edema (CSME) in diabetes, wet age related macular degeneration, traumatic macular involvement, macular and non macular retinoschisis, retinal detachment, optic atrophy and chronic glaucomas.

The present study aims to collect the normographic data of high myopes of $\geq 6D$ with respect to thickness of macular region, so as to interpret and distinguish the physiological changes of high myopia from accompanying diseases in such individuals.

Under ideal conditions, optical coherence tomography (OCT) can quantify the thickness of the retina with a resolution of 8 to 10 μm . OCT uses poorly coherent laser interferometry to interpret reflectance data and measure retinal nerve fibre layer thickness and macular thickness, Wakitani *et al*⁹ proposed that the periphery, rather than the central retina, is thinner in myopic eyes.

All this emphasizes us the need to detect changes in the macula accurately at an early stage.

Subjects and Methods

After obtaining clearance from Institutional ethics committee, the present study was carried. Subjects were chosen randomly from the outpatient department of ophthalmology and Retina Clinic, Institute of Ophthalmology. A well informed was obtained from all subjects before examination. Inclusion criteria were: Patients with myopia of $\geq 6\text{D}$, Emmetropic subjects, Intraocular pressure $< 21\text{mm Hg OU}$, No glaucomatous changes such as disc haemorrhages and glaucomatous cupping. Exclusion criteria were: glaucoma, refractive surgery, neurological disease, diabetes mellitus, hypertension and any other systemic illness needs chloroquine or hydroxychloroquine. Subjects were divided into two groups: Group I- pts with high myopia ($\geq 6\text{ D}$) and Group II- emmetropic subjects. So, 50 high myopic eyes and 40 emmetropic eyes were participated. In the present study, Macular thickness was measured by fourier domain optical coherence tomography (Optovue RTVue model RT100). The fast macular thickness scanning protocol was used. The calculation of macular thickness was based on the 6mm retinal thickness map analysis printout. The map was composed of 9 sectorial thickness measurements in three concentric circles with diameters of 1, 3, and 6 mm. The central 1mm circular region represented the fovea. The area bounded by the outer (6mm) and middle (3mm) circles formed the outer ring (para-

fovea) and the area bounded by middle (3mm) and inner circles (1mm) formed the inner ring (perifovea).The perifovea and parafovea were further divided into four quadrant zones: temporal, superior, nasal and inferior study and data acquisition. **(FIGURE 1&2)**

Analysis of the collected data was done using SPSS version 20. Variables were expressed as mean \pm standard deviation. Significance of difference of macular thickness between myopic and emmetropic was determined by using unpaired t-test, quadrant comparison by paired t-test. P value ≤ 0.05 were considered statistically significant.

Results

In the present study, 50 eyes of high myopic and 40 eyes of emmetropic subjects were enrolled. In both groups age of subjects varied from 11 to 40 years. The mean spherical equivalent (SE) of refractive errors of myopes (Group I) was $-10.48 \pm 0.08\text{ D}$ and range -6.5 to -18 D .

In our study, the mean macular thickness was significantly less in myopic eyes (group I) as compared to emmetropic eyes (group II).

Zone wise macular thickness

The zonal macular thickness measurements in each group are summarised in table 02, 03 and 04 respectively. The total macular thickness was less in myopic eyes as compared to emmetropic eyes.

But in contrast, the fovea was significantly thick ($p < 0.0001$) in myopic eyes as compared to emmetropic eyes.

In the parafoveal area (inner ring) retinal thickness was significantly thin in group I (myopic eyes) as compared to group II (emmetropic eyes).

Each zone of parafoveal area of myopic eyes was compared with similar zone of emmetropic eyes. Statistical analysis revealed that thinning of all the zones in parafoveal area in high myopes was highly significant. **(Table 03)**

The intergroup comparison of parafoveal zones in group I revealed the parafoveal area of macula in nasal quadrant was the thickest and temporal quadrant was thinnest. However the intragroup comparison was statistically highly significant when temporal quadrant was compared with superior and nasal quadrant, and superior quadrant in comparison with nasal quadrant. (p value <0.0001 on PAIRED T-TEST)

Similar analysis in group II (Emmetropes), showed the parafoveal area of macula was thickest in superior quadrant and thinnest in inferior quadrant. The interzonal comparison was statistically significant when temporal quadrant was compared with superior and nasal quadrants.

Similarly in the perifoveal area (outer ring) retinal thickness was significantly thin in group I (myopic eyes) as compared to group II (emmetropic eyes). Each zone of perifoveal area of myopic eyes was compared with similar zone of emmetropic eyes and statistical analysis revealed highly significant thinning of all the zones in perifoveal area in high myopes. (Table 04)

Interzonal comparison in group I (myopes) was statistically highly significant when temporal quadrant was compared with superior and nasal quadrant (p <0.0001 on paired t-test), and significant when superior quadrant was compared with nasal quadrant (p = 0.01 on paired t-test).

However, in group II (Emmetropes) the interzonal comparison of perifoveal area was statistically insignificant (p value <0.05).

Discussion

Foveal thickness is a strong and independent predictor of clinically significant macular oedema. Macular thickness changes have shown to be well correlated with changes in visual function and retinal nerve fibre layer (RNFL) structure in diabetes and glaucoma.

Tewari et al. measured the minimum foveal thickness $149.16 \pm 21.15 \mu\text{m}$ using macular thickness protocol scan. They also illustrated various studies showing high variation in foveal thickness might be due to OCT model and methodologies.¹²

Pradhan et al. estimated the mean foveal thickness in South Indian population $186.07 \pm 23.34 \mu\text{m}$ (range 127-269) μm .¹³

Choovuthayakorn et al measured on 368 Thai healthy adult and found that mean foveal thickness was $259.19 \pm 19.08 \mu\text{m}$ using SD-OCT.¹⁴

Chan et al. measured on 37 healthy adult and observed mean foveal thickness was $252 \pm 20 \mu\text{m}$.¹⁵

Appukuttan et al observed normal central foveal thickness in healthy Indian eyes measured using Spectralis OCT was $260.1 \pm 18.19 \mu\text{m}$.¹⁶

Adhi et selected 220 subjects had a mean age of 45.3 years (16–80 years). Using the ETDRS map, foveal thickness for all subjects was measured to be $229.6 \pm 20.46 \mu\text{m}$.¹⁷

Al Haddad et al. measured on 108 children (6-17 yrs) and found the mean foveal thickness was $249.1 \pm 20.2 \mu\text{m}$.¹⁸

Ooto et al calculated mean foveal thickness was $222 \pm 19 \mu\text{m}$ by using SD-OCT in 248 normal eyes of 248 Japanese subjects.¹⁹

In our study, we got mean foveal thickness $235.95 \pm 21.91 \mu\text{m}$. Our finding corroborates with recent literatures and SD-OCT model used studies. The recent OCT models, Manual Vs Automatic software, radial Vs linear and Time domain Vs Spectral domain are possible reasons of variable mean foveal thickness.

The present study was conducted to elucidate the changes of high myopia. In the present study we found, the overall mean macular thickness was highly significantly less in all age group of myopic eyes (group I) as compared to emmetropic eyes (group II). But in contrast, the fovea (central zone) was highly significantly thicker (p <0.0001) in myopic eyes as compared to emmetropic eyes (group II).

Sung-Won Choi *et al*⁴ (2006) conducted a study in Korean adults and Marcus C. C. Lim *et al*⁵ in Asians, they observed foveal thickness increased with myopia.

A study done by Dennis Shun Chiu Lam. *et al*²⁰ in Chinese population in 2005, they found the average foveal (1mm) thickness was significantly higher in the high myopes than low to moderate myopes (p=0.002). In our study, the parafoveal area (inner ring) retinal thickness was very highly significantly thin in myopic eyes as compared to emmetropic eyes.

Each zone of parafoveal area of myopic eyes was compared with similar zone of emmetropic eyes. Statistical analysis revealed highly significant thinning of all the zones in parafoveal area in high myopes.

The comparison of a parafoveal zone with other parafoveal zones in myopes revealed the parafoveal area of macula in nasal quadrant was the thickest and temporal quadrant was thinnest. However this differences of parafoveal zones was statistically highly significant when temporal quadrant was compared with superior and nasal quadrant, and superior quadrant in comparison with nasal quadrant (p value <0.0001 on paired t-test).

Similar analysis in group II (Emmetropes), showed the parafoveal area of macula was thickest in superior quadrant and thinnest in inferior quadrant. The interzone comparison was statistically significant when temporal quadrant was compared with superior and nasal quadrants.

Similarly in the perifoveal area (outer ring) retinal thickness was very highly significantly thin in myopic eyes as compared to emmetropic eyes. Each zone of perifoveal area of myopic eyes was compared with similar zone of emmetropic eyes and statistical analysis revealed highly significant thinning of all the zones in perifoveal area in high myopes.

Interzone comparison in myopes was statistically highly significant when temporal quadrant was compared with superior and nasal quadrant (p value 0.0001 on paired t-test), and significant when superior quadrant was compared with nasal quadrant (p value 0.01 on paired t-test). However, in group II (Emmetropes) the interzone comparison of perifoveal area was statistically insignificant (p value <0.05).

A study was done by P-C Wu *et al*²¹ in 2007 to compare the macular retinal thickness and macular volume between subjects with high myopia and non myopia. They took 80 high myopic eyes and 40 non myopic eyes; they found that the retinal thickness in individuals with high myopia is thicker in the foveola and fovea, but thinner in the inner and the outer macular region.

In myopic eyes, the elongation of the globe leads to mechanical stretching and thinning of the retina. It is conceivable that the extent of the elongation would be related to the degree of retinal thinning. The lack of correlation between axial length/refractive error and retinal thickness in previous studies had been attributed to various causes. In an optical coherence tomography (OCT) macular thickness study, Wakitani *et al*⁹ proposed that the periphery, rather than the central retina, is thinner in myopic eyes. The absence of large blood vessels and optic nerve fibres could render the peripheral retina less resistant to traction and stretch, and the decrease in peripheral retinal thickness may compensate for the stretching force over the entire retina to preserve the central retinal thickness. This conclusion is supported by Lim *et al*⁵ who also suggested that retinal thinning in myopia is more common in the peripheral retina. They found that the outer ring (3–6 mm), but not the inner ring (1–3 mm), macular thicknesses decreased in eyes with a greater degree of myopia.

Mrugacz *et al*²² who showed that as myopia increased, the thickness of fovea decreased while the thickness of peripapillary retinal nerve fibre layer remain unchanged.

In our study para and peri macular thickness was significantly less in high myopic but central (foveal) thickness was more in myopic. The present study therefore emphasizes the need to have

macular thickness normogram for high myopes for a given population group to avoid wrong interpretation. High myopia may also be associated with macular edema and macular retinoschisis these conditions also give rise to increase in central macular thickness. Low sample size is limitations of study so, further consolidation of facts needs large sample size study.

Table 1: Showing mean macular thickness in myopic eyes (group I) and emmetropic eyes (group II)

Macular thickness	Group I (Myopes)	Group II (Emmetropes)	95% CI	P value (Unpaired t- test)
Average thickness (overall)	262.98 (±24.98)	290.92 (±11.54)	-36.45 to -19.42	<0.0001

Table 02: Showing Foveal thickness in group I (myopes) and group II (emmetropes)

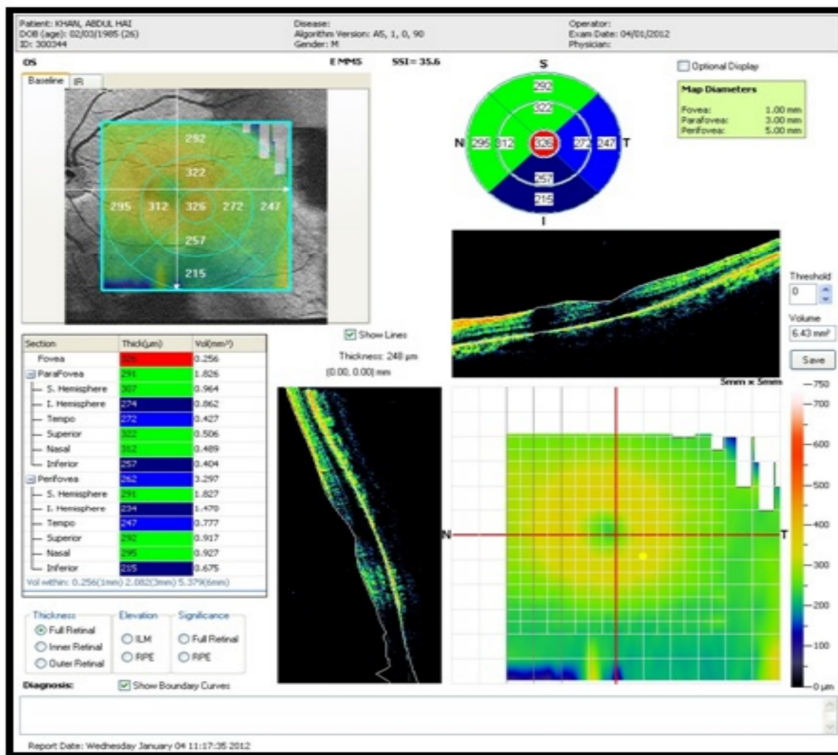
Macular thickness	Group I (Myopes)	Group II (Emmetropes)	95% CI	P value (unpaired t- test)
Fovea (SD) µm	265.43 (±32.69)	235.95 (±21.91)	-17.46 to -41.49	< 0.0001

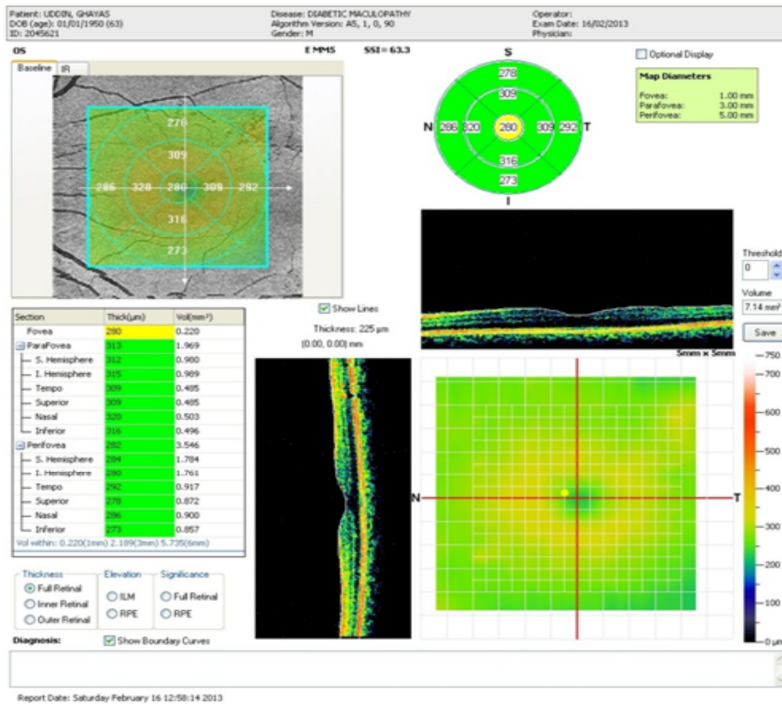
Table 03: Showing inner macular thickness (parafovea =3mm) in myopes and emmetropes

Retinal thickness(µm)± SD	Group I (myopes)	Group II (Emmetropes)	95% CI	P value (Unpaired t-test)
Total parafoveal thickness	279.04 (±29.72)	304.85 (±22.92)	-37.16 to -14.45	<0.0001
Temporal	264.69 (±36.33)	295.86 (±09.83)	-42.93 to -19.41	<0.0001
Superior	272.32 (±44.93)	312.57 (±16.02)	-55.08 to -25.42	<0.0001
Nasal	282.74 (±27.18)	312.55 (±15.51)	-39.37 to -20.18	<0.0001
Inferior	268.44 (±29.67)	307.42 (±14.09)	-49.12 to 28.84	<0.0001

Table 04: Outer macular thickness (peri fovea = 6mm) in myopes and emmetropes

Retinal thickness (µm) ± SD	Group (Myopes)	I Group (Emmetropes)	II 95% CI	P value (unpaired t-test)
Total perifoveal thickness	256.68 (±33.38)	286.25 (±20.57)	-48.57 to -17.58	<0.0001
Temporal	242.28 (±33.22)	279.72 (±16.90)	-48.91 to -25.96	<0.0001
Superior	256.56 (±40.27)	282.15 (±18.70)	-39.30 to -11.87	<0.0001
Nasal	263.12 (±38.23)	304.99 (±17.67)	-54.83 to -28.85	<0.0001
Inferior	240.97 (±37.34)	286.05 (±16.92)	-57.75 to -32.40	<0.0001





References:

1. Lim MC, Hoh S, Foster PJ, et al. Use of optical coherence tomography to assess variations in macular retinal thickness in myopia. *Invest Ophthalmol Vis Sci* 2005; 46:974–8.
2. Ho T, Shih Y, Lin S, Lin LL, Chen M. Peculiar arcuate scotoma in pathologic myopia-optical coherence tomography to detect peripapillary neural tissue loss over the disc crescent. *Graefes Arch Clin Exp Ophthalmol* 2005; 243:689–94.
3. Leung CK, Mohamed S, Leung KS, et al. Retinal nerve fiber layer measurements in myopia: an optical coherence tomography study. *Invest Ophthalmol Vis Sci* 2006; 47:5171–6.
4. Choi S, Lee S. Thickness changes in the fovea and peripapillary retinal nerve fiber layer depend on the degree of myopia. *Korean J Ophthalmol*. 2006; 20:215–9.
5. Hoh S, Lim MC, Seah SK, et al. Peripapillary retinal nerve fiber layer thickness variations with myopia. *Ophthalmology* 2006; 113:773–7.
6. Yanoff M, Fine BS. *Ocular Pathology: A Text and Atlas*. Harper & Row Philadelphia. 1982; 513–514.
7. Spencer WH. *Ophthalmic Pathology: an Atlas and Textbook*. WB Saunders Philadelphia 1985; 3rd ed.395–400.
8. Curtin BJ, Karlin DB. Axial length measurements and fundus changes of the myopic eye. *Trans Am Ophthalmol Soc*. 1970; 68:312–334.
9. Wakitani Y, Sasoh M, Sugimoto M, et al. Macular thickness measurements in healthy subjects with different axial lengths using optical coherence tomography. *Retina*. 2003; **23**:177–182.
10. Zou H, Zhang X, Xu X, et al. Quantitative in vivo retinal thickness measurement in Chinese healthy subjects with the retinal thickness analyzer. *Invest Ophthalmol Vis Sci*. 2006; 47:341–347.
11. Huang D, Swanson EA, Lin CP, et al. Optical coherence tomography. *Science*. 1991; 254:1178–1181.

12. Tewari HK, Wagh VB, Sony P, Venkatesh P, Singh R. Macular thickness evaluation using the optical coherence tomography in normal Indian eyes. *Indian J Ophthalmol* 2004; 52:199-204.
13. Pradhan ZS, Braganza A, Abraham LM: Determinants of macular thickness in normal Indian eyes. *Journal of Clinical Ophthalmology and Research* ; 2013;1 (1):11-16.
14. Choovuthayakorn J, Watanachai N, Chaikitmongkol V, Patikulsila D, Kunavisarut P, Ittipunkul N: Macular thickness measured by spectral-domain optical coherence tomography in healthy Thai eyes. *Japanese Journal of Ophthalmology*; 2012; 56(6):569-74.
15. Chan A, Duker JS, Ko TH, Fujimoto JG, Schuman JS: Normal Macular Thickness Measurements in Healthy Eyes Using Stratus Optical Coherence Tomography; *Arch Ophthalmol*. 2006 February; 124(2): 193–198.
16. Appukkuttan B, Giridhar A, Gopalakrishnan M, Sivaprasad S: Normative spectral domain optical coherence tomography data on macular and retinal nerve fiber layer thickness in Indians; *Indian journal of ophthalmology*;2014, 62(3):315-321.
17. Adhi M, Aziz S, Muhammad K, Adhi MI: Macular Thickness by Age and Gender in Healthy Eyes Using Spectral Domain Optical Coherence Tomography; *PLoS ONE* | www.plosone.org ; 2012;7 (5) :1-6.
18. Al-Haddad C, Barikian A, Jaroudi M, Massoud V, Tamim H, Nouredin B: Spectral domain optical coherence tomography in children: normative data and biometric correlations; *BMC Ophthalmology* 2014, 14(53):1-8.
19. Ooto S, Hangai M, Sakamoto A, Tomidokoro A, Araie M, Otani T, et al. Three-Dimensional Profile of Macular Retinal Thickness in Normal Japanese Eyes; *IOVS*, 2010, 51(1):465-473.
20. Dennis Shun Chiu Lam, Leung SK, Mohamed S, Chan W, Palanivelu MS, Cheung CY et al. Regional variation in the relationship between macular thickness measurements and myopia. *The association for research in vision and ophthalmology, Inc.* 2006;
21. P C Wu, Y J Chen, C H Chen, Y H Chen, S J Shin H J Yang et al. Assessment of macular thickness and volume in normal eyes and highly myopic eyes with third generation optical coherence tomography. 2007:551-555
22. Mrugacz M, Bakunowicz-Lazarczyk A, Sredzinska-Kita D. Use of optical coherence tomography in myopia. *J Peads Ophthalmol Strabismus*. 2004; 41:159–162.