

Original Article

To compare post operative outcome of Toric IOL by two different methods of marking, air bubble VS slit lamp.

Dr O P Anand¹, Dr S K Choudhary², Dr Saloni Gupta³, Dr Shikha Gupta⁴

¹ HOD, EYE Department, NRCH

² Sr DMO, Eye Department, NRCH

³ ADMO, Eye Department, NRCH

⁴ Resident, Eye Department, NRCH

Northern Railway Central Hospital, New Delhi

Corresponding Author : Dr O P Anand

ABSTRACT

Introduction – Toric IOLs correct astigmatic refractive error along with spherical refractive error in a cataract surgery patient.

AIM - To compare the the post operative outcome of Toric IOL by two different methods of marking, air bubble vs slit lamp

Materials and Method - It is a prospective randomized comparative study conducted at tertiary level hospital. Total 40 suitable eyes enrolled and randomized into two groups of 20 each. In group A, the preoperative marking was done with the help of air bubble marker under torch light. Where as in group B, the marking was done at slit lamp with the help of horizontal beam. Post operatively visual acuity and refractive status was evaluated up to 6 months. The observed results were analyzed with appropriate statistical method.

Results- At the final follow up at 6 months, the outcome between two groups observed no statistically significant difference. Mean UCVA (+/-SD) with bubble marker was 0.07+/-0.09 and with slit lamp was 0.03+/-0.06 logMAR units (p value 0.080). Mean BCVA with bubble marker was 0.04+/-0.07 and with slit lamp was 0.07+/-0.23 logMAR (p value 0.743). Mean refractive cylinder with bubble marker was -0.62+/-0.37D and with slit lamp was 0.56+/-0.32 (p value 0.439). The results were not statistically significant.

Conclusion - Both the methods of preoperative marking (air bubble marking and slit lamp marking) are equally

Introduction -

Cataract surgery in recent years has evolved not merely as a visual rehabilitation procedure but also as a modality for correcting refractive error to achieve emmetropia. This has been marked with the development of accurate biometry and toric intraocular lens, which was devised by Shimizu et al in 1994 and is been used clinically since then. Astigmatism is a type of refractive error, which is caused by corneal shape or lens shape or a combination of both. Significant corneal astigmatism is found in about 20% of patients undergoing cataract surgery. Broadly there are two types of astigmatism regular and irregular. Only regular type of astigmatism can be corrected with toric lens

Toric IOLs are available in two models, in the bag fixated and in the sulcus fixated like spherical IOLs. In majority of cases in the bag fixated IOL is preferred taking into consideration the rotational stability as main factor. Astigmatic keratotomies, paired corneal incisions, limbal relaxing incisions were used to correct pre existing corneal astigmatism during cataract surgery. These procedures are unpredictable and results are not measurable. There effect

is usually not long lasting and tends to regress with time. These shortfalls and demerits are taken care by toric IOL, leading to its need and acceptance. The study looked at the visual outcomes in term of comparison air bubble marker and slit lamp marker in patients undergoing cataract surgery with toric IOL implantation, having pre existing corneal astigmatism of more than one dioptre but less than three dioptres at corneal plane.

Aim and objectives –

To compare the the post operative outcome of Toric IOL by two different methods of marking, air bubble vs slit lamp

Materials and Method -

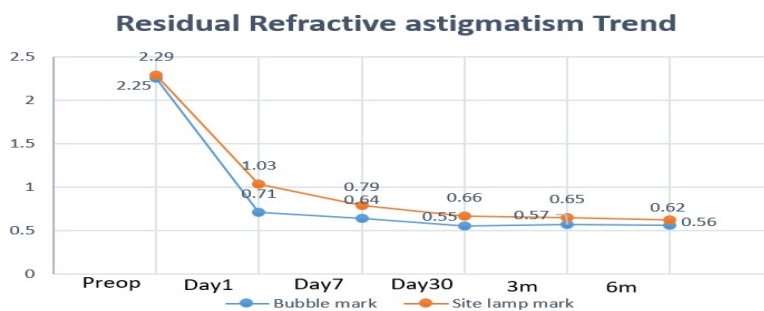
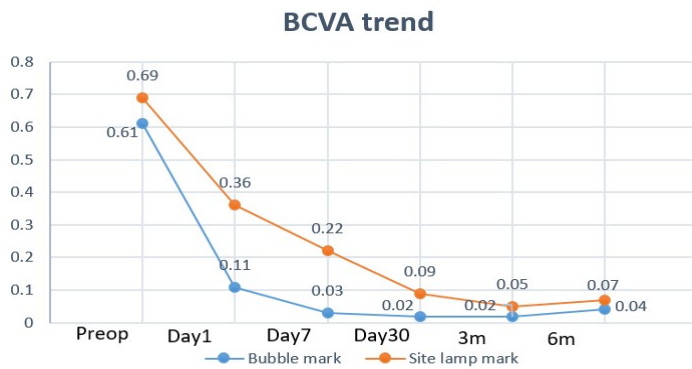
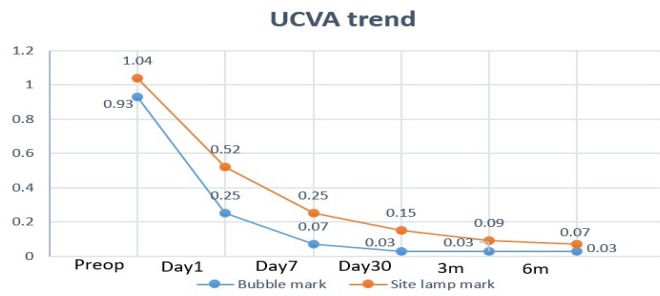
This is a prospective randomized comparative study conducted at eye department of NRCH New Delhi, a tertiary level teaching hospital. A total of 40 eyes of 36 patients, having visually significant cataract along with corneal astigmatism in the range of 1D to 3D enrolled in the study and randomized into two equal groups after matching all inclusion and exclusion criteria. All patients then underwent meticulous refractive and corneal workup to accurately assess the corneal astigmatism. After this A scan biometry was done to calculate the spherical component of IOL to be implanted. The surgically induced astigmatism (SIA) of operating surgeon is already known to be fed into online toric calculator along with keratometric value, IOL power, corneal topography and site (130 degree) of incision.

Standard pre operative protocol for cataract surgery cases were divided into two groups – 1. Bubble marking 2. Slit lamp. In bubble marking group, patient is asked to sit in such a position that eyes level of doctor and patient is same and facing each other. Topical anaesthesia drops put in the concerned eye and patient is asked to look far behind doctor at same level with other eye. The limbus at 3, 6 and 9 o clock is dried with dry cotton bud after placing Barraquer wire speculum. Under torch light, Storz air bubble marker is inked with marker pen and applied at limbus, keeping air bubble at centre of the liquid to obtain marks at 0 degree, 6 o clock and 180 degree. In slit lamp method, patient is asked to sit at slit lamp at same eye level and asked to look far target behind doctors head. Slit lamp beam of 1mm by 10mm kept horizontal at centre of cornea. Marking is done with pointed and inked needle at 0 degree and 180 degree after topical anesthesia.

Cataract surgery performed by standard phacoemulsification method with placement of toric IOL at desired angle. Post operatively patient is followed at day 1, week 1, one month and six month to evaluate UCVA, BCVA, Keratometry and refraction. Also at each visit dilated pupil examination is also conducted to assess the the IOL and its position.

Results

At final follow up of six months, the outcome between two groups showed no significant difference. Mean (+/- SD) UCVA with bubble marker and slit lamp marker was 0.07 +/- 0.09 and 0.03 +/- 0.06 logMAR respectively (p value 0.080). Mean (+/- SD) BCVA with bubble marker and slit lamp marker was 0.04 +/- 0.07 and 0.07 +/- 0.23 logMAR respectively (p value 0.743). Mean refractive cylinder with bubble marker was 0.62 +/- 0.37D and with slit lamp marker was 0.56 +/- 0.32. The results were not significant (p value 0.439). Similarly there was no difference between two groups in terms of rotational stability. Mean deviation from axis was 0.2 +/- 0.89 degree in bubble marker Vs 0.5 +/- 2.24 degree in slit lamp marking system with p value 0.971.



Discussion

Our study clearly suggest that toric IOL implantation is an effective tool in correcting corneal astigmatism with excellent stability. The marking in both the methods is done in sitting position to avoid cyclorotation . In a comparative study done by Popp et al, comparison between 3 groups was done between slit lamp, bubble marker and pendulum marker. They found no statistical significant difference between slit lamp and pendulum marker, where as the difference between air bubble marker and pendulum marker was significant. An Indian study by Farooqui et al compared bubble marker with slit lamp marker and found no statistical difference. Our results also showed that there is no statistical significant difference between air bubble marker and slit lamp marker in terms of accuracy .

Conclusion

Toric IOL significantly improves unaided visual out come and also provides good level of patient satisfaction. In conclusion, toric IOL are safe and effective method to reduce moderate corneal astigmatism post cataract surgery and both the methods of pre operative markings i.e. air bubble marker and slit lamp marker are equally effective and accurate in terms of lens alignment.

REFERENCES

1. Shimizu, Misawa, A. & Suzuki, Y. Toric intraocular lenses: correcting astigmatism while controlling axis shift. *J. Cataract Refract.Surg.*20,523-526 (1994)
2. Hoffer K. J. Biometry of 7,500 cataractous eyes. *Am. J. Ophthalmol.* 90, 360-368 (1980).
3. Vitale S., Ellwein, L., Cotch, M. F., Ferris, F. L. & Sperduto, R. Prevalence of refractive error in the United States, 1999-2004. *Arch. Ophthalmol. Chic.* 111 1960 126, 1111-1119 (2008).
4. Hoffer K. J. Biometry of 7,500 cataractous eyes. *Am. J. Ophthalmol.* 90, 360-368 (1980)
5. Desai P., Reidy, A., Minassian, D. C., Vafidis, G. & Bolger, J. Gains from cataract surgery: visual function and quality of life. *Br. J. Ophthalmol.* 80, 868-873 (1996)
6. A K Khurana, *Theory and Practise of Optics and Refraction*, 3rd edition, Chapter 3, page 77-79.
7. Visser N. et al. Cataract surgery with toric intraocular lens implantation in patients with high corneal astigmatism. *J. Cataract Refract. Surg.* 37, 1403-1410 (2011).
8. Bauer N.J.C., de Vries, N.E., Webers, C.A.B., Hendrikse, F. & NUIJTS, R.M.M.A. Astigmatism management in cataract surgery with the AcrySof toric intraocular lens. *J. Cataract Refract. Surg.* 34, 1483-1488 (2008).
9. Novis C. Astigmatism and toric intraocular lenses. *Curr. Opin. Ophthalmol.* 11, 47-50 (2000)
10. Dada T., Titiyal, J.S. & Sharma, N. Combined astigmatic keratotomy with corneal valvular incision in the treatment of high surgical astigmatism. *Aust. N.Z.J. Ophthalmol.* 26, 261-262 (1998).
11. Mendicute J. et al. Toric intraocular lens versus opposite clear corneal incisions to correct astigmatism in eyes having cataract surgery. *J. Cataract Refract. Surg.* 35, 451-458 (2009).
12. G.K. Krieglstein, R.N. Weinreb. *Cataract and Refractive surgery*, Progress iii, Springer.
13. WHO Blindness : Vision 2020-The Global Initiative for the Elimination of Avoidable Blindness. Available at: <http://www.who.int/mediacentre/factsheets/fs213/en/> (Accessed: 18th June 2017)
14. Pascolini D. & Mariotti, S. P. Global estimates of visual impairment : 2010. *Br. J. ophthalmol.* 96, 614-618 (2012).
15. Horvath K., Constantinescu, D., Vultur, F. and Muhlfay, G (2014). Premium Intraocular Lenses : Patient satisfaction . *Acta Media transilvanica.* 19, 228-230.
16. Gullstrand A 1924. Mechanism of accommodation . *Helmholtz's treatise on physiological optics*, Vol 1 (Trans . from the 3rd German ed.) . Rochester , NY, US: Optical Society of America.
17. Ong H S ., Evans, J. R. and Allan , B. D. (2014). Accommodation intraocular lens versus standard monofocal intraocular lens implantation in cataract surgery . *Cochrane Database of systemic Reviews.*

18. Al Ghouli K. J., Nordgren, R.K., Kuszak, A.J., Freil, C.D., Costello, M. J and Kuszak, J.R. (2001). Structural evidence of human nuclear fiber compaction as a function of ageing and cataractogenesis. *Experimental Eye Research*. 72, 199-214.
19. Pollreis A. and Schmidt-Erfurth, U. (2010). Diabetic cataract-pathogenesis, epidemiology and treatment. *Journal of ophthalmology*. 2010, 1-8.
20. Asbell P., Dulan, I., Mindel, J., Brocks, D., Ahmad, M. and Epstein, S. (2005). Age-related cataract. *The Lancet*. 365, 599-609.
21. Schemann J.-F., Bakayoko, S. and Coulibaly, S. (2000). Traditional couching is not an effective alternative procedure for cataract surgery in Mali. *Ophthalmic Epidemiology*. 7, 271-283.
22. Saxena R.C. (1965). Couching and its hazards (a review of 62 cases). *Indian Journal of Ophthalmology*. 13, 100-104.
23. Signes-Soler I., Javaloy, J., Montes-Mico, R and Munoz, G (2012). Cataract surgery in West Africa: is couching still a choice? *Acta Ophthalmologica*. 90, e488-489.
24. Rabiou M. M. (2001). Cataract blindness and barriers to uptake of cataract surgery in a rural community of Northern Nigeria. *British journal of Ophthalmology* 85, 776-780.
25. De Silva S. R., Riaz, Y. and Evans, J. R. (2014). Phacoemulsification with posterior chamber intraocular lens versus extracapsular cataract extraction (ECCE) with posterior chamber intraocular lens for age-related cataract. *Cochrane Database of systematic Reviews*.
26. Khanna R., Pujari, S and Sangwan, V. (2011). Cataract surgery in developing countries. *Current opinion in Ophthalmology*. 22, 10-14.
27. Pershing S. and Kumar, A. (2011). Phacoemulsification versus extracapsular cataract extraction: where do we stand? *Current Opinion in Ophthalmology*. 22, 37-42.
28. Conrad-Hegerer I., Al Juburi, M., Schultz, T., Hengerer, F. H and Dick, H. B. (2013). Corneal endothelial cell loss and corneal thickness in conventional compared with femtosecond laser-assisted cataract surgery: three-month follow-up. *Journal of cataract and refractive surgery*. 39, 1307-1313.
29. Mencucci R., Ponchiotti, C., Virgili, G., Giansanti, F. and Menchini, U. (2006). Corneal endothelial damage after cataract surgery: Microincision versus standard technique. *Journal of cataract and refractive surgery* : 32, 1351-1354.
30. Mayer W. J., Klaproth, O. K., Hengerer, F. H. and Kohnen, T. (2014). Impact of crystalline lens opacification on effective phacoemulsification time in femtosecond laser-assisted cataract surgery. *American journal of ophthalmology*. 157, 426-432.
31. Roberts T. V., Lawless, M., Bali S. J., Hodge, C and Sutton, G. (2013). Surgical outcomes and safety of femtosecond laser cataract surgery: a prospective study of 1500 consecutive cases. *120*, 227-233.
32. Moshirfar M., Churgin D. S. and Hsu, M. (2011). Femtosecond laser-assisted cataract surgery: current review. *Middle East African Journal of Ophthalmology* 18, 285-291.

33. Kranitz K., Takacs, A., Mihaltz, K., Kovacs, I., Knorz, M.C. and Nagy, Z. Z. (2011). Femtosecond laser capsulotomy and manual continuous curvilinear capsulorrhexis parameters and their effects on intraocular lens centration. *Journal of Refractive Surgery*. 27,558-563.
34. Nagy Z. Z., Ecsedy, M., Kovacs, I., Takacs, A., Tatrai, E., Somfai, G.M. and Cabrera Debut. D. (2012). Macular morphology assessed by optical coherence tomography image segmentation after femtosecond laser-assisted and 252 standard cataract surgery. *Journal of cataract and Refractive Surgery* 38, 941-946.
35. Bali S. J., Hodge, C., Lawless, M., Roberts, T. V. and Sutton, G. (2012). Early experience with the femtosecond laser for cataract surgery. *Ophthalmology*. 119,891-899.
36. Donaldson KE, Braga-Mele R, Cabot F, Davidson R, Dhaliwal DK, Hamilton R, Jackson M, Patterson L, Stonecipher K, Yoo SH, Subcommittee AR. Femtosecond laser-assisted cataract surgery. *Journal of Cataract & Refractive Surgery*. 2013 Nov 1;39(11):1753-63.
37. Filkorn T, Kovacs I, Takacs A, Horvath E, Knorz MC, Nagy ZZ. Comparison of IOL power calculation and refractive outcome after laser refractive cataract surgery with a femtosecond laser versus conventional phacoemulsification. *Journal of refractive surgery*. 2012 Aug 1;28(8):540-4.
38. Uy HS, Hill W, Edwards K(2011). Refractive results after laser anterior capsulotomy. *Investigative Ophthalmology and Visual science*. 52,E-Abstract 5695.
39. Apple D.J. and Sims, J. (1996). Harold Ridley and the Invention of the intraocular lens. *Survey of Ophthalmology*. 40,279-292.
40. Jaffe N. S. (1996). History of cataract surgery. *Ophthalmology*. 103, S5-S16.
41. Bhartiya S., Sethi, S. Bhargava, S. and Lakhota S. (2009). History of intraocular lenses: Triumphs and Tribulations. *Delhi Journal of Ophthalmology*. 20,71-76.