

## Case Report:

# Anterior Aesthetic Rehabilitation Of A Patient With Hypoplastic Maxillary And Mandibular Anterior Teeth- A Case Report

DR VISHWAS KHARSAN , \*DR VAIBAV BANDGAR

Associate Professor, Department of Prosthodontics, Nair Hospital Dental College, Mumbai

Assistant Professor, Department of Prosthodontics, Government Dental College, Mumbai.

Corresponding author\*

## ABSTRACT:

Dental enamel defects have been associated with a broad spectrum of aetiologies, including genetic and epigenetic factors such as systemic, local and environmental factors. The consequence of disturbances in the formation of the organic enamel matrix is termed as enamel hypoplasia, which can be characterized as small grooves, depressions and cracks in the enamel surface that can be viewed in mild cases. The aesthetic treatment of hypoplastic anterior teeth represents a challenge to dentists, because the restorative materials ideally should match the natural teeth. The optical behaviour of the final restoration is determined by the color of the underlying tooth structure, the color of the luting agent, and the thickness and opacity of the ceramic material used. This article presents a simple and conservative technique for restoring disfiguring areas of enamel hypoplasia to achieve an optimally aesthetic result.

## INTRODUCTION:

Enamel hypoplasia is a sequel to disturbances that occur during enamel matrix formation. The quality and quantity of enamel may be affected by any disturbance during its formation which in turn depends upon the phase of enamel formation that has been affected and the duration for which stimulus was subjected to ameloblasts. The characteristics of enamel hypoplasia may be depressions, grooves and surface cracks in the enamel<sup>1</sup>. In dentistry, the concept of aesthetics is extremely subjective and is related to beauty, harmony and needs of the patient. The interactions between new restorative materials and techniques allow the reproduction of dental structures, restoring form and function in such a way that restorative procedures become imperceptible<sup>2</sup>. The reproduction of the optical characteristics of the teeth, such as translucency, opalescence and fluorescence, requires a considerable knowledge of restorative techniques and the materials currently available<sup>3,4</sup>. With the evolution of restorative materials and techniques, the restorative treatment for anterior teeth has achieved a better aesthetic prognosis and adequate longevity<sup>5</sup>. This article presents a case report of a restorative treatment of hypoplastic anterior teeth, demonstrating use of all ceramic crowns on maxillary anterior teeth and composite resin on mandibular anterior teeth to mask color alteration and enamel defects to rehabilitate a smile.

## CASE REPORT:

A 28 year old male patient reported with a chief complaint of unaesthetic appearance of his smile due to surface irregularity in maxillary anterior teeth (Fig. 1). History and clinical examination revealed an enamel defect with irregular surfaces on the maxillary central incisor (11,21) along with wearing off the tip the maxillary canines (13,23) and spacing between 11,12,21,22. Worn out incisal thirds of mandibular anterior teeth (31,32,33,41,42,43). The degree of enamel hypoplasia was not so severe in the mandibular anterior as compared

to maxillary anterior teeth (Fig. 2). History of endodontic treatment with respect to 16,26,36,46 few months back. Patient's dental as well as medical history was otherwise insignificant. The clinical status of tooth revealed it to be enamel hypoplasia.

Patient's oral hygiene and periodontal condition was good. After discussing all the available treatment options including the differences in costs, amount of tooth structure removal, expected clinical longevity, time period necessary to conclude the treatment, and the possible aesthetic result. The proposed treatment plan was to fabricate porcelain fused to metal crowns with respect to 16,26,36,46 along with direct composite restoration using hybrid and microfilled composites, along with a contemporary enamel/ dentin adhesive system with respect to 31,32,33,41,42,43 and esthetic rehabilitation with all ceramic crowns on 11,12,13,21,22,23.

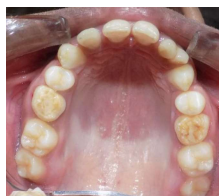

Fig.1

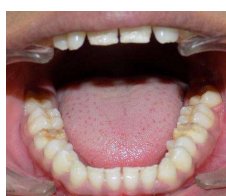

Fig.2

**Pre-treatment maxillary occlusal view**

**Pre-treatment mandibular occlusal view**

Complete arch impression was made with irreversible hydrocolloid to make maxillary and mandibular casts, using Type III dental stone) Diagnostic casts were mounted in centric relation on a semi-adjustable articulator using face-bow transfer and an inter-occlusal record. A diagnostic wax-up was done to achieve the patient's treatment goals (Fig.3). After evaluating the diagnostic wax-up in the patient's mouth, any necessary changes were made and patients approval and consent was taken before any treatment procedure was performed intraorally. Patient's participation in any decision making step is valuable. A diagnostic template was created on the basis of the wax-up, served as a guide for preparation of the teeth as well as fabrication of temporary restoration. Tooth preparation was done with respect to 16,26,36,46.

Gingival retraction was done to accurately record finish lines in the definitive impressions. Prepared teeth were temporized. Final impressions were poured and final casts were fabricated, the maxilla-mandibular relationship record was made, maxillary and mandibular casts were mounted on a semi-adjustable articulator. A trial evaluation of the metal substructure and shade selection was done followed by porcelain bisque trial in the next sitting. Any necessary occlusal adjustments were made with respect to porcelain fused to metal crowns (16,26,36,46) prior to glazing of the ceramic material. The crowns were cemented using glass ionomer luting cement. (Fig. 4 and Fig.5)

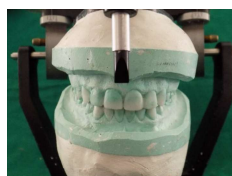


Fig.3- Diagnostic wax-up done

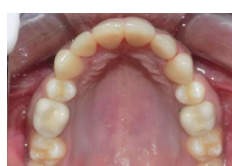

Fig.4- Final cementation with respect to 16,26

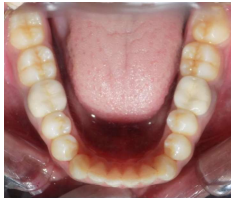

Fig.5- Final cementation with respect to 36,46

Slight enameloplasty was performed on mandibular anterior teeth to ensure a better substrate for adhesive bonding. Direct composite restorative procedure was carried out in the mandibular anterior region with respect to 31,32,33,41,42,43. The steps involved were acid etching using 35% phosphoric acid, rinsing for 30 s and drying with absorbent paper. A two-component adhesive system was applied on the dentin and the enamel and was light-cured. A combination of the incremental and stratified layering technique was used to restore the teeth using an aesthetic composite resin. The composite was added in increments of 1-1.5mm and was light-cured according to the manufacturer's instructions. The contouring was refined and the final polishing was performed with a high-luster polishing paste.(Fig 6)

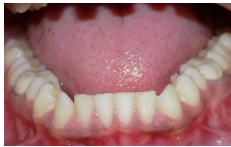

Fig.6 – Direct composite buildup done on mandibular anteriors 31,32,33,4,42,43.

Maxillary anteriors (11,21,12,22,13,23) tooth preparation was done to receive all ceramic crowns. The general tooth preparation guidelines, 1.5-2 mm incisal reduction, 1.0-1.5 mm lingual reduction, 1.0-1.5 mm labial reduction with a deep chamfer finish line, an indiscernible equigingivalmargin and rounded line angles were followed. Gingival retraction was performed (Fig.7) and complete arch definitive impressions were made with vinyl polysiloxane. Shade selection was done and approval was taken from the patient regarding the desired shade. Provisionals were trimmed and polished and cemented with a non-eugenol-containing temporary cement. CAD-CAM technology was used for fabrication of the prosthesis. PMMA crowns try in was done. (Fig.8)

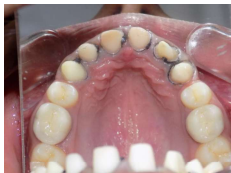

Fig.7- Tooth preparation done 11,12,13,21,22,23 to receive all ceramic crowns.

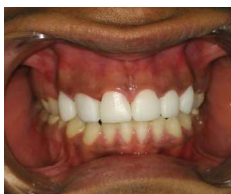

Fig.8- PMMA try in done

Before the technician glazed the restorations, they were tried in the mouth in a bisque bake stage to assess the final aesthetic appearance of the crowns. Any necessary modifications were done and if any changes required were conveyed to the technician. The crowns were received back from the technician with an untreated internal surface. This avoids the concern of decontaminating the etched internal surface of the crown after the crowns have been tried in. The fit was assessed and verified and the aesthetic appearance was approved by the patient. Etching of the internal porcelain surface (hydrofluoric acid) was carried out by the dentist in the dental surgery

after try-in to ensure a pristine, uncontaminated, etched surface before bonding. A thin layer of silane was applied on the internal surface of crown and dried thoroughly. A thin layer of bonding agent was applied on the internal surface but not cured.

The prepared tooth surface was etched and a thin layer of bonding agent was applied to the tooth surface. The resin cement was placed on the internal surface of the crown. The crown was fully seated with a slow, gentle, wiggling motion to allow excess thixotropic composite to gradually be extruded. Excess composite was cleaned off with a probe and micro brush. Once all excess has been removed the composite resin was cured.

Final polishing of the margin is carried out with a rubber cup wheel and diamond polishing paste. (Fig.9)

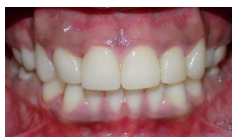

Fig.9-Final cementation all ceramic crowns 11,12,13,21,22,23

## DISCUSSION:

Enamel hypoplasia is an incomplete or defective formation in the organic matrix of the enamel. Irregularities present in a hypoplasia provide favourable conditions for the retention of plaque and the early development of caries lesions. One of the signs of hypoplastic lesions is diminishing enamel lustre and dental surfaces that have become eroded with cavitation and irregular wear because of the loss of the microanatomy affecting the color, morphology and texture of teeth <sup>6</sup>.

Several treatment modalities are available according to severity of lesion. Different available approaches are micro abrasion, tooth whitening and aesthetic restorations. Clinical studies have confirmed good performance of porcelain veneer restorations, with excellent aesthetics, overall patient satisfaction, and no adverse effects on the periodontal tissues <sup>7,8</sup>.

The association of hybrid and microfilled composite is a good alternative for the rehabilitation of anterior teeth affected by enamel hypoplasia, with desirable aesthetics and functional results. Composite resin restorations are fully capable of reproducing the appearance of a natural tooth with highly aesthetic outcomes in areas that are minimally affected <sup>9</sup>.

Porcelain laminate veneer restorations have certain disadvantages, such as marginal adaptation and bonding problems <sup>12</sup>.

Use of all-ceramic crowns in combination with resin cements has the potential to provide a more aesthetic solution than conventional ceramo-metal crowns. In fact, the concept of a silica/ glass based dentine bonded crown has been discussed by Burke et al. as arguably an ideal restoration <sup>10,11</sup>.

## REFERENCES:

1. Aesthetic management of enamel hypoplasia in maxillary lateral incisor with prefabricated composite veneer Neelam Mittal<sup>1</sup>, Vijay Parashar<sup>2</sup>
2. Baratieri LN, Araujo E, Monteiro S., Jr Color in natural teeth and direct resin composite restorations: Essential aspects. *Eur J Esthet Dent.* 2007;2:172–86.

3. Villarroel M, Fahl N, De Sousa AM, De Oliveira OB., Jr Direct esthetic restorations based on translucency and opacity of composite resins. *J Esthet Rest Dent.* 2011;23:73–87.
4. Heller A. Clinical procedures to avoid the ‘dark halo’ in restorations with direct composite resins. (309-10, 312). *Dent Update.* 2011;38:304–6
5. Esthetic Rehabilitation of Anterior Teeth Affected by Enamel Hypoplasia: A Case Report CARLOS JOSE SOARES, DDS, MS\*
6. Björndal L, Thyslstrup A. A structural analysis of approximal enamel caries lesions and subjacent dentin reactions. *Eur J Oral Sci.* 1995;103:25–31. [[PubMed](#)]
7. Peumans M, Van Meerbeek B, Lambrechts P, Vanherle G. The 5-year clinical performance of direct composite additions to correct tooth form and position. II. Marginal qualities. *Clin Oral Investig*1997;1:19–26
8. Peumans M, Van Meerbeek B, Lambrechts P, Vanherle G. Porcelain veneers: A review of the literature. *J Dent*2000;28:163–77.
9. Pontons-Melo JC, Furuse AY, Mondelli J. A direct composite resin stratification technique for restoration of the smile. *Quintessence Int.* 2011;42:205–11.
10. Burke F J, Qualtrough A J, Hale R W. The dentinebonded ceramic crown: an ideal restoration? *Br Dent J* 1995; 179: 58-63. 8.
11. Burke F J. Four year performance of dentinebonded all-ceramic crowns. *Br Dent J* 2007; 202: 269-273.
12. . Karlsson S, Landahl I, Stegersjo G, Milleding P. A clinical evaluation of ceramic laminate veneers. *Int J Prosthodont*1992;5:447-51.