

Original article:

A cadaveric study on the variation of branching pattern of femoral artery

Dr Banani Kundu, Dr Nabanita Chakraborty, Dr Soham Chakraborty, DrAlpana De

Name of the Institute/college: Department of Anatomy, R G Kar Medical College & Hospitals , Kolkata 700 004

Corresponding author: Dr Banani Kundu

Abstract:

Introduction- The largest deep branch of the femoral artery is the profundafemoris artery which provides the principal supply to all the extensor, adductor and flexor muscles of the thigh. Most commonly it takes origin from the postero-lateral side of the femoral artery about 3.5-5 cm below the mid-inguinal point. The study on the variation of the femoral artery and its branches has been a topic of great interest among the because of its major role in the clinical as well as radiological interventions.

Materials and Methods- In the present study, twenty-three (46 limbs) formaldehyde embalmed cadavers were dissected and studied. during the educational dissection in the Department of Anatomy, R. G. Kar Medical College.

Results- In this cadaveric study among 46 limbs 1) In one case we observed high up origin of the profundafemoris artery. 2) In another case the profundafemoris artery was arising from medial aspect of the femoral artery and then coursing superficial to femoral vein. The medial circumflex femoral artery took origin from the arteriaprofundafemoris but the lateral circumflex femoral artery was arising directly from the lateral side of the femoral artery. 3) Deep external pudendal artery took origin from arteriaprofundafemoris instead of femoral artery.

Conclusion- The knowledge of the variations regarding the site of the origin and course of profundafemoris artery and its circumflex branches has a great clinical importance during diagnostic imaging procedures as well as during surgeries that are performed in the femoral triangle. Hence, this present cadaveric study was done to estimate the incidence of origin of the profundafemoris artery along with its circumflex branches.

Keywords: Femoral artery, Profundafemoris artery, Medial and Lateral circumflex arteries

Introduction:

The External iliac artery continues as the femoral artery in the lower limb and enters the femoral triangle passing behind the inguinal ligament midway between the anterior superior iliac spine and the symphysis pubis¹. It gives three superficial branches -superficial epigastric artery, superficial circumflex iliac artery and superficial external pudendal artery. The femoral artery also gives off several deep branches in the upper part of the thigh including the deep external pudendal and profundafemoris arteries. The profundafemoris artery is a largest branch that arises laterally from the femoral artery about 3.5 cm below the inguinal ligament and spirals medially behind the femoral vessels. The profundafemoris artery gives off the lateral and medial circumflex arteries in the femoral triangle arising from the lateral and medial side of profundafemoris artery. During rest of the course It provides three perforating and muscular branches. The lateral circumflex femoral artery passes laterally between the anterior and posterior divisions of femoral nerve and disappears from the femoral triangle beneath the sartorius and

rectus femoris muscle. The medial circumflex femoral artery winds round the medial side of femoral shaft and passes between psoas and pectineus muscles. The greater trochanter, vastuslateralis and the knee is supplied by the lateral circumflex femoral artery whereas the medial circumflex femoral artery supplies the fatty tissue in the acetabular fossa and to the adductor muscles.^{2,3} Several case reports on the branching pattern of the femoral artery has been reported, but the variation of the profundafemoris artery arising from the medial side of the femoral artery is rare in literature.

The study of the femoral artery and its branching pattern has been a topic of great interest among the anatomists, vascular surgeons, and the professionals who work with imaging. The femoral artery is easily accessible for catheterization. Thereby investigations of any arterial system in the body can easily be carried out using this artery. The profundafemoris artery is also considered for various procedures like arteriography, ultrasound, Doppler imaging and magnetic resonance imaging and digital subtraction angiography.⁴ Because of the close relationship of profundafemoris artery with femur and hip bone there may be chances of development of aneurysm after penetrating injury, internal and external fixation of hip bone and during catheterization. So accurate anatomical knowledge about them is necessary to avoid various serious complications like haemorrhage, thrombosis, pseudo aneurysm etc.

Aims and Objectives:

The origin, course, termination and branching pattern of the major arteries of inferior extremity were studied in this cadaveric study to increase our knowledge regarding the possible variations which may be helpful not only to the clinicians but also to the radiologists.

Materials and methods :

During routine dissection of the inferior extremities in the department of Anatomy, R. G. Kar. Medical College twenty-three (46 limbs) formalin fixed cadavers were dissected during the period of three years. The femoral triangle was dissected meticulously, femoral sheath was identified and the femoral artery with all its branches including superficial and deep were exposed. The femoral artery, profundafemoris artery along with its medial and lateral branches were identified and its origin and course were studied. The origin of the profundafemoris artery from the mid-inguinal point was measured with a scale and a caliper in centimeters and noted for the study.

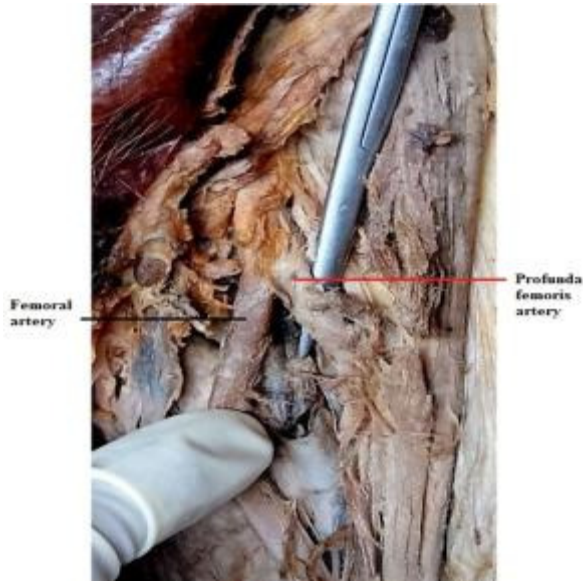
Observation and results:

Among all the lower limbs dissected we noticed higher origin of the profundafemoris artery in 4 limbs (1.84%).

This anatomical variations can be explained embryologically. In the lower animals, the profundafemoris artery arises from the external iliac artery. During course of evolution, the origin is shifted distally from the femoral artery. We know that Ontogeny repeats phylogeny. Hence, the developmental arrest at any stage may lead to anatomical variations related to the origin of the profundafemoris artery.⁷

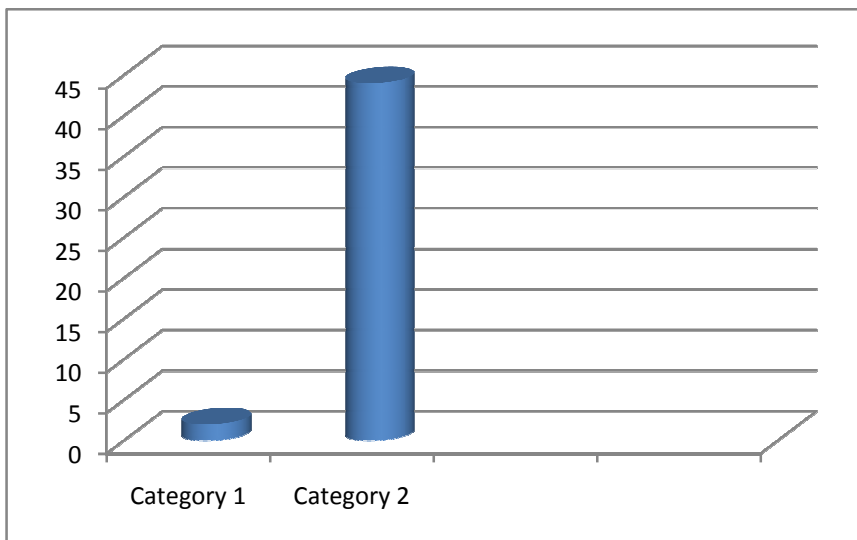
Table.1

Distance in cm from inguinal ligament	No of cases
<3cm	4
>3cm	42

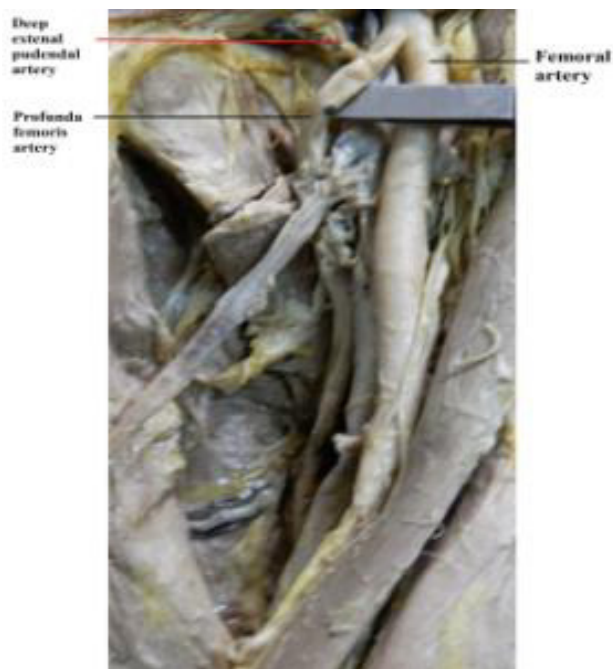


Picture 1: Showing high up origin of ProfundaFemoris Artery

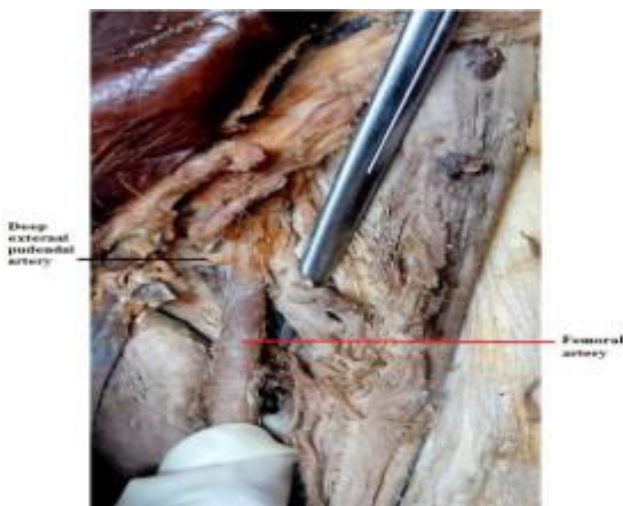
In 2 cases we observed that the deep external pudendal artery took origin from the profundafemoris artery instead of the femoral artery (0.92%).



Bar diagram showing variation of origin of the deep external pudendal artery



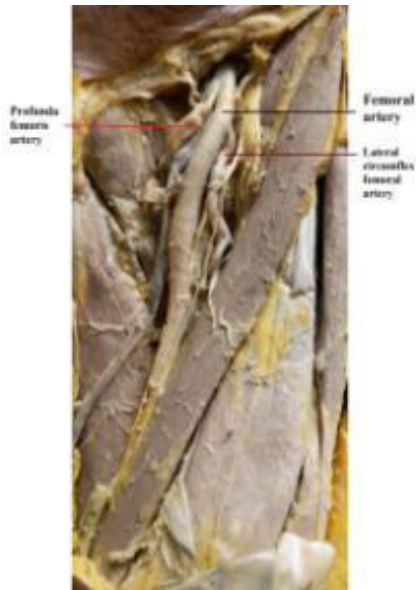
Picture 2 : Showing anomalous origin of Deep external Pudendal Artery from Profunda Femoris artery



Picture 3 : Showing normal origin of Deep external Pudendal Artery from Femoral artery

Only in one case the profundafemoris artery in the left limb was seen to take its origin from the medial aspect of the femoral artery (0.46%); while deep external pudendal artery was arising from arteriaprofundafemoris instead of the femoral artery. The lateral circumflex femoral artery was arising directly from the lateral side of the femoral artery; which was also giving muscular branches to the vastuslateralis and continued below to take part in genicular anastomosis. The medial lcircumflex femoral

artery was arising from the arteriaprofundafemoris. After its origin, the artery took its normal course and passed between the pectineus and psoas major muscle and eventually divided into its three terminal branches.



Picture 4: Showing variation of branches of Profunda Femoris Artery

Discussion:

Normal anatomy explains that the femoral artery which is the continuation of the external iliac artery gives off superficial and deep branches among which the profundafemoris is the largest. It gives two circumflex and four perforating branches. According to Bergman et al “the femoral artery may give rise to the inferior epigastric artery, deep circumflex iliac, lateral femoral circumflex, medial femoral circumflex, iliolumbar, accessory femoral circumflex (medial and lateral), descending branch of the lateral femoral circumflex and fourth or lowest perforating artery (general femoral nutrient or arteriafemoris magna)”.⁵ Anatomical variations reported at the level of the division of the femoral artery can be explained embryologically.

In the lower animals, the profundafemoris artery is a branch of the internal iliac artery. During course of evolution, the origin was shifted distally from the internal iliac artery. So the developmental arrest at different stages may cause various anatomical variations related to the division of the femoral artery.

In the present cadaveric study, in one case the profundafemoris artery was arising from the medial aspect of the femoral artery. Literatures say that when the origin of profundafemoris is high, it will emerge from the lateral side of the femoral artery. But in our study, did not support this view.. Additionally, arteriaprofundafemoris was coursing superficial to the femoral vein. Bergman et al. reported a case where the deep femoral artery passing in front of femoral vein.⁶ But it was rare according to him. And this theory was also supported previously by Johnston⁷ and Lipshutz⁸

The Medial circumflex femoral artery, which was arising from the arteriaprofundafemoris, is an important artery as it supplied blood to the head and neck of the femur, to the adductor muscles and to the fatty tissues in the acetabular fossa.⁹ Because of its close relationship with this area the artery is highly vulnerable to injury after trauma or during operations such as total hip arthroplasty.^{10, 11, 12} This study also showed that the lateral circumflex femoral artery was arising directly from the lateral side of the femoral artery instead of profundafemoris artery. This artery gave off ascending and descending branches. This ascending branch may be used during vascularized iliac transplantation.¹³

These anatomical variations reported may be due to the developmental arrest at different stages of the arterial network formation of the lower limb in the embryo.¹⁴ Very early in the developmental process, the anastomosis could be found between the dorsal sciatic artery and ventral femoral artery. Later capillary plexus in front of the pelvis and thigh formed complex vascular networks, named rete pelvicum and rete femorale. It was generally accepted that pattern of blood-flow determined the final mature arterial pattern. Thus the most appropriate channels enlarged while others contracted and disappeared; thereby establishing the final arterial ramification.¹⁵

Conclusion:

The existence of embryological variations of the arteries of the lower limb often results from unexpected developmental arrests of the embryological arterial network. So these variations are having practical importance for the radiologists, cardiologists, orthopedic and vascular surgeons.

Acknowledgement: The authors express their heartfelt gratitude to all the members of the Department of Anatomy, R G Kar Medical College, Kolkata for their kind cooperation and generosity in the conduct of the study.

References:

1. Susan Standring, Gray's Anatomy; The Anatomical Basis of Clinical practice, 40th edition, Elsevier Churchill Livingstone; 2005
2. Uzel M, Tanyeli E, Yildirim M. Anatomical study of the origin of the lateral circumflex femoral artery in the Turkish population; *Folia Morphol*, 2008, 64(4): 226-30
3. Tanyeli E, Uzel M, Yildirim M, Celik HH. An anatomical study of the origins of the medial circumflex femoral artery in the Turkish population, *Folia Morphol (warsz)*, 2006, 65(3): 209-12.
4. Dixit DP, Mehta LA, Kothari ML. Variation in the origin and course of profundafemoris, *J Anat. Soc, India*, 2001, 50(1) 6-7.
5. Compendium of human anatomic variation. Ronald A bergman, pg.86.
6. Bergman RA, Afifi AK, Miyauchi R (2001) Illustrated encyclopedia of human anatomic variation. Part II: Cardiovascular system: arteries: lower limb, femoral artery ([http://www. anatomyatlases.org/](http://www.anatomyatlases.org/)).
7. Johnston TB (1912) A rare anomaly of the arteriaprofundafemoris. *AnatAnz*, 42: 269-272
8. Lipshutz BB (1916) Study on the blood vascular tree. A composite study of the femoral artery. *Anat Rec*, 10:361-370.

9. Williams PL, Warwick R, Dyson M, Bannister LH. Gray's anatomy, 37th ed. Churchill &Livingston, London, 1989, pp. 781-783.
- 10.Langer R, Langer M, Scholz A, Astinet F, SchwetlickG, Felix R, Femoral head perfusion in patients with femoral neck fracture and femoral head necrosis, J BelgeRad, 1993, 76: 145-149.
- 11.Nachbur B, Meyer RP, Verkkala K, ZurcherR, The mechanisms of severe arterial injury in surgery of the hip joint. ClinOrthopRelat Res, 1979, 141: 122-133.
- 12.Pai VS, Compartment syndrome of the buttock following a total hip arthroplasty. J Artroplast, 1996, 11: 609- 610.
- 13.Siddharth P, Smith NL, Mason RA, Giron F, Variational anatomy of the Deep femoral artery, Ant Rec, 1985, 212: 206-209.
- 14.Sanudo JR, RoigM, Rodriguez A, Ferreira B, Domnech JM. Rare origin of the obturator, inferiorepigastric and medial circumflex femoral arteries from a common trunk, JAnat, 1993, 183(1): 161-163
- 15.BunyaminSahin, AhmetUzun, MehmetEmirzeoglu, RenginKosif, SaitBilgic. A deep femoral artery passing in front of the femoral vein,FoliaMorphol, 2003, 62(2): 143-146..