

**Original article:**

## **Study of functional outcome of treatment of intraarticular proximal tibia fractures**

**<sup>1</sup>Dr.Kusumchandra Ambhure , <sup>2</sup>Dr Swapnil Sonar \***

<sup>1</sup>Associate Professor, Department of Orthopedics, SMBT Institute of Medical Sciences, Nandi Hills, Igatpuri, Nashik.

<sup>2</sup>Resident, Department of Orthopedics, SMBT Institute of Medical Sciences , Nandi Hills , Igatpuri, Nashik

Corresponding author\*

### **Abstract:**

**Introduction:** Extraarticular fractures of proximal tibia occur only in 5% to 11% of all tibial shaft fractures. As they often are the consequence of high energy transfer, a highly unstable situation with bone fragmentation and extensive soft tissue damage may result

**Material and methods:** It is a prospective study. 50 cases of proximal tibia fractures including both intraarticular and extraarticular fractures were included in the study. Cases treated in our Tertiary Healthcare Institute for two years duration. were included in the study. Criterion for selection was radiologically demonstrable fracture of proximal tibia and satisfaction of inclusion criterion.

**Results:** Extraarticular proximal tibial fractures with fracture site > 5 cm from articular surface, stable, minimally displaced fractures were treated with intramedullary interlocked nailing. A high bend nail was used with a lateral entry and a blocking screw / K wire.

**Conclusion:** In our study of proximal tibia fractures, incidence of Intra-articular fracture was **54%** while that of Extra-articular fracture was **46%**.

### **Introduction:**

Extraarticular fractures of proximal tibia occur only in 5% to 11% of all tibial shaft fractures. As they often are the consequence of high energy transfer, a highly unstable situation with bone fragmentation and extensive soft tissue damage may result.<sup>1</sup>Treatment of these injuries is challenging and is associated with higher rates of complications than diaphyseal tibia fractures.<sup>2</sup>

The goals of surgical management include correction and maintenance of sagittal and coronal alignment, restoration of length and rotation, and early functional knee and ankle range of motion. Treatment options include medullary implants, half pin external fixation, hybrid or thin wire external fixations, plate fixations, or combination techniques.<sup>3</sup>

Recent design changes to intramedullary nails (IMNs) and adjunctive fixation techniques have definitely increased the popularity of IMN for the treatment of this fracture. Similarly the development of percutaneous biological plating has allowed surgeons to treat these complex fractures without the need for large incisions or fear of soft tissue stripping with subsequent failure due to infection and nonunion.<sup>5</sup> In most instances, intramedullary nailing has

become the method of choice for the fixation of diaphyseal tibial fractures and has been extended to the treatment of proximal fractures. Reports have show a high incidence of malalignment and loss of fixation associated with intramedullary nailing of proximal metaphyseal fractures.<sup>5</sup> Minimally invasive plate osteosynthesis techniques have recently been applied to fractures of proximal and distal tibia. Recently, the use of plate fixation utilizing minimally invasive techniques has been put forward as one way maintaining alignment in proximal tibial fractures.<sup>3</sup> The purpose of this study is to study the available modalities of treatment of proximal tibia fracture in this institute and observe their functional result.

**Methodology:**

It is a prospective study. 50 cases of proximal tibia fractures including both intraarticular and extraarticular fractures were included in the study. Cases treated in our Tertiary Healthcare Institute for two years duration. were included in the study. Criterion for selection was radiologically demonstrable fracture of proximal tibia and satisfaction of inclusion criterion.

**INCLUSION CRITERION:**

- 1) Patients of age group 18 to 65 years of both sexes with fracture of proximal tibia.

**EXCLUSION CRITERION:**

- 1) Children with less than 18 years of age.
- 2) Pathological fracture.
- 3) Associated neurovascular injuries.
- 4) Compound fractures.
- 5) Ipsilateral lower femur or lower tibia fracture.
- 6) Closed fractures with significant soft tissue trauma.( AO types IC 3,4,5, MT 3,4,5, NV 2,3,4,5)

Intraarticular fractures were classified using Schatzkers classification and extraarticular fractures were classified using AO classification.

All the clinical details of patient selected for study were noted in a proforma prepared for the study.

Functional outcome was evaluated by **MODIFIED HOHL M. AND LUCK**

**Results:**

**A) Intra articular fracture:**

1) Outcome

| Functional Outcome | CR CAST | CRCC | ORIF BP | ORIF BP+BG |
|--------------------|---------|------|---------|------------|
| Excellent          | 1       | 5    | 4       | 3          |
| Good               | 2       | 3    | 2       | 1          |
| Fair               | 2       | 1    | 2       |            |
| Poor               |         |      | 1       |            |

Table 1 : Functional Outcome (Intra-articular fracture)

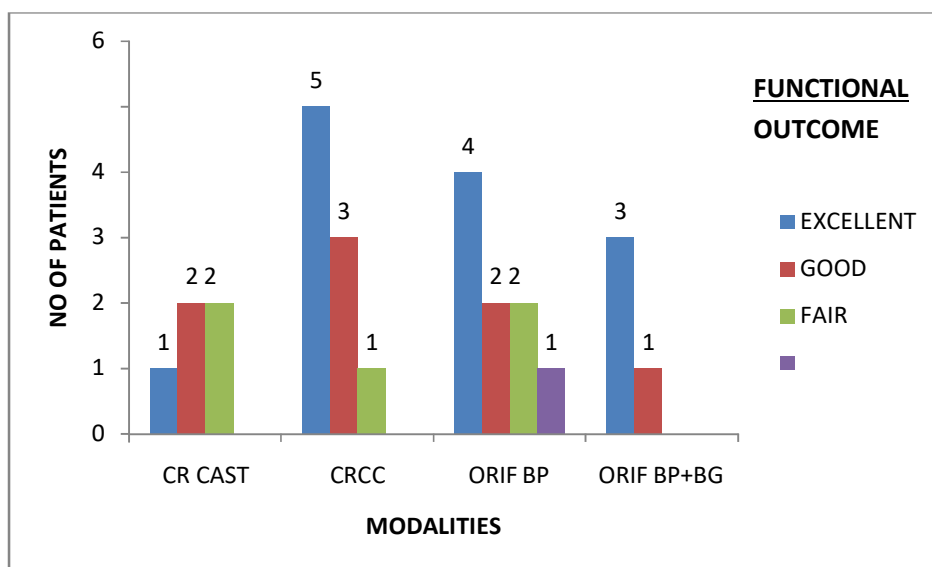


Chart 1: Functional Outcome (Intra-articular fracture)

2) Classification of outcome

| Modality     | CR CAST | CRCC   | ORIF BP ± BG |
|--------------|---------|--------|--------------|
| Acceptable   | 60%     | 88.88% | 76.92%       |
| Unacceptable | 40%     | 11.12% | 23.08%       |

Table 2: Pooled Functional Outcome (Intra-articular)

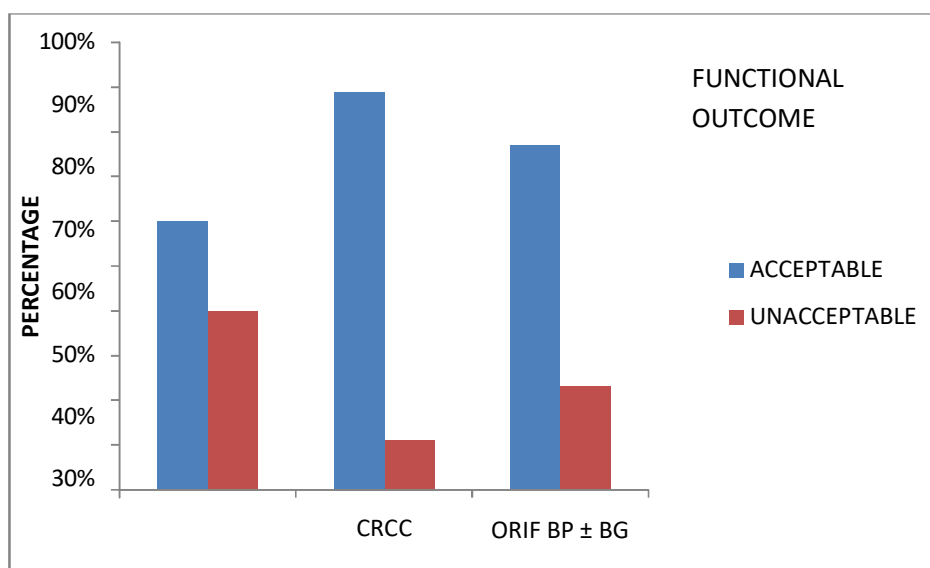


Chart 2: Pooled Functional Outcome (Intra-articular)

**Discussion:**

Fixation with interlocking nail is a modality used only in Extra-articular proximal tibial fractures. Efficiency of interlocking nail in proximal tibial fractures depends on its proper placement in the medullary cavity. Major factors affecting its placement are;

- 1) Lateral situation of medullary cavity in proximal tibia.
- 2) Constant muscular deforming forces which tend to keep proximal fragment into valgus angulation.
- 3) Skills to maintain the properly aligned medullary cavity throughout the operative procedure until interlocking is done.

These are counter acted by :

A lateral entry point in line with the medullary cavity.

Reduction done and held by clamps, and a blocking screw is passed so that an anatomically correct path is made by the reamers for the nail<sup>4,5</sup>

Nail is passed with utmost care to hold the reduction.

Blocking screw is removed **only after** interlocking.

**Advantages :**

- 1) Closed minimally invasive procedure
- 2) Avoidance of soft tissue stripping, periosteum and fracture hematoma damage, hence maintain proper fracture healing environment.
- 3) Load bearing, rotationally stable intramedullary implant increases efficiency of the construct.
- 4) Reaming acts as internal bone grafting procedure, hence hastens healing.
- 5) Fewer incidences of infections.
- 6) Immediate and adequate physiotherapy can be given.

**Disadvantages:**

- 1) Difficult technique in view of constant deforming forces and the necessity to hold the reduction throughout the procedure.
- 2) Higher incidences of deformities due to loss of reduction and malunion.
- 3) In a setting of infection, higher chances of transdiaphyseal spread as implant is intramedullary and all along the length.

Extraarticular proximal tibial fractures with fracture site > 5 cm from articular surface, stable, minimally displaced fractures were treated with intramedullary interlocked nailing. A high bend nail was used with a lateral entry and a blocking screw / K wire.

**Conclusion:**

Functional outcome for CR CAST is highly unsatisfactory with high unacceptability rate, even when used only for undisplaced and stable fracture types.

**References:**

- 1) Cambells operative orthopaedics; Fractures of lower extremity: Tibial plateau 2094- 2111 Vol 3.
- 2) ROCKWOOD AND GREENS FRACTURE IN ADULTS, seventh edition, volume 3 tibia and fibula fractures by Brad Petrisor, Mohit Bhandari and Emil Schemitsch page no 1867-1923.
- 3) Lindvall , Eric; Sanders, Roy; DiPasquale, et al. Intramedullary nailing versus Percutaneous Locked Plating of extraarticular proximal tibial fractures : Comparison of 56 Cases. J Orthop Trauma. 2009;23:485-492.
- 4) Laflamme GY, HeimlichD, Stephen D, et al. Proximal tibial fracture stability with intramedullary nail fixation using oblique interlocking screws.J OrthopTrauma.2003;17:496-502.
- 5) Nork SE, Barei DP, Schildhauer TA, et al. Intramedullary nailing of proximal tibial fractures. J Orthop Trauma. 2006;20:523-528.
- 6) David Levay : History of Orthopaedics : 625,592,1990