

## Case report

# Primary renal hydatid cyst masquerading as matrix renal stones

<sup>1</sup>Dr Bawana Raina , <sup>2</sup>Dr Ajay Misri , <sup>3</sup>Dr Monal Trisal , <sup>4</sup> Dr Naveen Kumar

<sup>1</sup>Deptt of Pathology, Acharya Shri Chander College Of Medical Sciences, Sidhra, Jammu-180017

<sup>2</sup>Department of Surgery, Police Hospital Gandhi Nager, Jammu, 180004.

<sup>3</sup>Department of Pathology and Transfusion Medicine, Dharamshila Hospital And Research Centre , New Delhi- 110096

<sup>4</sup>Department of Medicine, Fortis Hospital Sector - 44, Opposite HUDA City Centre, Gurgaon, Haryana 122002

Corresponding author: Dr Monal Trisal

---

## Abstract

Human hydatidosis affects several organs in the body. Primary isolated kidney involvement is very rare. We present a case of incidentally discovered hydatid disease encountered during elective pyelolithotomy for renal matrix stones. It was managed by cyst enucleation without sacrificing the kidney, followed by a course of albendazole. The patient showed no evidence of recurrence till the end of one year follow up. The case emphasizes the need to keep a broad differential in such cases and to use of advanced imaging techniques to narrow them down, so that a more accurate decision about their management can be taken.

**Keywords** – Hydronephrosis, Hydatidosis, Hydatid cyst, Isolated renal hydatid.

---

## Background

Echinococcosis or hydatidosis is caused by the tapeworm, *Echinococcus granulosus*, which belongs to the order cestoda, family taenia. Its prevalence is highest in cattle and sheep raising regions of the world, such as the Middle East, Central Europe, Australia, Asia and South America. The disease affects mainly the gastrointestinal and pulmonary systems.<sup>1</sup> Most commonly affected organs are liver (75%) followed by lungs (15%), which act as filters for the worm.<sup>2,3</sup> Kidneys are uncommonly involved, usually along with other organs and comprises only 2-3% of all cases.<sup>2</sup> An isolated involvement of kidneys is even rarer. Here we report a case, which on the basis of history and investigation appeared to be soft matrix renal calculi, for which elective pyelolithotomy was planned. But to our surprise, it turned out to be an isolated renal hydatid cyst.

## Case Presentation

A 33 year old female presented with complaints of

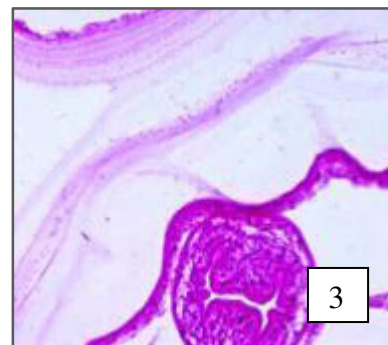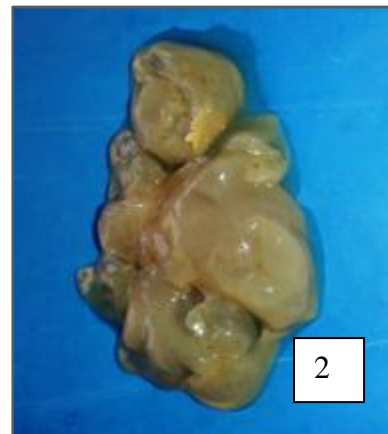
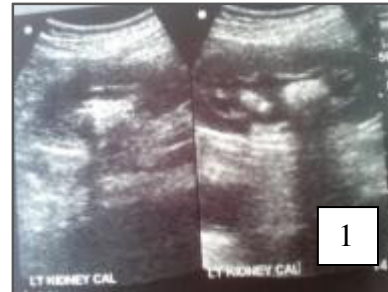recurrent left lumbar region pain for last six months, followed by dysuria for about four months. The pain was episodic, dull aching to colicky in nature, involving the renal angle, some time associated with vomiting. In last four months, she also had episodes of dysuria and fever, which were treated with a course of antibiotics. In physical examination, there was no tenderness in the left renal angle, left hypochondrium or lumbar region. Ultrasound (USG) of the whole abdomen revealed: multiple (6-7), soft, echogenic matrix calculi, with faint acoustic shadow in all calyceal groups of the left kidney, largest 26mm; left sided moderate hydronephrosis with echogenic debris within the hydronephrotic sac; cortico-medullary differentiation was maintained (figure -1). The rest of the abdominal ultrasound was normal. Intravenous urography (IVU) was done and which showed no excretion of contrast from the left kidney, delayed nephrogram at 6 hr with filling defects; finding was suggestive of left stag horn soft calculus with

pyonephrosis and suppressed function. Renal scan showed 30% split function of the left kidney. In routine investigations haemoglobin was 11.2 gm/dl, total leucocyte count was 10000/cc and differential leucocyte count was N-70/L-26/E-4/M-1. Liver and kidney function tests, serum electrolyte, random sugar, chest X ray were normal. Urine routine examination had 20-25 pus cells per high power field. We first treated the urinary tract infection. Then on the basis of matrix stones with hydronephrosis on USG, delayed nephrogram of left side on IVU and reduced but preserved left renal function on scan, we planned left pyelolithotomy. When pyelotomy was made, multiple cystic masses popped out, which raised the suspicion of renal hydatid disease. The lesion was excised and precautions were taken so that there was no spillage of cystic contents. In gross examination, cyst was 8.5 X 6.5 cm, single, multiloculated, grey white, fluid filled, appearing as bunch of grapes (figure-2). The microscopic examination revealed a lamellated fibrochitinous cyst wall which contained scolices and brood capsule (figure-3) and there were also areas of focal calcification of the wall. Patient was given a post-operative course of Albendazole with view to decrease the risk of recurrence. Her post operative stay was uneventful and patient was discharged on a regime of Albendazole: 3 cycles of 400mg given twice a day for 28 days with an interval of 14 days between cycles. The patient showed no evidence of recurrence at the end of 1 year follow up.

Figure 1: USG abdomen shows soft renal calculi with faint acoustic shadow.

Figure 2: Grey coloured multiloculated hydatid cyst removed from left kidney, appearing as bunch of grapes.

Figure 3: Shows lamellated fibrochitinous hydatid cyst wall (pericyst) and the inner endocyst with daughter cyst (H&E.40X).



### Discussion

Matrix calculi are an uncommon form of renal stones. They are composed of protein, sugars, glucosamines, and water. Being soft, they conform to the shape of

the ureter or calyx. The diagnosis is usually made at surgery, as it is very difficult to suspect them in radiographic investigations.<sup>4</sup>They are usually radiolucent non-opaque calculi and are difficult to diagnose on plain X-ray abdomen or IVU. In IVU they appear as radiolucent filling defect. Ultrasonography can identify them, but depending on the amount of mineralization, acoustic shadowing may or may not be present. CT can distinguish them from other causes of radiolucent filling defects in the collecting system. They are best treated by percutaneous or surgical extraction. As they are gelatinous in nature and lack a crystalline structure, extracorporeal shock wave lithotripsy (ESWL) is generally unsuccessful and not recommended. In our case also, the lesions were multiple, fitting into calyces, with faint acoustic shadowing thus suggesting matrix calculi. IVP also only showed reduced renal function with filling defects. As on renal scan, function of kidney was reduced but not absent, and we suspect matrix calculi, we planned pyelolithotomy and not ESWL or nephrectomy. But to our surprise, it turned out to be hydatid cyst. There was no sign of disease anywhere else in USG abdomen, and being a closed cyst, there was no hydatiduria in urine routine examination. Moreover, findings on USG were not typical of hydatid disease (unilocular or multilocular cystic mass with daughter cysts). Hence we didn't suspect it, and didn't go for CT abdomen. Similar to our case, Nandwani *et al*<sup>5</sup> also reported a case where they confused renal hydatid cyst with calculus and diagnosis was suspected only during planned percutaneous nephrolithotomy.

Echinococcosis is a zoonosis with worldwide prevalence, caused by the larval stage of the echinococcus tapeworm. The adult worm lives in the

proximal small intestines of the definitive host (usually a dog). They release eggs, which are excreted in the feces. Humans become accidental intermediate hosts either through contact with a definitive host, or ingestion of contaminated water or vegetable.<sup>3</sup>The larvae penetrate the intestines to enter the portal venous system and lymphatics; via them they travel to the liver which acts as the first line of defence. From there they can reach lungs which act as second site of filtration of the hydatid cyst. Hematogenous dissemination from these two primary locations can secondarily involve any organ in body.<sup>3</sup>

Kidney involvement is rare (2-3%) even in endemic area, as it has to cross above mentioned lines of defence of liver and lung.<sup>6</sup>It has been postulated that the cysts pass through portal system into the liver and finally via retroperitoneal lymphatics reach kidney.<sup>7</sup>They are most commonly solitary and located in renal cortex, generally in either of the poles.<sup>6</sup>The hydatid cyst of kidney can be of three types: closed, exposed and open. It is called closed type when all three layers of cyst are intact. When the cyst is no longer protected by the third layer (pericyst), it is called an exposed cyst. If all the three layers of the cyst have ruptured, and there is free communication with the drainage system of kidney, it is called an open or communicating cyst. Cystic rupture into the collecting system, leads to passage of daughter cysts into the urine, causing hydatiduria which is pathognomonic of renal hydatidosis. It is usually microscopic and is seen only in 10-20% of cases.<sup>7</sup>Gross hydatiduria is uncommon but diagnostic. The patient usually remains asymptomatic for years and later may present with the symptoms of hydatiduria, lumbar region pain, hematuria, pyuria or intermittent fever.<sup>2,3</sup>

Eosinophilia is a feature in about 25-50% cases.<sup>8</sup>

Serological tests in primary renal hydatidosis are usually negative; but it does not exclude hydatid disease. Positive serology neither confirms the diagnosis, nor correlate with pathological stage; it just have a supportive role and suggest further work-up.<sup>9</sup> Although not specific, radiological studies may provide clue for preoperative diagnosis. A high index of suspicion for hydatid disease should be maintained while evaluating complex cystic renal masses. On plain X ray abdomen, it can appear as soft tissue mass or ring shape calcification; 0.9% of calcified renal mass can have renal hydatidosis.<sup>9</sup> IVP reveals mostly distortion of calices, calical ectasia as a result of mass involving the collecting system or reduced function of kidney. Ultrasonography usually demonstrates unilocular or multilocular cyst. In 2003 WHO-IGWE classified the types of HC according to disease activity: pure cyst or those having dominant cystic components with hydatid sand (types 1 and 2 respectively) indicates active disease; cysts having detached membranes, daughter cysts or solid septations are the transitional or 'in process of dying' stage (type 3); and those having solid appearance (types 4 and 5) are suggestive of inactive disease.<sup>10</sup> CT scan is more sensitive and accurate than USG, and it has some important advantages: it can more easily detect calcification, daughter cysts, intracystic infection, communication with the urinary tract, extra renal disease and can more easily differentiate WHO stage 4 cyst from urinary tract tumor and abscess.<sup>9</sup>

Histopathologically there is an outer laminated non-nucleated layer made up of layers of gelatine. Outside this layer there is a pericyst which is formed as a result of inflammatory reaction of the host. Over a period of time it makes a dense fibrous capsule. There is an inner germinal layer gives rise to

daughter cysts. The cysts eventually become leaky, resulting in shrinkage, fibrosis and eventual calcification. The parasite structure are completely destroyed, with only degenerated scolices remaining intact along with yellow paste like cholesterol rich debris.<sup>11</sup>

As medical treatment is insufficient to cure and interventional radiology is quite risky, surgery is usually the treatment of choice in renal hydatid cyst. Kidney-sparing surgery is possible in 75% cases of intra pelvic renal hydatid; but nephrectomy may be needed in remaining 25% cases when it has been totally destroyed by the cyst.<sup>12,13,14</sup> Care should be taken to prevent spillage which can result in anaphylactic reaction and dissemination of disease. Pre-operative courses of albendazole is recommended for cyst sterilization, decreasing risk of anaphylaxis (as it become non-antigenic) and to reduce pressure within the cyst (thus reducing the risk of spillage). Post-operative course of up to 3 months is recommended to reduce the recurrence of disease, especially when cystic fluid has spread during surgery.<sup>15</sup> Albendazole with or without puncture aspiration-injection-re-aspiration (PAIR) is indicated in patients with WHO stage 1 hydatid cyst, cyst containing several daughter cyst, inoperable disease, patients who cannot tolerate surgery and who do not wish to undergo surgery.

#### **Learning Points**

1. Hydatid disease may present in unusual ways leading to diagnostic difficulty and management problems.
2. Isolated renal involvement caused by Hydatid cyst is a rare occurrence. A high index of suspicion for hydatid disease should be maintained while evaluating renal masses.

3. Preoperative diagnosis using advanced radiological technique is important, failing which there is risk of anaphylactic reactions during surgery and disease recurrence their after.

## References

1. Kouskos E, Chatziantoniou J, Chrissafis I, Anitsakis C, Zamtrakis S. The uncommon locations of hydatid cysts. *Singapore Med J* 2007;48(4):119-21.
2. Mongha R, Narayan S, Kundu AK. Primary hydatid cyst of the kidney and the ureter with gross hydatiduria: A case report and evaluation of the radiological features. *Indian J Urol* 2008;24:116-17.
3. Pedrosa I, Saiz A, Arrazola L, Ferreiros J, Pedrosa CS. Hydatid disease: radiologic and pathologic features and complications. *Radiographics* 2000;20:795-817.
4. Singh H, Pandey S, Dorairajan LN, Kumar S. Acute renal failure due to bilateral matrix renal calculi- a diagnostic dilemma. *Int Urol Nephrol* 2001; 33(2): 311-3.
5. Nandwani GM, Biyabani SR, Memon A. Incidental intrarenal-pelvic hydatid cyst discovered during percutaneous Nephrolithotomy (PCNL). *J Pak Med Assoc* 2004; 54(8): 436-8.
6. Volders WK, Gelin G, Stessens RC. Best Cases from the AFIP Hydatid Cyst of the Kidney: Radiologic-Pathologic Correlation. *Radiographics* 2001;21:8255-60.
7. Unsal A, Cimentepe E, Dilmen G, Yenidunya S, Saglam R. An unusual cause of renal colic: Hydatiduria. *Int J Urol* 2001; 8:319-21.
8. Afsar H, Yagci F, Meto S, Aybasti N. Hydatid disease of the kidney: evaluation and features of diagnostic procedures. *J Urol* 1994;151:567-70.
9. Gogus C, Safak M, Baltaci S, Turkolmez K. Isolated renal hydatidosis: experience with 20 cases. *J Urol* 2003;169:186-9.
10. WHO Informal Working Group. International classification of ultrasound images in cystic echinococcus for application in clinical and field epidemiological settings. *Acta Tropica* 2003;85:253-61.
11. Ramzi SC, Vinay K, Robbins SR. *Pathologic basis of disease*, 8<sup>th</sup> ed. Philadelphia: WB Saunders, 1989, pp.392-93.
12. EJ Khader K, Koutani A, EJ Mamoun M, Ibn Attya A, Hachimi M, Lakrissa A. Endoscopic percutaneous drainage of a renal echinococcal cyst during percutaneous nephrolithotomy. *Acta Urol Belg* 1998; 66:43-6.
13. Ishimitsu DN, Saouaf R, Kallman C, Balzer BL. Best cases from the AFIP: Renal hydatid disease. *Radiographics* 2010 Mar; 30(2):334-37.
14. Zmerli S, Ayed M, Horchani A, Chami I, EI Ouakdi M, Ben Slama MR. Hydatid cysts of the kidney: diagnosis and treatment. *World J Surg* 2001; 25(1):66-74.
15. Junghans T, da Silva AM, Horton J, Chiodini PL, Brunetti E. Clinical management of cystic echinococcosis: state of the art, problems, and perspectives. *Am J Trop Med Hyg* 2008;79: 301-11.