

Case series:

Presurgical Nasoalveolar Moulding: A Practical approach for improving surgical outcome in Cleft Lip and Palate patients

¹Dr Manthan Patel , ²Dr Shantanu Choudhari, ³Dr Chirag Vaghela , ⁴Dr Parikrama Solanki

¹Post Graduate, Dept. of Pedodontics and Preventive Dentistry, Govt. Dental College & Hospital, Ahmedabad

²Professor and Head, Dept. of Pedodontics and Preventive Dentistry, Govt. Dental College & Hospital, Ahmedabad

³Post Graduate, Dept. of Pedodontics and Preventive Dentistry, Govt. Dental College & Hospital, Ahmedabad

⁴Post Graduate, Dept. of Pedodontics and Preventive Dentistry, Govt. Dental College & Hospital, Ahmedabad

Corresponding author : Dr Shantanu Choudhari

Abstract:

Objective: The purpose of this article is to describe a treatment approach for presurgical nasoalveolar moulding in newborns with unilateral and bilateral cleft lip and palate.

Methods: Presurgical nasoalveolar moulding was done with a nasoalveolar moulding (NAM) appliance in a 9 day old boy with bilateral cleft lip and palate, and in a 17 day old boy, a 12 day old girl and a 9 day old girl with unilateral cleft lip and palate. The NAM appliance consists of lip taping, alveolar moulding with an intraoral moulding plate and nasal moulding with nasal stents.

Discussion: The shape of the cartilaginous septum, alar cartilage tip, angle between medial and lateral crus, columella length and alveolar segments can be molded to their normal anatomic position. The NAM appliance is easy to fabricate, practical to activate, and comfortable to wear and use.

Conclusion: PNAM effectively improves nasal symmetry in terms of nostril width, height and columella angle. Patients also benefit by a decrease in size of cleft, thereby facilitating lip repair, followed by palatal closure with minimal scar.

Introduction:

Presurgical infant orthopedics has been used in the treatment of cleft lip and palate patients since long. The early techniques involved elastic retraction of the protruding premaxilla followed by stabilization after surgical repair ⁽¹⁾. In 1689, Hoffmann demonstrated the use of facial binding to narrow the cleft and prevent postsurgical dehiscence ^(1,2). In 1844, Hullihen stressed the importance of presurgical preparation of clefts using an adhesive tape binding ^(1,3). In 1927, Brophy demonstrated the passing of a silver wire through both the ends of the cleft alveolus, and then progressively tightened the wire to approximate the ends of the alveolus before lip

repair ^(1,4). In 1975, Georgiade and Latham introduced a pin-retained active appliance to simultaneously retract the premaxilla and expand the posterior segments over a period of several days ^(1,5).

In 1993, Grayson *et al* ⁽⁶⁾, first described nasoalveolar moulding to presurgically mould the alveolus, lip and nose in infants born with cleft lip and palate. It consists of an intraoral moulding plate with nasal stents to mould the alveolar ridge and nasal cartilage at the same time. The objective of presurgical NAM is to reduce the severity of the original cleft deformity and thereby enable the surgeon to achieve better repair of the alveolus, lip and nose. This technique has also eliminated surgical columella

reconstruction and the resulting scar tissue in bilateral cleft lip and palate^(1, 7). It has also been shown to significantly improve the surgical outcome compared to other techniques of presurgical orthopedics^(1,8).

Long term studies on NAM therapy indicate 60 % reduction in the need for secondary alveolar bone grafting. With proper training and clinical skills NAM has demonstrated tremendous benefit to the cleft patients as well as to the surgeon performing the repair⁽¹⁾.

Case report 1:

A family brought their 17-day-old male child with complete unilateral cleft lip and palate to the department of Pedodontics and Preventive Dentistry of our institute. He had no significant medical history, family history or associated systemic illness. He had a nasal deformity which included a depressed wide nostril on the cleft side, a small elevated nostril on the non-cleft side, with small columella stretched towards non-cleft side, deviated nasal tip towards cleft side and increased angle between lateral and medial crus cartilage of nostril on cleft side (Fig.1.1). There was an alveolar deformity which included segment displacement, with intraoral cleft gap of 6.5 mm. Greater segment was displaced outwards and lesser segment displaced inwards (Fig 1.2).

On the same day, primary impression was taken with elastomeric impression material and next day final impression with the same impression material with the help of custom tray. A nasoalveolar moulding plate was constructed with self-cure acrylic resin. The plate was inserted into the newborn's mouth when he was 20 days old. At 24th day, adding of soft acrylic resin and selective trimming of plate was started for alveolar moulding. The nasal stent was attached to the nasoalveolar moulding plate at the 30th day (Fig

1.3). Controlled movement of the alveolar segments was obtained by tight positioning of lip segments with a micropore tape combined with the plate.

The parents were instructed to keep the appliance in the child's mouth for full time. They were explained about removing, cleaning and applying the plate as well as micropore tapes. They were also explained about possible complications of nasoalveolar moulding, specially associated with excessive pressure of tapes and elastics.

In the initial period, after every 3 days, follow up was taken and in each appointment parents were asked to supervise the procedure. After parents satisfactorily learnt applying, removing and cleaning of appliance, follow up was taken every 7 days. During every appointment, first soft tissue examination was done to check for any ulcer or erythematous lesion, columella tear or any other soft tissue complication. Then progress of nasoalveolar moulding was checked by measuring alar height and width as well as size of alveolar cleft and after that modification of nasoalveolar plate (adding of soft liner and selective trimming of plate) and nasal stent was done to achieve the desired moulding. Every 15 days, impression was taken, 2 casts were poured, one for record purpose and other for new nasoalveolar moulding plate fabrication.

The intraoral cleft gap was reduced to 4 mm at the 90th day by gradual lip tapping and alveolar moulding (Fig 1.4). There was also improvement in the shape of both nostrils. The patient was then referred to the Department of Plastic Surgery where surgery was carried out at six months of age after fulfillment of preoperative criteria. There was even size of nostril and normal repositioning of columella which gave sufficient esthetic result after surgery.

Fig. 1.1

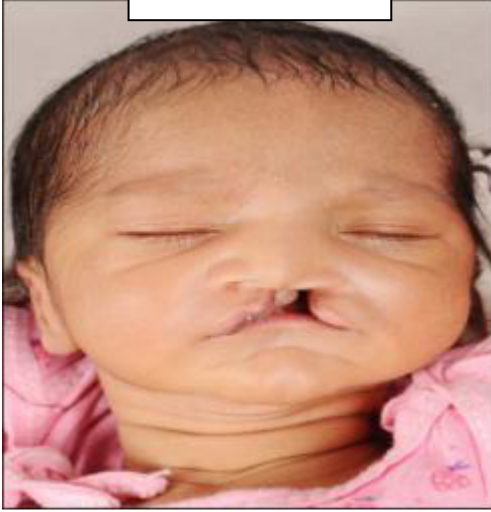

Fig. 1.3

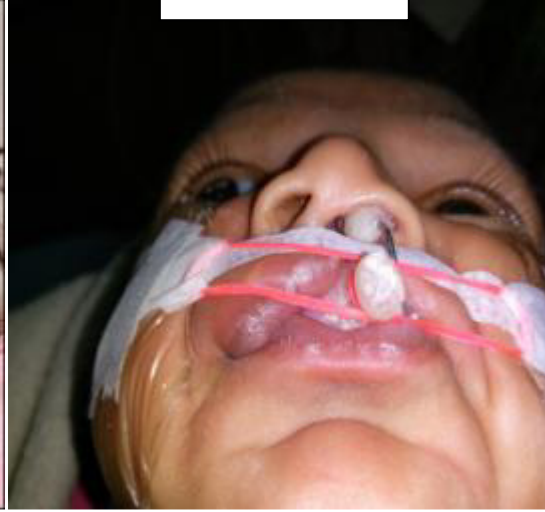


Fig. 1.2

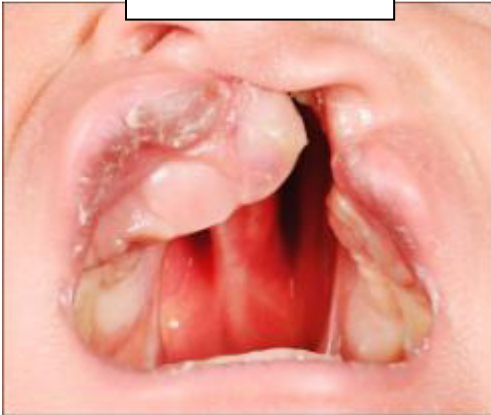
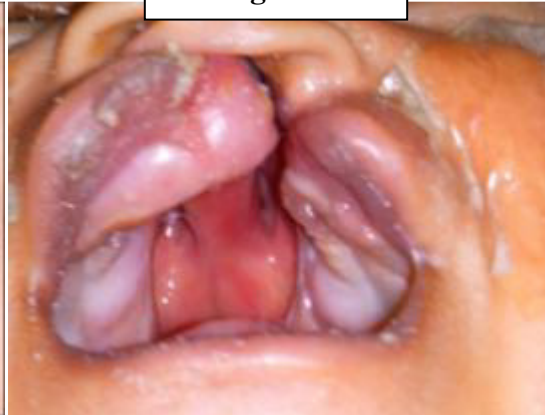
Fig. 1.4



Case report 2:

A 9-day-old male child with complete bilateral cleft lip and palate was brought to the department of Pedodontics and Preventive Dentistry of our institute with negative medical and family history except consanguineous marriage. The parents reported that their child found difficulty in feeding due to nasal regurgitation of milk. He had a nasal deformity which included depressed wide nostrils on either side of the cleft, flat nose and with no columella referred to as

“zero columella” (Fig 2.1). There was alveolar segment displacement with protruding premaxilla separating both the segments (Fig 2.2). Same day impression was taken and next day final impression was taken with custom tray. As in unilateral case tegaderm was applied and nasoalveolar moulding plate was given having two acrylic buttons (Fig 2.3). Lip taping and placement of plate was done in the same manner as in unilateral case with the addition of one more micropore tape with elastic placed on the prolabium for retraction of premaxilla. Addition of

nasal stent was done at the 18th day and continued till 90th day. Follow up was taken as in unilateral case. After 3 months of age, there was columella

lengthening and approximation of alveolar segments on the left side and decreased amount of gap on the right side (Fig 2.4).

Fig. 2.1

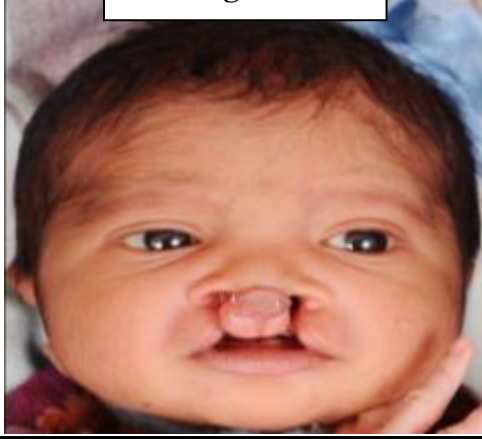

Fig. 2.3

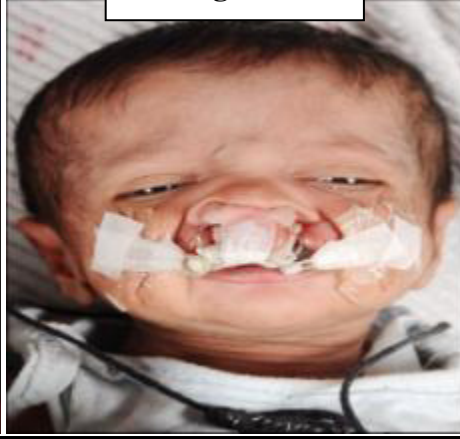


Fig. 2.2

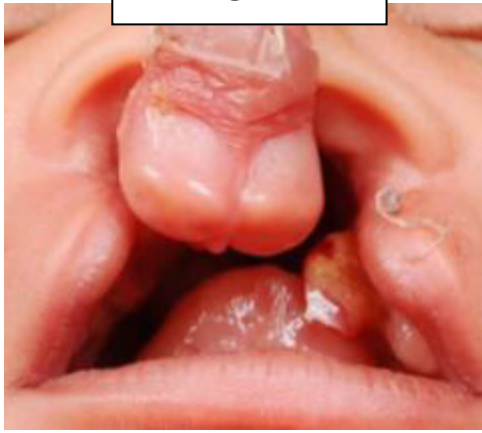
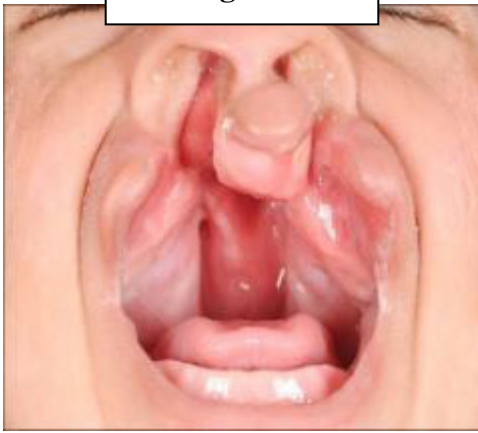
Fig. 2.4



CASE REPORT 3:

A 12 day old female patient with complete unilateral cleft lip and palate was referred from Plastic Surgery Department to our department with negative systemic and family history. The patient had difficulty in feeding due to nasal regurgitation of milk. As discussed in the previous case reports, primary and

final impressions were taken and nasoalveolar plate was delivered to the patient at the 16th day. Lip tapping, alveolar moulding and nasal moulding were done in the same manner as in the 1st case report with regular follow up. The alveolar defect was 21 mm at the beginning of procedure and reduced at 14mm at the end of 45 days and 9 mm at the end of 90 days.

There was also an improvement in the shape of nostril as well as size of columella (Fig 3.4). In between, after 22 days of the moulding procedure, parents came with the complaint of a mobile natal tooth which was in the region of greater segment of

the cleft. The tooth interfered with the proper positioning of the NAM plate. Hence it was extracted rather than following any other conservative approach to avoid the risk of the tooth being aspirate

Fig. 3.1

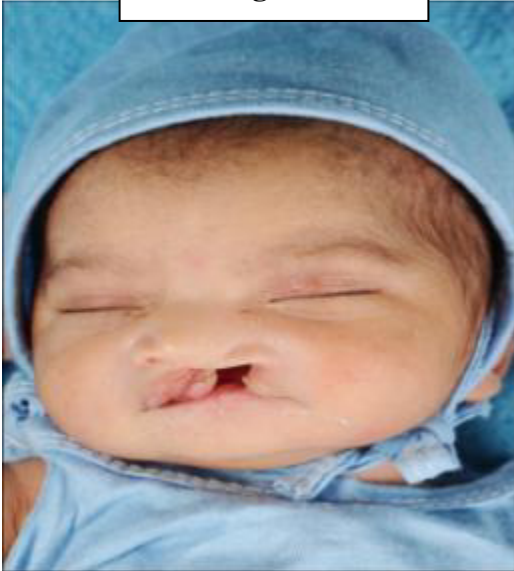

Fig. 3.3

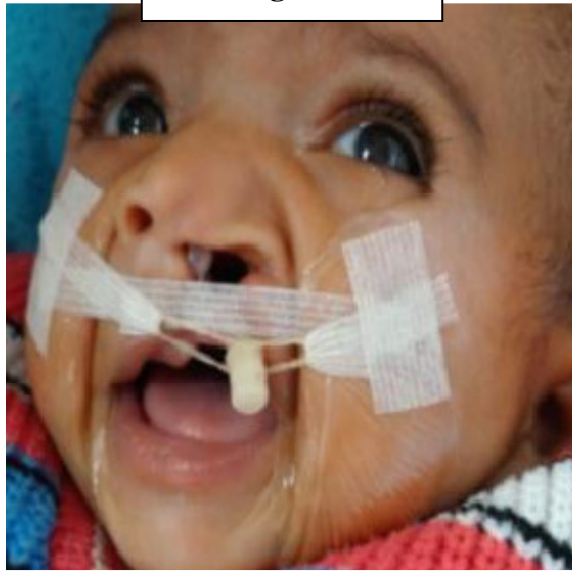


Fig. 3.2

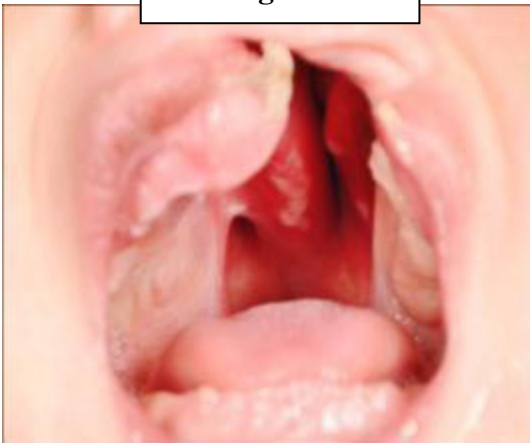
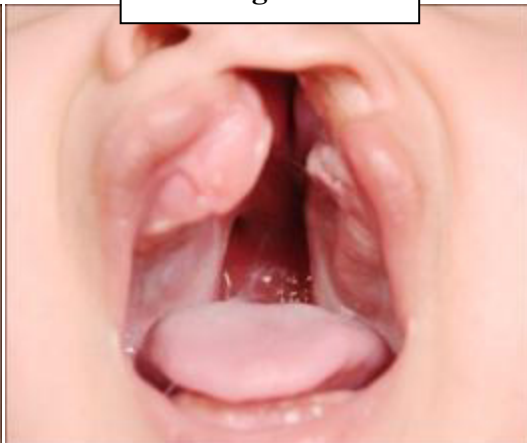
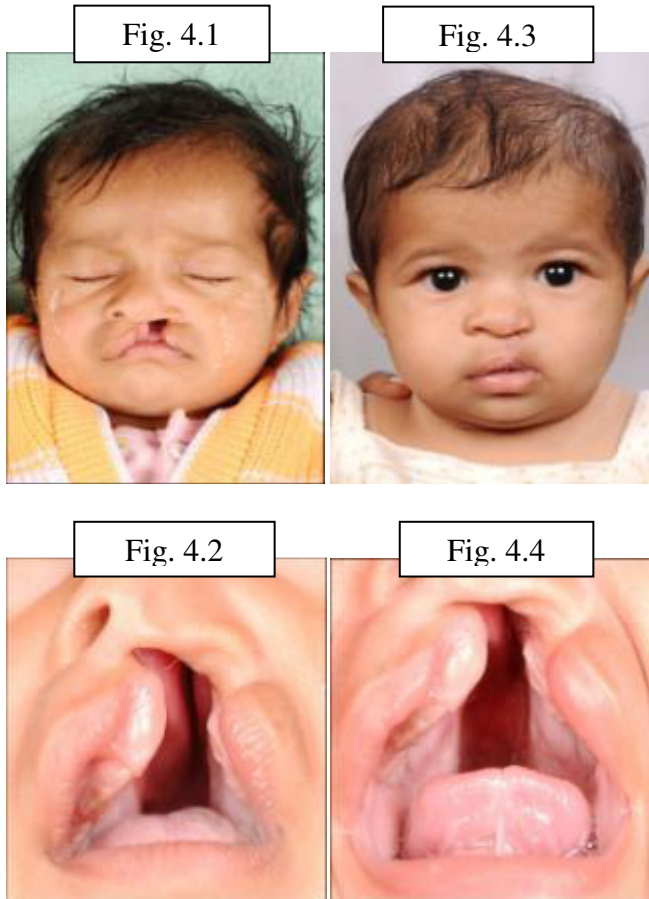Fig. 3.4



CASE REPORT 4

A 9 day old female patient with complete unilateral cleft lip and palate was referred from Plastic Surgery Department to our department with negative systemic and family history. All the procedures were performed as mentioned in the previous case reports.

The alveolar defect was 16 mm at the beginning of procedure and reduced at 11 mm at the end of 45 days and 8 mm at the end of 90 days with an improvement in the shape of nostril as well as size of columella.



Discussion:

In accordance with the principle of nasoalveolar moulding, PNAM appliance applies constant low-grade pressure to reshape and reposition labial, alveolar and nasal tissues to the most anatomic position possible⁽⁹⁾. Newborns should be evaluated as early as possible, preferably within the first 2 weeks of life (Da Silveira et al., 2003)^(9, 10). This is because the alar cartilage is soft and plastic at birth much like auricular cartilage. It is correctable in the

early neonatal period because of the high estrogen concentrations in the newborn's blood during the first 15 days of life. Estrogen increases the level of hyaluronic acid, which subsequently increases the level of plasticity of the cartilage (Hardingham and Muir, 1972)^(9, 11). This flexibility can be used for moulding of tissues as early and quickly as possible. The adjustments of the nasal moulding stent portion were also very easily and quickly performed, thus

creating pressure mesially as well as upwards for elevation of the nostril^(9, 12). At every 7 days follow up, nasal stent was activated till sufficient blanching of the outer rim of ala was seen. In these case reports, the parents found it very easy to insert the appliance and apply the tapes by themselves after 2 to 3 follow up sessions. The newborn could not take the appliance off with his hands because his parents always kept woolen gloves placed over his hands⁽⁹⁾.

The newborn had significantly improved symmetry of his nose as compared to the beginning of the procedure. The nasal width decreased, the columella length increased, and the alar cartilages molded to a more normal shape. The alveolar and the lip segments were approximated much closer to each other⁽⁹⁾. In unilateral case, there was more nasal improvement and less alveolar improvement and in bilateral case, there was good nasal improvement and alveolar approximation on left side compared to the right side. In bilateral case, there was no improvement in alveolar approximation after 55 to 60 days. This may be due to retraction of premaxilla resulting in deviation of nasal septum while touching the hard palate and hence decreasing further alveolar approximation.

Impression taking is the most critical step of PNAM as it can lead to a medical emergency of respiratory choking caused by tearing and aspiration of impression material due to the child exhibiting strong sucking reflex in a very small oral cavity⁽¹⁾. Presence of high evacuation system and anesthetist may help if such type of emergency arises. Tegaderm is applied to prevent peeling of skin as a base tape but sometimes an erythematous lesion may develop below the tegaderm⁽¹⁾. In such a case, it is better to carefully remove the tegaderm with a wet cotton and apply a soothing agent for some days and discontinue

nasoalveolar moulding.

Some other practical problems were also encountered in the cases discussed in this article. In unilateral case, because of less convexity of the wire component of nasal prong, difficulty was found in proper lip taping for 15 days. So another nasoalveolar plate was fabricated with the wire component having proper convexity to provide sufficient room for lip taping. In bilateral case, ulceration of alveolar mucosa occurred as a result of sharp margin of plate impinging upon it, which was then trimmed in the next appointment. There was also rocking of the plate intraorally which was managed by changing the position of elastics or acrylic button or direction of placement of tapes.

We believe that the appliance described in these case reports can be helpful in other patients with cleft lip and palate because it is very easy to fabricate, practical to activate, and comfortable for both the patient to wear and the parents to use⁽⁹⁾. But it requires a significant parental commitment, without which the pediatric dentist's continuing adjustments cannot be productive⁽¹³⁾.

Conclusion:

PNAM should be considered soon after birth to promote a physiological pattern of function, which eventually sets the course for the functional patterns in later life⁽¹⁴⁾. The Pediatric dentist is one of the early caregivers consulted for fabrication of feeding plate who must take the opportunity for this kind of treatment approach.

It effectively improves nasal symmetry in terms of nostril width, height and columella angle. Patients also benefit by a decreased severity of alveolar cleft and decreased number of surgeries required to close the cleft⁽¹⁴⁾. It also increases the mucosal lining which helps the surgeon for proper esthetic lip closure and decrease in the chances of scar formation.

Hence, PNAM, when performed prior to primary lip repair, will give psychological reassurance to parents, enhance surgical outcome, reduce the need for soft tissue revision surgeries later on and also reduce the overall cost of treatment.

References:

1. Barry H. Grayson and Pradip R. Shetye; Presurgical nasoalveolar moulding treatment in cleft lip and palate patients: *Indian J Plast Surg.* 2009 Oct; 42(Suppl): S56–S61
2. Millard D. *Bilateral and rare deformities.* 2nd ed. Boston: Little Brown; 1977. *Cleft craft: The evolution of its surgery.*
3. Goldwyn RM, Hullihen SP. Pioneer oral and plastic surgeon. *PlastReconstr Surg.* 1973;52:250–7.
4. Brophy TW. Cleft lip and cleft palate. *J Am Dent Assoc.* 1927;14:1108.
5. Georgiade NG, Latham RA. Maxillary arch alignment in the bilateral cleft lip and palate infant, using pinned coaxial screw appliance. *PlastReconstr Surg.* 1975;56:52–60
6. Grayson BH, Cutting C, Wood R. Preoperative columella lengthening in bilateral cleft Lip and palate. *PlastReconstr Surg.* 1993;92:1422–3
7. Grayson BH, Santiago PE, Brecht LE, Cutting CB. Presurgical nasoalveolar moulding in infants with cleft lip and palate. *Cleft PalateCraniofacJ.* 1999;36:486–98.
8. Grayson BH, Cutting CB. Presurgical nasoalveolar orthopedic moulding in primary correction of the nose, lip and alveolus of infants born with unilateral and bilateral clefts. *Cleft PalateCraniofac J.* 2001;38:193–8.
9. CenkDoruk, D.D.S., M.S. BanuKilic, D.D.S. Extraoral Nasal Molding in a Newborn With Unilateral Cleft Lip and Palate:A Case Report; *Cleft Palate–Craniofacial Journal*, November 2005, Vol. 42 No. 6
10. Da Silveira AC, Oliveira N, Gonzalez S, Shahani M, Reisberg D, Daw JL, Cohen M. Modified nasal alveolar molding appliance for management of cleft lip defect. *J Craniofac Surg.* 2003;14:700–703
11. Hardingham TE, Muir H. The specific interaction of hyaluronic acid with cartilage proteoglycans. *BiochemBiophysActa.* 1972;279:401–405.
12. Matsuo K, Hirose T, Otagiri T, Norose N. Repair of cleft lip with nonsurgical correction of nasal deformity in the early neonatal period. *PlastReconstr Surg.* 1989;83:25–31.
13. JungWei Chen DDS, MS, PhD; LLU School of Dentistry Newsletter: Loma Linda University
14. Dolly Patel, Ramesh Goyal; Pre-surgical nasoalveolar moulding in patientwith unilateral cleft of lip, alveolus andpalate: Case report: *Journal of Plastic, Reconstructive & Aesthetic Surgery* (2012) 65, 122e126