

**Original article:**

## **Cadaveric study in south Indian population to identify a safe zone for axillary nerve in shoulder surgeries**

**Dr.Thirunarayanan Vasudevan \*, Dr.Ramprasath Dhurvas Ramlal , Dr.Arularasan Samraj**

Department of Orthopaedic Surgery, Government Royapettah Hospital, Chennai, Tamilnadu, India.

\*Corresponding author: Dr. Thirunarayanan Vasudevan

### **Abstract:**

**Background:** Axillary nerve is at potential risk of injury in surgeries around proximal humerus. Two approaches universally followed are 1) Deltopectoral and 2) Deltoid splitting. The deltopectoral approach has the advantage of a better exposure but has disadvantage of more soft tissue dissection and vascular compromise to the head of humerus. The deltoid splitting approach provides easy access but carries the risk of a potential danger to axillary nerve. Purpose of this study is to find a safe zone for axillary nerve in surgeries around proximal humerus in south Indian population.

**Materials and methods:** We used 20 fresh cadavers (40 shoulders). We approached the proximal humerus by deltoid splitting approach in all shoulders and then erased the entire deltoid muscle from its origin, to study the entire course of the axillary nerve.

**Results:** The Average arm length - $31.2 \pm 4.18$  cm , The mean axillary nerve to acromion distance - $5.6 \pm 1.02$  cm , The mean axillary nerve to greater tuberosity distance -  $5.14 \pm 1.1$  cm , The mean axillary nerve to deltoid tuberosity distance -  $5.18 \pm 1.82$  cm

**Conclusion:** In longitudinal axis, the safe zone for axillary nerve in surgeries around proximal humerus in south Indian population would be 5.6 cm from the angle of acromion (Distance of 4.07cm gives 99.7% confidence level).The safe zone increases by 1.67mm for every 1cm increase in arm length.

**Keywords:** Arm length, Axillary nerve, Cadaveric, Safe zone, Shoulder

### **Introduction:**

The axillary nerve is a branch of the posterior cord of brachial plexus, with root values C5C6. It exits through the quadrilateral space and splits into anterior and posterior branches. The anterior branch gives off branches to anterior and middle fibres of deltoid. The posterior branch gives off the upper lateral cutaneous nerve of arm and motor branches to Teres minor & posterior fibres of deltoid<sup>1</sup>.

Two approaches universally followed for the proximal humerus are 1) Deltopectoral approach<sup>2</sup> and 2) Deltoid splitting approach<sup>2,3</sup>. The deltopectoral approach has the advantage of a better exposure but disadvantage of more soft tissue dissection and vascular compromise

endangering the vascularity of the head of humerus.

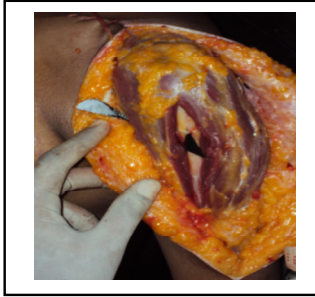
The deltoid splitting approach provides easy access but carries the risk of a potential danger to axillary nerve<sup>2,3</sup>. The purpose of this study is to find a safe zone for axillary nerve in surgeries around proximal humerus in south indian population.

### **Methodology:**

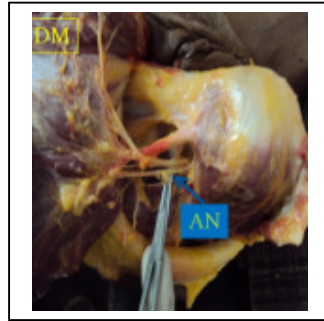
We dissected 40 shoulders of 20 fresh cadavers (less than 24 hours after death) out of which 12 were male and 8 were female. We approached the humerus by deltoid splitting approach in all shoulders(as in **Fig.1**). After performing the deltoid splitting approach, the entire deltoid muscle was subsequently erased from its origin( as in **Fig.2**) . The course of the nerve was traced from the level of the quadrangular space till its terminal branch, in

all the 40 shoulders. The cadaver was placed in lateral position with shoulder in neutral position. All measurements were taken after deltoid splitting

and only after the measurements were taken the deltoid muscle origin was erased.



**Fig.1** Illustration of the deltoid splitting approach



**Fig.2** Axillary nerve(AN) after erasing deltoid

After tracing the course of the nerve, the following parameters were measured.

**Height**

The height of the cadaver was measured from the vertex of the head to the heel.

**Length of the upper limb**

Measured from the lateral edge of acromion to the radial styloid process

**Length of the arm**

Measured from the lateral edge of acromion to the lateral epicondyle

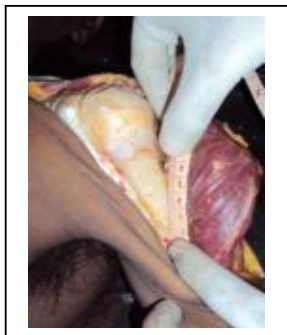**Distance from Axillary nerve to**

Angle of acromion (lateral edge of acromion) (**Fig.3**)

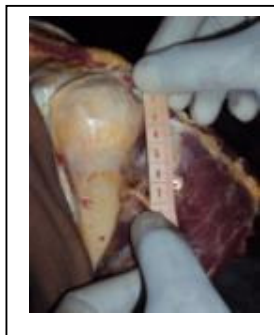Greater tuberosity (highest point) (**Fig.4**)

Deltoid tuberosity(**Fig.5**)

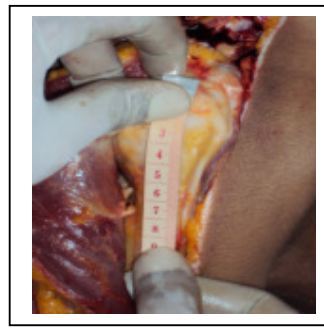All the measurements were taken with the shoulder in neutral abduction adduction plane



**Fig.3** Lateral edge of acromion to axillary nerve distance



**Fig.4** Greater tuberosity to axillary nerve distance



**Fig.5** Deltoid tuberosity to axillary nerve distance

***We also measured the following ratios***

Ratio of Arm length to axillary nerve-acromion distance

Ratio of Arm length to axillary nerve- greater tuberosity Distance

**Observation &results:**

The average measured values are listed below:

The mean average arm length :  $31.2 \pm 4.18\text{cm}$

The mean distance between axillary nerve and acromion :  $5.6 \pm 1.02\text{cm}$  ( Distance of 4.07cm gives 99.7% confidence level)

The mean distance between axillary nerve & greater tuberosity(highest point) :  $5.14 \pm 1.1\text{cm}$

The mean distance between axillary nerve and deltoid tuberosity:  $5.18 \pm 1.82\text{cm}$

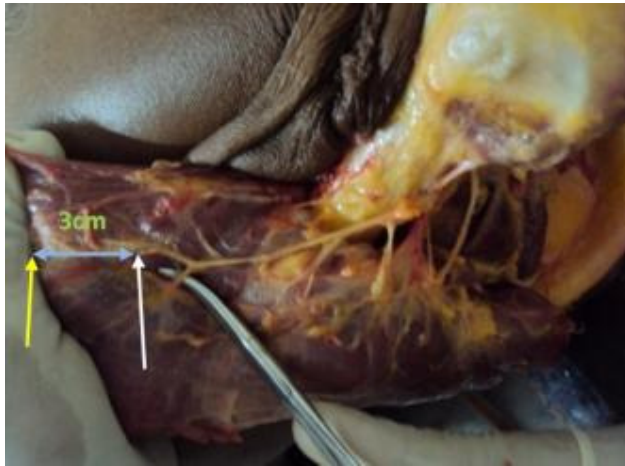
A strong positive correlation exist between arm length and acromion - axillary nerve distance, which is indicated by the Pearson's R Correlation value of 0.685204(statistically significant with a p value of  $< 0.0001$  as per analysis of variance test).

Only in one case the axillary nerve to acromion distance was 4.7 cm. In all other cases the minimum distance was 5.0 cm and above.

The observations and analysis of our study is given in **Table.1**

***Anatomic variations observed***

1. In 4 shoulders (10%) the posterior part of deltoid was supplied by the anterior branch
2. In 3 shoulders (7.5%) the anterior branch stops at about 3 cm from the anterior border of deltoid (**Fig.6**).



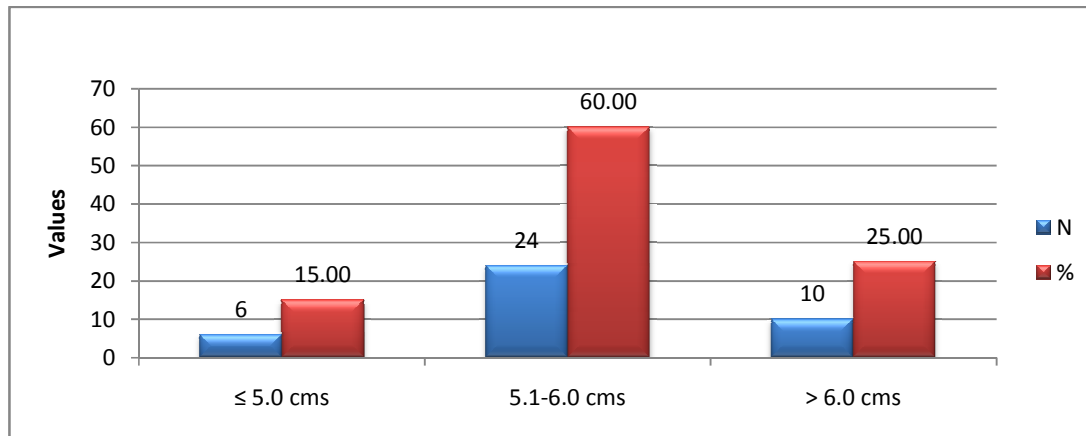
**Fig.6** Anterior branch ended 3cm before anterior deltoid border

**TABLE 1- Observations and analysis of our study group**

Age	Sex	Height (cm)	Arm length(cm)		Circumference of Deltoid(cm)		Acromion- Axillary Nerve		Greater tuberosity- axillary Nerve		Deltoid tuberosity- Axillary Nerve	
			Right	Left	Right	Left	Right	Left	Right	Left.	Right	Left
22	F	160	31	31	12.5	13	5.7	6.1	4.5	4.9	5.5	6
40	M	170	34	34	15	14.5	6.5	6.3	5.6	5.3	7	7
35	M	165	32	32	14	13.8	6.1	6.1	4.9	4.9	6	6
30	M	170	33	33	14.5	14.5	6.3	6.3	5.6	5.6	6.5	6.7
45	M	159	29	29	14	14	5.2	5	4.6	4.4	6.5	6.5
25	M	160	31	31	13	12.5	5.9	5.7	4.7	4.5	5	5
40	F	162	32	32	13	13	5.8	6	4.7	4.9	5	5.3
41	M	166	33	33	14.2	14	6	5.9	5	5	5.3	5.6
35	F	150	27	27	12	11.5	4.7	4.8	4.4	4.4	5.8	4.6
30	F	158	30	30	13	12.5	5.8	5.6	4.9	4.9	5.8	5.8
19	F	150	30	30	11.2	11.5	5.1	5.3	5	5	4.1	4.5
20	M	173	35	35	11	11.5	5	5.1	5	5.2	4	4.1
22	M	162	31	31	11.4	12	5.7	5.5	5.5	5.7	4.5	4.8
26	M	171	34	34	13	13.5	5.9	6.1	5.8	5.9	4.9	5.3
32	M	160	30	30	12.5	13.2	5.2	5.4	5.1	5.3	4	4.4
32	F	152	30	30	13.5	13	5.1	5	5	4.8	4.5	4.2
33	M	167	30	30	13	13.5	5.1	5.3	5.1	4.9	4.1	4.3
36	F	150	29	29	14.5	14.5	5	5.2	5.1	5.4	4.1	4.4
41	M	171	34	34	12.5	13	6.5	6.3	7	6.7	5.6	6
43	F	162	29	29	13.5	14	5.2	5.4	5.1	5.3	4.1	4.5

**Statistical analysis:**

Acromion-Axillary Nerve Distance

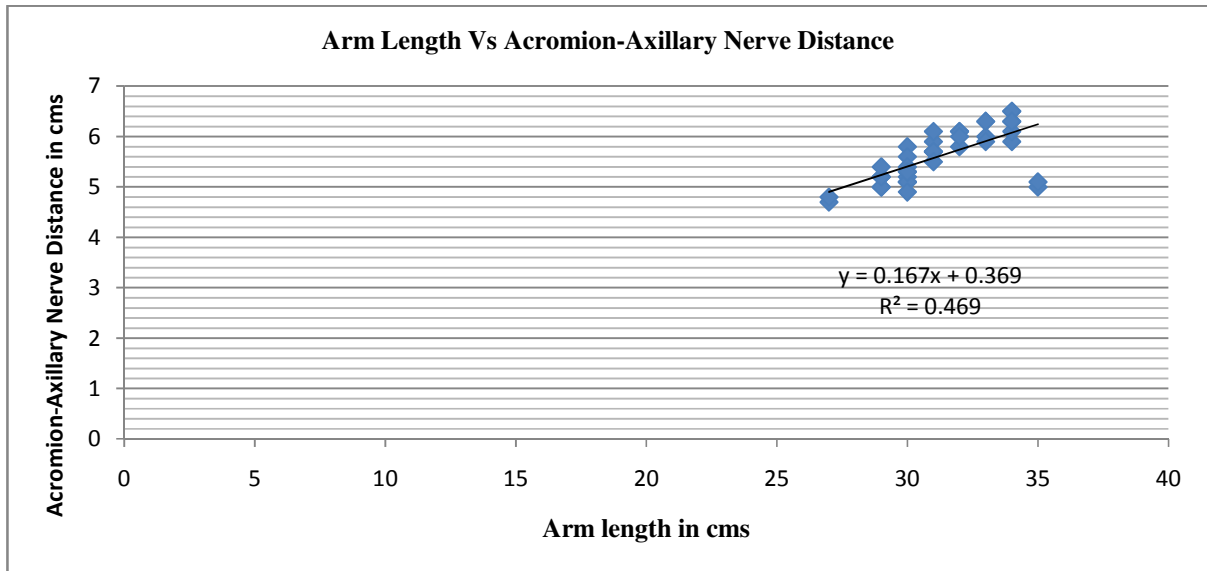


Acromion-Axillary Nerve Distance	No. of shoulders	%
≤ 5.0 cms	6	15.00
5.1-6.0 cms	24	60.00
> 6.0 cms	10	25.00
0	0	0.00
Total	40	100

Acromion-Axillary Nerve Distance	Values
No. of shoulders	40
Mean	5.60
SD	0.51
Range – Min	4.7
Range – Max	6.5

The results for acromion-axillary nerve distance distribution indicated that majority of the cadavers had acromion-axillary nerve distance between 5.1-6.0 cms (n=24, 60%) with a mean acromion-axillary nerve distance of 5.6 cms and ranging from 4.7- 6.5 cms.

Arm Length Vs Acromion-Axillary Nerve Distance



<i>Regression Statistics</i>	
Multiple R	0.685204
R Square	0.469504
Adjusted R Square	0.455544
Standard Error	0.377534
Observations	40

<i>ANOVA</i>					
	<i>Df</i>	<i>SS</i>	<i>MS</i>	<i>Significance F</i>	
Regression	1	4.793523	4.793523	33.63114	0.0000
Residual	38	5.416227	0.142532		
Total	39	10.20975			

	<i>Coefficients</i>	<i>Standard Error</i>	<i>t Stat</i>	<i>P-value</i>	<i>Lower 95%</i>	<i>Upper 95%</i>	<i>Lower 95.0%</i>	<i>Upper 95.0%</i>
Intercept	0.369542	0.904325	0.408639	0.685099	-1.4611683	2.200253	-1.46117	2.200253
Arm length(cm)	0.167723	0.028922	5.799236	1.07E-06	0.1091744	0.226272	0.109174	0.226272

There is a strong positive correlation between arm length and acromion-axillary nerve distance. This is indicated by the Pearson's R Correlation value of 0.685204. This direct correlation is significant with a 'p' value of < 0.0001 as per analysis of variance test. The percentage change is also explained in the scatter plot. This linear model explains all the variability of the response data around its mean.

Since  $R^2$  is 0.469504, "the fitted regression equation explains 46.95% of the variation in Y"( $Y=0.1677x + 0.3695$ ).

We can conclude that larger the arm length larger the acromion-axillary nerve distance. For each cm increase in arm length, acromion-axillary nerve distance increases by 0.1677 cm. The 68% correlation of variation in arm length in relation to acromion-axillary nerve distance is validated 46,95% of times.

#### **Discussion**

Proximal humerus is approached in various indications like mini open rotator cuff repair, proximal humerus fractures (closed pinning, open plating, minimally invasive plating), humerus nailing, external fixation and shoulder arthroplasty etc. Deltoid splitting and the Deltopectoral approach are the two most common surgical approaches. The axillary nerve is very vulnerable for injury especially in deltoid splitting approach<sup>5</sup>.

In our study the lateral edge of acromion to axillary nerve distance<sup>6,7,8,9,10</sup> (Abhinav,kamineni, smith, eran mamman, kulkarni), the highest point on greater tuberosity to axillary nerve distance ,and the axillary nerve to deltoid tuberosity distance<sup>11</sup> (nassar et al) were measured in 20 fresh cadavers (40 shoulders). Also the length of the arm and its relation to the acromion – axillary nerve distance has been identified. All these measurements were taken with the shoulder in neutral position.<sup>6,9,12</sup>

The reason for selecting acromion and greater tuberosity is that, these two landmarks can be used

in surgeries as they can be easily marked with C-arm in theatre. In fractures around humerus ,the greater tuberosity may get displaced. This may be the reason why this parameter was not found in literature review. In proximal locking for intramedullary nailing for fracture shaft of humerus and shoulder arthroplasty this distance (axillary nerve to greater tuberosity) may give an additional safety measurement. In a cadaveric study on chinese population by kuang-yi liu et al and in a cadaveric study on caucasian population by bono and grossman et al, the distance of axillary nerve from a point on the superior aspect of humeral head was taken<sup>13,14</sup>. These two anatomical landmarks( the greater tuberosity and superior aspect of humeral head) are certainly not the same but mentioned here as they are both landmarks in the proximal humerus itself.<sup>13,14</sup>

The measurement of axillary nerve to deltoid tuberosity is also not used much in literature. In proximal humerus fractures and in cases where the acromion is also injured or altered this variable can be used. If a distal split of deltoid is required this value of axillary nerve to deltoid tuberosity may be very useful. Nassar et al in his study has calculated the safe distance of axillary nerve by finding the distance between the acromioclavicular joint and deltoid tuberosity and multiplying that value by 0.48 in males and 0.40 in females<sup>11</sup> to calculate safe zone for axillary nerve from lateral edge of acromion.

Many studies have given a wide range of measurements of the lateral edge of acromion to axillary nerve distance from one and half inches(3.75cm) by Abbott et al, 3.4 cm by Duparc et al, to 7.0 cm by Hoppenfeld and deBoer<sup>15,16,2</sup>. The comparative analysis of our study and various other studies are given in Table 2.

**Table2. Comparative analysis with other cadaveric studies**

	Range(cm)	Mean(cm)	No of cadavers	Acromion reference point
<b>Our study</b>	4.7-6.5	5.6±1.02	20	Lateral edge
<b>Abhinav et al</b>	4.5-6.5	6.0	15	Lateral edge
<b>Kamineni et al</b>	3.5-7.0	5.7	40	Lateral edge
<b>Smith et al</b>	6.2-8.5	7.2	6	Lateral edge
<b>Eran mamanan et al</b>	3.5-5.5(ht<170cm) 4.5-6.8(ht>170cm)	4.66 5.45	60	Lateral edge
<b>Cetik et al</b>	5.2-6.9 4.3-5.5	6.08 4.87	24 12	Anterior edge Posterior edge
<b>Gardener et al</b> <b>Gardener et al</b>	5.32-7.04	6.33 6.0	20 6	Undersurface Anterolateral edge
<b>Uz et al</b>	6.4-8.8	7.8	15	Posterolateral edge
<b>Bono et al</b>	4.5-6.9	6.09	50	Superior aspect of humeral head

The mean distance of 5.6 cm in our study is comparable to 5.7cm measured by Kamineni et al but lesser than 6.0 cm by Abhinav et al and 7.2 cm by Smith et al<sup>7,6,8</sup>. In all these studies the lateral edge as in our study was taken as reference point in acromion. Abhinav et al has taken the acromion – axillary nerve distance in neutral, adduction and abduction positions of shoulder and arrived at three different sets of values respectively<sup>6</sup>. For comparison with our study only the values in neutral position of shoulder (as in our study) has been taken. In a study by eran mamman et al the author has grouped the cadavers into two categories based on the height of cadaver <170 cm as one group and > 170 cm as another group<sup>9</sup>. He has arrived at two different means of 4.66 cm and 5.45 cm for the two groups respectively. In other studies

the acromion reference points have been different and an identical comparison could not be made.<sup>17,18,19,13,14</sup>

In our study the mean is 5.6 cm and 3SD is 1.53. Within a minimum distance of 4.07cm (Mean-3SD), a confidence interval of 99.7% can be achieved. Hence a minimum of 4.07cm distance from the lateral edge of acromion can be considered as the safe zone for axillary nerve in our study. Abhinav et al in his study has proposed a distance of 4.2cm (mean-3SD) as the minimum acromion – axillary nerve distance with 99.7% confidence interval<sup>6</sup>.

In our study only in one case the acromion – axillary nerve distance was 4.7 cm. In all other cases the minimum distance was 5.0 cm and above. Burkhead et al in his study on 51 embalmed and 5



fresh cadavers found out that in one fifth of cases the distance was less than 5.0 cm with a minimum of 3.1 cm<sup>20</sup>. The embalmed nature of the cadaver could have given such a difference.<sup>18,20</sup>

Kontakis in his study on 134 shoulders arrived at the position of axillary nerve in the deltoid by calculating the deltoid ratio (width/length of deltoid muscle)<sup>4</sup>. The axillary nerve in this study was located at a mean of 2.6(1.7-3.4) cm above the midpoint (length) of the deltoid. In cadaver it may be possible but in surgeries it is not practically possible to measure this ratio. He concluded that the shorter the deltoid length the greater the danger of injury to the axillary Nerve at a short distance from the upper end of deltoid.

The acromion-axillary nerve distance has a strong association with the arm length. Our study shows that as arm length increases, the safe zone for axillary nerve also increases proportionately (1.67mm for every 1 cm increase in arm length). Though Cetik et al measured the axillary nerve distance from the anterior edge and posterior edge of acromion arch separately, he concluded that there is a strong association in both these measurements to the arm length. Though abhinav et al found a strong correlation between Acromion-Axillary Nerve distance and Arm length ratio, they said using an adjusted mean minus a factor of 0.2 cm per 1.0 cm, for shorter arms this still would have resulted in some nerves being cut due to variability in the nerve positions<sup>6</sup>. They agreed to the findings of Kontakis et al that measurement of arm length during surgery does not allow accurate

application of linear regression equation for determination of safe zone for the nerve<sup>21, 6,17,21,22</sup>

In four shoulders (10%) the posterior part of deltoid was supplied by the anterior branch (c.f. "The posterior aspect of the deltoid has a more consistent supply from the anterior branch of the axillary nerve, necessitating caution when performing a posterior deltoid-splitting approach to the shoulder" – **Gray's Anatomy**)<sup>1</sup>

In 3 shoulders the anterior branch stops at about 3 cm from the anterior border of deltoid (**fig.7**)

(c.f. "Anterior branch reaches the Anterior border of the deltoid muscle, supplies it and gives off a few small cutaneous branches which pierce deltoid and ramify in the skin over its lower part" – **Gray's Anatomy**) probably the divisions in the anterior end were too small to be visualized by our eyes<sup>1</sup>.

#### **Conclusion**

In longitudinal axis, the safe zone for axillary nerve in surgeries around proximal humerus would be 5.6cm from the angle of acromion in south Indian population. A value of 4.58 cm gives a 95% confidence limit which is mean minus 2SD. The mean minus 3SD which will include 99.7% population is a better value in this study. In 99.7% of cases if this value is kept in mind the axillary nerve will be free of any iatrogenic injury. In our study it is 4.07 cm. The distance from the acromion to the axillary Nerve is highly variable. The arm length has a strong correlation with the nerve distance from acromion. The safe zone increases by 1.67mm for every 1cm increase in arm length.

#### **References:**

1. S Standring. Gray's Anatomy. The Anatomical Basis of Clinical Practice. 41<sup>ST</sup> edition.
2. Hoppenfield S, DeBoer P. Chapter 1: The shoulder. In: Surgical exposures in orthopaedics: The anatomic approach. 3<sup>rd</sup> ed. Lippincott Williams and Wilkins; 2003. p. 29-33.
3. Terry canale S, James H. Beaty. Campbell's Operative Orthopaedics: Approach to axillary nerve. 12<sup>th</sup> edition. 2013; 4:3098-99

4. Kontakis GM, Steriopoulos K, Damilakis J, Michalodimitrakis E. The position of the axillary nerve in the deltoid muscle: A cadaveric study. *Acta Orthop Scand* 1999;70:9-11.
5. Isiklar.Z, Kormaz.F, Gogus.A, Kara.A. Comparison of deltopectoral versus lateral deltoid split approach in operative treatment of proximal humeral fractures. *EFORT –European Federation of National Associations of Orthopaedics and Traumatology(9<sup>th</sup> Congress)* 29 May-1 June 2008
6. Gulihar A, Sivaraman B, Matthew N,Taylor Grahame JS. A contribution to the calculation of a safe deltoid split. *Int.J Shoulder surg* 2008,2:3:52-5.
7. Kamineneni S. Ankem H. Sanghavi S. Anatomical considerations for percutaneous proximal humeral fracture fixation. *Injury* 2004; 35: 1133-36
8. Jason Smith, Greg Berry, Yves Laflamme, Etienne Blain-Pare, Rudy Reindl, Edward Harvey. Percutaneous insertion of a proximal humeral locking plate: An anatomic study. *Injury*. 2007;38(2): 206-11
9. Eran maman, Guy Morag, Oleg Safir, Mony Benifla, Gavriel Mozes, Erin Bonyton. The Anterior Trunk of the axillary Nerve: Surgical Anatomy And Guidelines. A Fresh, Cadavers study. *J.Orthopaedics* 2008;5(2)e7
10. Kulkarni RR. Nandedkar AN. Mysorekar VR. Position of the axillary nerve in the deltoid muscle. *Anat.Rec.* 1992;232: 316-17.
11. Nassar JA. Wirth MA. Burkhart SS. Schenck RC, Jr. Morphology of the axillary nerve in an anteroinferior shoulder arthroscopy portal. *Arthroscopy* 1997; 12: 600-05.
12. Bailie DS, Moseley B, Lowe WR. Surgical anatomy of the shoulder: Effects of arm position and antero-inferior capsular shift. *J Shoulder Elbow Surg* 1999;8:307-13.
13. Kuang-Yi Liu, Tien-Hua Chen, Jia-Fwu Shyu, Shih-Tien Wang, Jenn-Yuan Liu, Po-Hsin Chou. Anatomic study of the axillary nerve in a Chinese cadaveric population: correlation of the course of the nerve with proximal humeral fixation with intramedullary nail or external skeletal fixation. *Arch Orthop Trauma Surg* DOI 10.1007/s00402-010-1184-2
14. Bono CM. Grossman MG. Hochwald N. Tornetta P, III. Radial and axillary nerves. Anatomic considerations for humeral fixation. *Clin.Orthop.Relat Res.* 2000; 259-64.
15. Abbott L C, Saunders B M, Hagey H, Jones E W. Surgical approaches to the shoulder joint. *J Bone joint Surg(Am)* 1949;31 (2): 235-55.
16. Duparc F, Bocquet G, Simonet J, Freger P. Anatomical basis of the variable aspects of injuries of the axillary nerve (excluding the terminal branches in the deltoid muscle). *Surg Radiol Anat.* 1997;19:127 -32.[Medline]
17. Cetik O. Uslu M. Acar HI. Comert A. Tekdemir I. Cift H. Is there a safe area for the axillary nerve in the deltoid muscle? A cadaveric study. *J.Bone Joint Surg.Am.* 2006; 88: 2395-9.
18. Gardner MJ, Voos JE, Wanich T, Helfet DL, Lorch DG(2006) Vascular implications of minimally invasive plating of proximal humerus fractures. *J Orthop Trauma* 20:602-607
19. Uz A, Apaydin N, Bozkurt M, Elhan A (2007) The anatomic branch pattern of the axillary nerve. *J Shoulder Elbow Surg* 16:240-244
20. Burkhead w z. Schienberg R R. Box G. Surgical anatomy of the axillary nerve. *J shoulder elbow surg.* 1992;31-36
21. Kontakis GM. Is there a safe area for the axillary nerve in the deltoid muscle? *J Bone Joint Surg Am* 2007;89:1134-5.
22. Vanthana P, Ratanalaka R, Chiarapattanakom, Vorasatit P. The relationship of the axillary nerve and the acromion. *J Med Assoc Thai* 1998;81;953-7.