

**Original article :**

## **Study of Anatomical Variations in Adult Human Scapulae**

**<sup>1</sup>Dr. Rohini M Pawar , <sup>2</sup> Dr. R. Manoranjitham**

<sup>1</sup>Associate Professor , Department of Anatomy , PIMS DU's Rural Medical College, Loni , Maharashtra

<sup>2</sup>Professor , Department of Anatomy , Dhanalakshmi Srinivasan Medical College, Perambalur , Tamilnadu

Corresponding author : Dr. Rohini M Pawar

---

### **Abstract:**

**Background-** Different Shapes of acromion process is clinically important as in impingement syndrome and rotator cuff tear. Variations in the shape of glenoid cavity is of paramount importance in designing and fitting glenoid component for total shoulder arthroplasty and shoulder joint replacement therapy. Anatomical variations of suprascapular notch is similarly helpful in arthroscopic procedure related to suprascapular nerve entrapment.

**Objectives-** To find out anatomical variations of acromion process, glenoid cavity and suprascapular notches.

**Method-** Present study was conducted on 105 scapulae. Various morphological types of acromion process, different shapes of glenoid cavity, suprascapular notch were observed and studied.

**Results-** 1. Morphological types of acromion process found to be; type I (flat)- 43 (40.95 %), type II (curved)- 51 ( 48.57 %), type III (hooked)- 11 (10.47 %). 2. Various shapes of glenoid cavity determined as; pear, oval and inverted comma. 3. Five different types of suprascapular notch were noted, commonest being Type III- 47 (44.76%).

**Conclusion-** Morphological types of acromion process are helpful for orthopaedic surgeon as well as for anthropologists in surgical repair of shoulder joint and in evaluation of bipedal gait respectively. The different shapes of glenoid cavity are helpful in designing and fitting glenoid prostheses. Study of variations in suprascapular notch helpful for clinicians in case of diagnosis and treatment of suprascapular nerve entrapment.

**Key-words:** Acromion process, glenoid cavity, suprascapular notch, anatomical variations.

---

### **Introduction:**

The scapula is a flat triangular bone situated posteriorly overlying the second to seventh ribs on both the side.[1] Morphologically acromion process of scapula is classified by many researchers into three types; type -I (flat), type-II (curved ), type-III (hooked).[2] Variations of acromion may be associated with pathogenesis like subacromial impingement syndrome and rotator cuff tear. [3] Anatomically the glenoid cavity is considered to be a head of scapula. [4] Various shapes of glenoid cavity is described earlier as; pear, round and oval or inverted comma.[5] Anatomical basis and variations in shape of glenoid is fundamentally important in clinical practice. Knowledge about shapes of glenoid cavity is essential in designing

and fitting of glenoid components during total shoulder arthroplasty. [6] The anatomical variations of suprascapular notch either in combination or with an anomalous superior transverse scapular ligament is responsible for suprascapular nerve entrapment syndrome.[7, 8]

### **Material and methods:**

The study was conducted in Anatomy and Forensic Medicine department after seeking an approval from Institutional Research and ethics committee (IREC). A total of dry 105 scapulae were selected; 52 were being from the right side and 53 from the left side. The bones belonged to mature specimens, but exact age and gender were not known. The bones were isolated and morphologically studied.

**Inclusion criteria:** All the scapulae which were

completely ossified and without any deformity.

**Exclusion criteria:** Scapulae with deformity, pathology or with any fracture.

**Results:**

1) Morphological types of acromion process- In the present study 105 scapulae were studied for variations in its morphological types. Different types of acromion processes studied were, I-flat, II-curved and III-hooked. We found distinct frequencies among acromion types. Type I were found in 43 (40.95%) of acromions, type II in 51 (48.57 %) and the type III in 11 (10.47 %). Type II acromion process was more frequent in our sample than type I and type III. **(Table 1. and Figure 1)**

2) Shape of acromion process- The variations in the different shapes of acromion process found during study were; triangular, quadrangular and tubular. Percentage frequency of these shapes found to be; triangular 27 (25.71%), quadrangular 47 (44.76%) and tubular 31 (29.52%). **(Table 2. and Figure 1)**

3) Shape of glenoid cavity- The variation in the shapes of glenoid cavity studied were pear, oval and inverted comma. Total 52 glenoid cavities of right scapulae were observed and studied. Out of

them 24 (46.15%) were of pear shaped, 9 (17.30%) were of inverted comma and 19 (36.53%) were found to be oval shaped. Total 53 glenoid cavities of left scapulae were observed and studied. Out of them 14 (26.41%) were pear shaped, 9 (16.98%) were inverted comma and 30 (56.60 %) were found to of oval shaped. **(Table 3. Figure III)**

4) Types of suprascapular notch- According to standard classification of Michael Polguy (2011), five different types of suprascapular notches were determined. In which, Type I - had a longer maximal depth than superior transverse diameter, Type II- equal maximal depth (MD), superior transverse diameter (STD) and mid transverse diameter (MTD), Type III- superior transverse diameter longer than the maximal depth, Type IV- with a bony foramen, Type V-has a discrete notch.

[9] Commonest Suprascapular notch was of type III (44.76%), while least common was of type IV (2.85%). Type –V suprascapular notch which is clinically important for suprascapular nerve entrapment (SSNE), was found 17.14%. **(Table 4. Figure IV)**

**Table –1. Morphological types of acromion process of scapulae.**

| Morphological types of acromion process | Right scapulae (n=52) | percentage | Left scapulae (n=53) | Percentage | Total | Percentage |
|---|-----------------------|------------|----------------------|------------|-------|------------|
| Type-I                                  | 24                    | 46.15%     | 19                   | 35.84%     | 43    | 40.95%     |
| Type-II                                 | 25                    | 48.07%     | 26                   | 49.05%     | 51    | 48.57%     |
| Type-III                                | 3                     | 5.76%      | 8                    | 15.09%     | 11    | 10.47%     |

**Table-2. Shapes of acromion process of scapulae.**

| Shape of acromion process | Right scapulae (n=52) | Percentage | Left scapulae (n=53) | Percentage | Total | Percentage |
|---------------------------|-----------------------|------------|----------------------|------------|-------|------------|
| Triangular                | 14                    | 26.52%     | 13                   | 24.52%     | 27    | 25.71%     |
| Quadrangular              | 23                    | 44.23%     | 24                   | 45.28%     | 47    | 44.76%     |
| Tubular                   | 15                    | 28.84%     | 16                   | 30.18%     | 31    | 29.52%     |

**Table-3. Comparison between shapes of glenoid cavity of right and left scapulae.**

| Shape of glenoid cavity | Glenoid cavity of right scapulae (n= 52) | Percentage | Glenoid cavity of left scapulae (n=53) | Percentage | Total | Percentage |
|-------------------------|--|------------|--|------------|-------|------------|
| Pear                    | 24                                       | 46.15%     | 14                                     | 26.41%     | 38    | 36.19      |
| Inverted comma          | 9  | 17.30%     | 9                                      | 16.98%     | 18    | 17.14      |
| Oval                    | 19                                       | 36.53%     | 30                                     | 56.60%     | 49    | 46.66      |

**Table-4. Frequency of various types of suprascapular notches.**

| Types of suprascapular notch | Right scapulae (n=52) | Percentage | Left scapulae (n=53) | Percentage | Total | Percentage |
|------------------------------|-----------------------|------------|----------------------|------------|-------|------------|
| I                            | 8                     | 15.38%     | 2                    | 3.77%      | 10    | 9.52%      |
| II                           | 14                    | 26.92%     | 13                   | 24.52%     | 27    | 25.71%     |
| III                          | 19                    | 36.53%     | 28                   | 52.83%     | 47    | 44.76%     |
| IV                           | 1                     | 1.92%      | 2                    | 3.77%      | 3     | 2.85%      |
| V                            | 10                    | 19.23%     | 8                    | 15.09%     | 18    | 17.14%     |

**Fig.1. Photographs showing morphological types of acromion process of scapulae.**



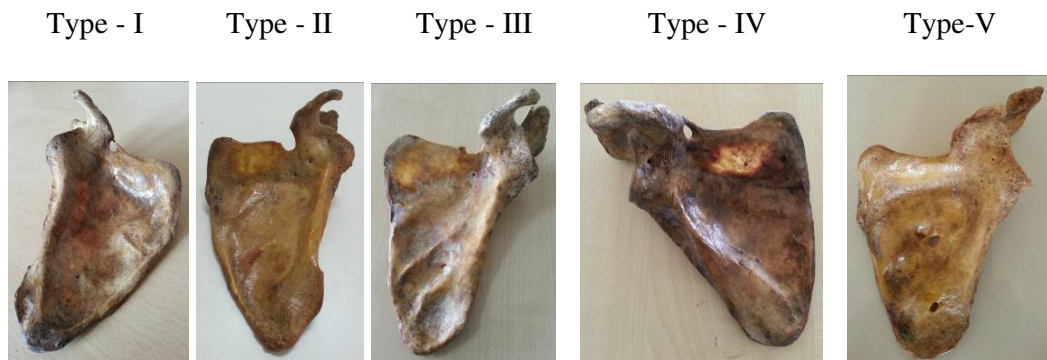
**Fig. 2. Photographs showing various shapes of acromion process of scapulae.**



**Fig. 3. Photographs showing various shapes of glenoid cavity of scapulae**



**Fig. IV. Photographs showing various types of suprascapular notches of scapulae.**



**Discussion:**

The variation of the acromion process has been studied by different authors. Biglani et al classified the acromion process into; type I-flat, type II-curved, type III-hooked.[10] In present study there was a higher frequency of type II acromion (48.57%). These results differs from Hirano M et al's studies, where higher frequency of type III and

type I acromion was noted. [11] Natsis K et al quoted that subacromial impingement syndrome and rotator cuff tears were more common in type III acromion, due to presence of enthesophytes. [12] The fourth type of acromion (Concave downward) was also introduced but it was not

recognised to an extent. [13] In present study, the higher frequency of quadrangular shaped acromion process noted in 47 (44.76%) scapulae.

In our study, 24 (46.15%) pear shaped glenoid cavity of right scapulae were found more common. While, 19 (36.53%) were found to be of oval shaped on same sided scapulae. In left scapulae, 30 (56.60%) were found to be more of oval shaped. Overall, 49 (46.66%) oval shaped glenoid cavities were more common in this study. According to Hina B's study, who had worked on 100 scapulae; 35% of the right and 39% of left glenoids were inverted comma shaped with a distinct notch. These results are varying with our South Indian scapular study. [14] The pear shaped glenoids were 49% on the right side and 46% on the left side with an indistinct notch. On the right side 16% were oval and on the left side 15% were oval without any recognisable notch. These results are closely related in right scapulae for pear shape and in left scapulae for oval shape. According to study of Coskun N et al on 90 scapulae, in 72% of the specimens, the glenoid notches of the scapulae were absent or oval shaped, whereas in 28% the notch was well expressed and the glenoid cavity was pear shaped.[15] Morphological study of Shrott et al on glenoid cavity has detected 85% ovoid glenoids and 15% inverted comma shaped glenoids in eighty shoulders, which is closely matching with the frequencies of inverted comma shape of South Indian scapulae. [16]

We followed Michael Polguy's classification for suprascapular notch. Accordingly, the commonest type of suprascapular notch in the present study was noted to be of type III- 47 (44.76%), while least common type suprascapular notch was of type IV- 3 (2.85%). Morphological variation of suprascapular notch was known to be one of the cause of suprascapular nerve entrapment .[17] Previously suprascapular notch was classified by

many researchers based on its geometric calculations. Six different types of anatomical variations including complete absence of suprascapular notch was quoted in Nigerian population.[18] Rengachary et al (1979) conducted a study of suprascapular notches in 211 cadaveric scapulae. Author classified it in six types. The said classification mainly focused on shape of suprascapular notch and ossification of superior transverse scapular ligament.[19] According to study of G. Soni et al, five different types of suprascapular notch were put forward with type II suprascapular notch were found more common.[20] In 2007, Nastis et al determined a new classification of suprascapular notches. It distinguished into its five types, as per its vertical and transverse diameter of the suprascapular notch and presence or absence of both suprascapular notch and suprascapular foramina.[21] As stated earlier, the present study followed Polguy's classification of suprascapular notch, and classified into its five different types. These morphological variations could be useful in further diagnosis and management of various clinical conditions including suprascapular nerve entrapment.

#### **Conclusion:**

In an observational study of South Indian scapulae, we found a higher percentage of type II acromion 51 (48.57%), Quadrangular acromion 47 (44.76%), Oval shaped glenoid cavity 49 (46.66%) and type III Suprascapular notch 47 (44.76%). This data may be used to compare South Indian scapulae with those of various other regions or with different races. Our findings can also contribute to demographic studies of shoulder disease in South Indian population. The anatomical morphological variations of the acromion and related structures of shoulder joint is of clinical importance. It is also useful for suitably interpreting the radiological images, during

surgical procedures and in pathologies associated with shoulder joint. This study will be helpful clinically in impingement syndrome and rotator cuff tear and also to know its prevalence with the various shapes of the acromion. Such type of study may also be useful for Orthopaedic surgeon in case of total shoulder arthroplasty and suprascapular nerve entrapment to avoid iatrogenic injuries to suprascapular nerve.

#### References:

1. Neil R Borley, Patricia Cullins, Alan R Crossman, Michael A Gatzoulis. Gray's Anatomy.40<sup>th</sup> edition. The anatomical basis of clinical practice. Editor in chief –Susan Standring. Section editors - Churchill Livingstone Elsevier Publication.
2. Collipal E, Silva H, Ortega L, Espinoza E, Martinez C. The acromion and his different forms. *Int. J. Morphol.*, 28(4):1189-1192, 2010.
3. Schetino L, Sousa Junior R, Amancio G, Schetino M, Almeida-Leite CM, Silva J. Anatomical variations of acromions in Brazilian adult's scapulas *J. Morphol. Sci.*, 2013, vol. 30, no. 2, p. 98-102.
4. Pahuja Kavita, Singh Jaskaran, Geeta. Morphology of coracoid process and glenoid cavity in adult human scapulae. *International Journal of Analytical, Pharmaceutical and Biomedical Sciences* Volume: 2: Issue-2: April-June-2013p.19to 22.
5. Mamtha T, Pai SR, Murlimanju BV, Kalthur SG, Pai MM, Kumar B. Morphometry of Glenoid Cavity. *Online J Health Allied Scs.* 2011; 10(3):7.
6. Shortt, Conor P, Morrisson, William B, Shah, Suken H, Zoga, Adam C, Carrino, John A. Association of glenoid morphology and anterosuperior labral variation. *Journal of computer assisted tomography.* Issue: vol. 33(4), July/August 2009, pp 584-586.
7. Jadhav S. D, Patil R J, Roy P P, Ambali M.P, Doshi M.M, Desai R.R. , Suprascapular foramina in Indian dry scapulae. *National journal of clinical Anatomy.* vol.1 (3). Page 133-135(2012).
8. . Dr. Vyas K.k., Dr. Rajput H. B, Dr. Zanzrukiya K. M,Dr. Suttarwala Ila,Dr. Sarvaiya Bharat J. Dr. Shroff Bhavesh D. Various dimensions of safe zone to prevent suprascapular nerve injury..*Indian Journal of Applied Basic Medical Sciences.*Vol.: 15a, Issue : 20 ,PP-27-39.(2013)
9. Polguy M, Jędrzejewski KS, Podgórski M, Topol M. , Correlation between morphometry of the suprascapular notch and anthropometric measurements of the scapula. *Folia Morphol (Warsz).* 2011 May; 70 (2):109-15.
10. Bigliani LU, Morrison DS, April EW. , The morphology of the acromion and rotator cuff impingement (abstr). *Orthop Trans.* 1986; 10:228.
11. Hirano M., Ide J. and Takagi K., Acromial shapes and extension of rotator cuff tears: magnetic resonance imaging evaluation. *Journal of Shoulder and Elbow Surgery*, 2002, vol. 11, n. 6, p. 576-8.
12. Natsis K, Tsikaras P, Totlis T, Gigis I, Skandalakis P, Appel HJ et.al. Correlation between the four types of acromion and the existence of enthesophytes: a study on 423 dried scapulas and review of the literature. *Clin Anat (Review).* 2007; 20: 267–272.
13. Farley T, Neumann C, Steinbach L, Petersen S. , The coracoacromial arch: MR evaluation and correlation with rotator cuff pathology. *Skeletal Radiol.* 1994; 23: 641–645.
14. Hina B Rajput1, Kintu K Vyas, Bhavesh D Shroff. , A study of morphological patterns of glenoid cavity of scapulae. *National Journal of research* Volume 2 (4) Oct – Dec 2012, 504.
15. Coskun N, Karaali K, Cevicol C, Demirel BM, Sindel M. , Anatomical basics and variations of the scapula in Turkish adults. *Saudi Med J.* 2006; 27(9):1320-5.

#### Acknowledgement:

We extend our sincere thanks to Dr. K.R. Arunkumar and Dr. S R Gosai of Department of Anatomy, Dhanalakshmi Sriivasan Medical College, Siruvachur (Tamilnadu), as well as the faculties of Anatomy department of Government TD Medical College Vandanam, Alapuzha (Kerala) for their kind co-operation.

16. Shortt, Conor P, Morrisson, William B, Shah, Suken H, Zoga, Adam C, Carrino, John A. Association of glenoid morphology and anterosuperior labral variation. *Journal of computer assisted tomography*. Issue: vol. 33(4), July/August 2009, pp584-586.
17. E Witvrouw, A Cools, R Lysens, D Cambier, G Vanderstraeten, J Victor, C Sneyers, M Walravens. Suprascapular neuropathy in volleyball players *Br J Sports Med* 2000;34:174–180
18. David A. Ofusori, Raymond A. Ude, Christina U. Okwuonu, Olamide A. Adesanya. Complete absence of the suprascapular notch in a Nigerian scapula: A possible cause of suprascapular nerve entrapment *Int J Shoulder Surg*. 2008 Oct-Dec; 2(4): 85–86.
19. Rengachary S, Burr D, Lucas S, Hassanein K, Mohn M, Matzke H. Suprascapular entrapment neuropathy: a clinical, anatomical, and comparative study. Part 1 : clinical study. *Neurosurgery*. 5: 441-446.
20. Soni G, Malik V S, Shukla L, Chhabra C, Gaur N. , Morphometric Analysis of the Suprascapular Notch. *The Internet Journal of Biological Anthropology*. 2012 Volume 5(1): 219
21. Natsis K, Totlis T, Tsikaras P, Apple HJ, Skandalakis P, Koebke J , Proposal for classification of the suprascapular notch: a study on 423 dried scapulas. *Clin Anat* (2007) 20:135- 139.