

Case report:

Variation of origin of left testicular artery- A case report

**Dr Saikat Kumar Dey¹, Dr. Pallab Kumar Saha², Dr. Anupam Baske³, Dr Parijat Mukherjee⁴,
Dr. Aradhana Sanga⁵, Dr.Purnendu Rang⁶, Dr. Sayongdeepa Roy⁷, Dr. Sudeshna Majumder⁸**

^{1,5}2nd Year Junior Resident, ²Assistant Professor, ^{3,6,7}3rd Year Junior Resident, ⁴1st Year Junior Resident, ⁸Professor & Head
Department of Anatomy, North Bengal Medical College & Hospital, Sushruta Nagar, Darjeeling, West Bengal, India

Corresponding author: Dr Saikat Kumar Dey

Abstract

Anatomy of testicular artery is very important for testicular as well as renal surgeries. In addition to the normal pattern of origin of the gonadal arteries from abdominal aorta, it may arise from renal arteries, suprarenal arteries and accessory renal arteries. During routine dissection of a male cadaver of 65 year old the left testicular artery arising from the left renal artery was found. In the literature origin of testicular artery from renal artery was found from 1.47% to 17%. Thus knowledge of this type of variation is very important in avoiding complications during abdominal surgeries.

Key words : Testicular artery, Renal artery, Mesonephric crest

Introduction

The testicular artery (internal spermatic artery) usually arises from the abdominal aorta, inferior to the origin of the renal artery, and courses infero-laterally under the parietal peritoneum, along psoas major, towards the pelvis. On the right, it courses anterior to the inferior vena cava and posterior to the middle colic and ileocolic arteries and terminal ileum. On the left, it courses posterior to the inferior mesenteric vein, left colic artery and descending colon. As the right and left testicular arteries enter the pelvis, they lie anterior to the genitofemoral nerves, ureters and external iliac arteries. Both arteries then enter the deep inguinal ring and travel with ipsilateral spermatic cord in the inguinal canal to the scrotum [1].

In the literature it has been found that there may be several other sites, in addition to the normal pattern, of origin of the gonadal arteries have been described; renal, accessory renal and suprarenal arteries are

most commonly mentioned (Lippert & Pabst et al., 1985)[2]; (Asala et al., 2001) [3]; (Cicekcibasi et al., 2002)[4]; (Bergman et al., 2006)[5]; (Petru et al., 2007) [6]; (Shoja et al., 2007) [7]; (Pai et al., 2008) [8] and more rarely the lumbar, common or internal iliac and superior epigastric arteries [2,5]; (Paraskevas et al., 2011) [9].

At embryonic stage there is presence of lateral splanchnic arteries which are branches of the dorsal aorta, persists bilaterally as testicular and three suprarenal arteries. With variations in the course of the testicular arteries there may be association of certain vascular and developmental anomalies of kidneys, as both of these organs embryologically developed from the intermediate mesoderm of mesonephric crest. Also the vasculature of kidneys and gonads are derived from the lateral mesonephric branches of dorsal aorta [10,11].

This kind of aberrant vasculature might be a challenge for the surgeon during surgery in this

region, though may be mostly undiagnosed throughout life. So pre operative aortography is often required to know the presence of abnormality. So the present case report aims together to explain the embryological basis of this congenital anomaly and also the risk associated during surgery in this region.

Case Report

During routine abdominal dissection of a male cadaver of 65 year old at North Bengal Medical College & Hospital for the undergraduate medical students of the session 2016-17, it was found that the

left testicular artery originated from the left renal artery. The testicular artery of other side originated from its normal position i.e. from the lateral branch of abdominal aorta just below the origin of right renal artery. Both sided renal vein were normal in draining i.e. left sided testicular vein drains into left renal vein and right sided testicular vein in inferior vena cava. On both side, there was no additional branch from abdominal aorta to the testes and also absence of any additional renal artery.

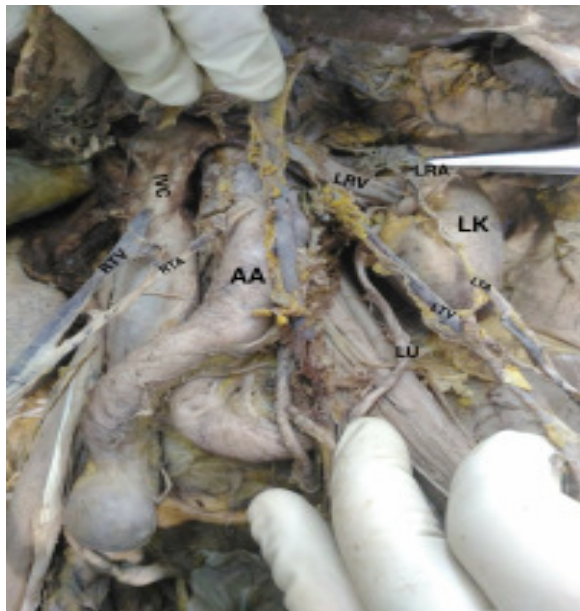


Fig.1 showing origin of testicular arteries of both side

LK- Left Kidney, LU- Left Ureter, LRA- Left Renal artery, LRV- Left Renal vein, LTA- Left Testicular artery, LTV- Left Testicular vein, AA- Abdominal Aorta, IVC- Inferior vena cava, RTA- Right Testicular artery, RTV- Right Testicular vein

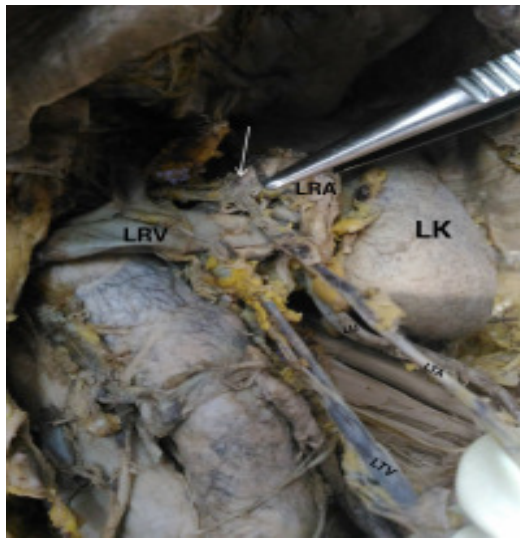


Fig. 2 showing the origin of left testicular artery (marked by arrow) fro left renal artery.



Fig.3 showing the origin of left testicular artery (marked by arrow) fro left renal artery.

Discussion

Congenital anomalies of the testicular arteries are common, may vary at the origin; one or both arteries may arise from renal, suprarenal or lumbar artery or may be missing, may be originated from a common trunk or be doubled, tripled or quadrupled [2]. High origin of gonadal arteries from abdominal aorta and origin of accessory left testicular artery from anterolateral wall of descending aorta described [12]. It was also noted that from the inferior polar artery of

kidney testicular artery originated [13]. Testicular arteries may arise from a common stem with suprarenal artery [14]. The normal pattern is followed in the 83% of cases according to the classical anatomical text books [2]. In the literature anomalies were in a range from 4.7 % (7/150) [3] to 75% (12/16) [6]. To be specific the gonadal arteries originating from main renal artery with a varying frequency of 1.47% (1/68)[8] to 17% [2] and from accessory renal artery ranges from 5.5% (5/90) [4] to

31.25% (5/16) [6]. The latter variety occurred bilaterally only in the 1.1% of the cases (1/90) [4]. The testicular arteries are more anomalous than ovarian arteries in respect of anomalous origin [4]. In a study data, collected from spontaneously aborted fetus and classification made on origin of gonadal arteries in following four types. ii)

Type I- origin from suprarenal artery [Rt-4.4%, Lt-iii) 1.1%]

Type II- origin from renal artery [Rt- 2.2%, Lt- 3.3%]

Type III- High positional origin from the abdominal aorta at the level of renal artery [Rt- 3.3%, Lt- 1.1%]

Type IV- Duplication of the testicular artery (3.3%). It is worth to mention that in type- II, the gonadal artery always originated from inferior polar arteries and not from the main one [4].

According to another literature the variation is as follows:-

Variation 1:- Testicular artery from inferior polar artery (T-5/68, R-3/34 L-2/34)

Variation 2:- Testicular artery from main renal artery (T-1/68, R-1 /68)

Variation 3:- High origin of testicular artery

Variation 4:- Double testicular artery

And all these variations coexisted with multiple renal vessels [8].

Cicekcibasi et al reported that the gonadal artery originated from inferior polar artery in (5/98) cases right and (2/98) cases left sided, whereas from upper polar artery the no. is (2/98) and only found in right side [4].

Embryological basis

There is definite embryological basis for the variation of renal and gonadal arteries. Both kidneys , suprarenal and gonads developed during embryonic

life from the intermediate mesoderm of mesonephric crest [4, 14]. So their blood supply was also from a common source, the lateral mesonephric branches of dorsal aorta. These were 9 pairs in nos. These can be divided into three groups,

1st and 2nd – cranial arteries

3rd to 5th - middle arteries

6th to 9th - caudal arteries.

If there is persistence of more than one middle artery, there will be multiple renal arteries. As embryo grows, kidney ascends and gonads descend. When the two organs cross, the testis receives two main branches, one above and one below the kidney. As the organs reach their final position the lower branch usually atrophies [13].

Felix [14] also stated that mainly caudal group of arteries give rise to gonadal arteries though may arise from any of the 9 arteries. Various growth/transcription factors and hemodynamic forces may determine about the selection and persistence of a particular congenital vascular channel, though the particular embryonic signal for this selection is yet to be found [15].

In our case report we found type-II variety as described by Cicekcibasi et al [4] of congenital anomaly where left testicular artery was arising from left renal artery.

Conclusion:

Now a days there are newer techniques for surgery. So during laparoscopic surgery of male abdomen and pelvis, there may be hazardous complication due to this kind of variable anatomy of renal and gonadal artery. So surgeons need to be careful to any vascular injury to gonads. Arteriography or Doppler ultrasound examination of renal hilum is important before surgery in this region.

It is worthy to mention that the increasing demand for living donor graft in renal transplantation, the knowledge of variant renal arteries and gonadal arteries is necessary. The knowledge regarding this

variation becomes very helpful when one has to manage the case of spontaneous retroperitoneal hemorrhage from aneurysm of adrenal artery.

Bibliography:

1. Standring S, editor-in-chief, Gray's Anatomy. The anatomical basis of clinical practice. In male reproductive system, vascular supply and lymphatic drainage. 41st edition, Elsevier; 2016; p-1272.
2. Lippert, H. & Pabst, R. *Arterial variations in man. Classification and frequency*. Munich, J. F. Bergmann, 1985.
3. Asala S, Chaudhary SC, Bidmos M. Anatomical variations in the human testicular blood vessels. *Ann Anat*. 2001; 183: 545–549
4. Cicekcibasi, A. E.; Salbacak, A.; Seker, M.; Ziyilan, T.; Büyükmumcu, M. & Uysal, I. I. The origin of gonadal arteries in human fetuses: anatomical variations. *Ann. Anat.*, 184(3):275-9, 2002.
5. Bergman RA et al., Human doubled renal and testicular arteries. *Anat. Anz* 1992; 174:313- 315.
6. Petru, B.; Elena, S.; Dan, I. & Constantin, D. The morphology and the surgical importance of the gonadal arteries originating from the renal artery. *Surg. Radiol. Anat.*, 29(5):367-71, 2007.
7. Shoja, M. M.; Tubbs, R. S.; Shakeri, A. B. & Oakes, W. J. Origins of the gonadal artery: embryologic implications. *Clin. Anat.*, 20(4):428-32, 2007.
9. Pai, M. M.; Vadgaonkar, R.; Rai, R.; Nayak, S. R.; Jiji, P. J.; Ranade, A.; Prabhu, L. V. & Madhyastha, S. A cadaveric study of the testicular artery in the South Indian population. *SingaporeMed.J.*, 49(7):551-5, 2008.
10. Paraskevas, G. K.; Ioannidis, O.; Raikos, A.; Papaziogas, B.; Natsis, K.; Spyridakis, I. & Kitsoulis, P. High origin of a testicular artery: a case report and review of the literature. *J. Med. CaseRep.*, 5:75, 2011
11. Williams PL, Bannister LH, Berry MM, Collins P, Dyson M, Dussek JE, Ferguson MW, eds. Gray's Anatomy. 38th Ed., Edingburg, Churchill Livingstone. 1995; 1558.
12. Moore KL, Dalley AF. Clinically oriented Anatomy. 5th Ed., Philadelphia, Lippincott Williams & Wilkins. 2006; 311, 384.
13. Ozan H et al. (1995) High origin of gonadal arteries associated with other variations. *Anat , Anz*. 1995; 177:156-160.
14. Ravery V et al. Variations in arterial blood supply and the risk of hemorrhage during percutaneous treatment of lesions of the pelviureteral junction obstruction: report of a case of testicular artery arising from an inferior polar renal artery. *Surg Radiol Anat*. 1993; 15:355-359.
15. Adachi, B. *Das Arteriensystem der Japaner II*. Kyoto und Tokyo, Maruzen Publishing Co., 1928.
16. Felix W Mesonephric arteries (aa mesophricae) In Kiebel F, Mall FP eds, Manual of human embryology Vol 2, Philadelphia, Lippincott 1912; 820-25.