

Case report:

Anomalous origin of the radial recurrent artery

Dr Banani Kundu, Dr Nabanita Chakraborty, Dr Soham hakraborty, Dr Alpna De

Name of the Institute/college: R G Kar Medical College & Hospitals , Kolkata 700 004

Corresponding author: Dr Banani Kundu

Abstract

The brachial artery begins at the distal border of teres major and ends about a centimetre below to the elbow joint at the level of the neck of the radius by dividing into the radial and the ulnar arteries. But in the present case an unusual variation in the branching pattern of the right brachial artery was observed. Here the brachial artery gave three terminal branches –the radial artery ,the ulnar artery and the radial recurrent artery just below the elbow joint .In this report we discuss the relevance of embryogenesis and clinical importance of such variation.

Key words – Brachial artery, Radial artery, Radial recurrent artery

Introduction

The axillary artery of the upper limb continues as the brachial artery at the lower border of teres major muscle. It descends downwards and then appears in the cubital fossa, where it ends at the level of the neck of the radius by dividing into the radial and the ulnar arteries. The artery is superficial throughout its course in the arm lying immediately deep to the deep fascia and is accompanied by a pair of venae comitantes. The brachial artery gives profundabrachii, superior ulnar collateral ,inferior ulnar collateral arteries ,muscular branches and two terminal branches i.e the radial artery and the ulnar artery.¹

Among these two terminal branches the radial artery passes inferolaterally resting on supinator and appears in front of the forearm through the apex of the cubital fossa. While in the fossa ,the radial artery gives a branch , the radial recurrent artery ,which ascends between the superficial and deep branches of the radial nerve and anastomoses with the radial collateral branch of arteria profunda brachii in front of the lateral epicondyle of the humerus.

Sometimes the artery divides proximally into two trunks ,which may reunite. Previous study done by Compendium of Human Anatomic Variations,² major variations are present in about 25% of the subjects studied for the brachial artery. The variation in the form of high proximal division into radial artery(15%),ulnar artery (2%) and common interosseousartery.

This high division may occur at any point in the normal course of the vessel, but it is more common in the middle third.

Sometimes the radial artery arises more proximally leaving a common trunk for ulnar and common interosseous artery³.The brachial artery is most commonly used for blood pressure measuring and to do arteriography of the different parts of the body.The pulsed doplersonography is done in the distal part of this artery.So the knowledge regarding the variation of the branching pattern of it is indispensable not only to the vascular surgeons but also to the radiologists for various imaging studies.

Aims and objectives

The origin , course, termination and branches of the major arteries of superior extremity were

studied in this case report to increase our knowledge regarding the possible variations which may be helpful not only to the clinicians but also to the radiologists.

Observations

These findings were observed during routine dissection of the upper limbs of both sides of a 63 year old adult male cadaver in the department of anatomy, R.G. Kar Medical College, Kolkata. The brachial artery present in right limb was divided into three branches – Radial, Ulnar and Radial recurrent arteries in the cubital fossa. The course of the Radial recurrent artery was traced and it was going towards the division of the deep and superficial branches of radial nerve. The subsequent course of other two arteries was normal. The brachial artery of the left side was also dissected but there was no such vascular anomalies.

Discussion

Arterial variation in the upper limb was very much common. It was first reported by Von Haller in 1813.^{4,5} This is mainly because of their multiple and plexiform sources, the temporal succession of emergence of principal arteries, anastomoses and periarterial networks and functional dominance followed by regression of some paths⁶. The early limb bud receives blood via 7th inter segmental arteries, which contribute to a primitive capillary plexus. At the tip of the limb bud there is a terminal plexus that is constantly renewed in a distal direction as the limb grows. This terminal plexus was separated from the outer ectodermal sleeve of the limb by an avascular zone of mesenchyme. This avascular zone contains an extracellular matrix consisting largely of hyaluronic acid. Thus ectodermal- mesenchymal interactions and extracellular matrix components are controlling the initial patterning of blood

vessels within the limb⁷. According to Arey and Jurjus there are six possible causes which may be responsible for this vascular anomalies. These are (a) the choice of unusual paths in the primitive vascular plexus, (b) the persistence of vessels which are normally obliterated, (c) the disappearance of vessels which are normally retained, (d) an incomplete development, (e) the fusion and absorption of parts which are normally distinct, (f) a combination of factors leading to an atypical pattern normally encountered. In our case also one of these above mentioned factors may play the role.

Several variations with regard to the origin and termination of the brachial artery have been reported by many earlier research workers. Treves and Rogers described a case where two arteries were present instead of one brachial artery. Among these two arteries one may be a) radial and ulnar and the other may be b) interosseous artery which was originated high up⁸.

Anomalies of the upper limb arterial tree are very much common. The occurrence rate of high origin of the radial artery is 3 to 15%, as reported by different authors. The parent trunk being axillary artery in 12.5%, proximal 1/3 of brachial artery in 62.5% and middle 1/3 of brachial artery in 25%⁹.

So it was important to mention that the normal vascular development and its pattern of distribution is influenced mainly by local hemodynamic factors. Altered hemodynamic environment may be responsible for different pattern of blood vessels.¹⁰

Conclusion

The vessels of the upper limb are very important for different kinds of diagnostic, analytical and therapeutic studies. So these variations are having practical importance for the radiologists, cardiologists, orthopaedic and vascular surgeons.

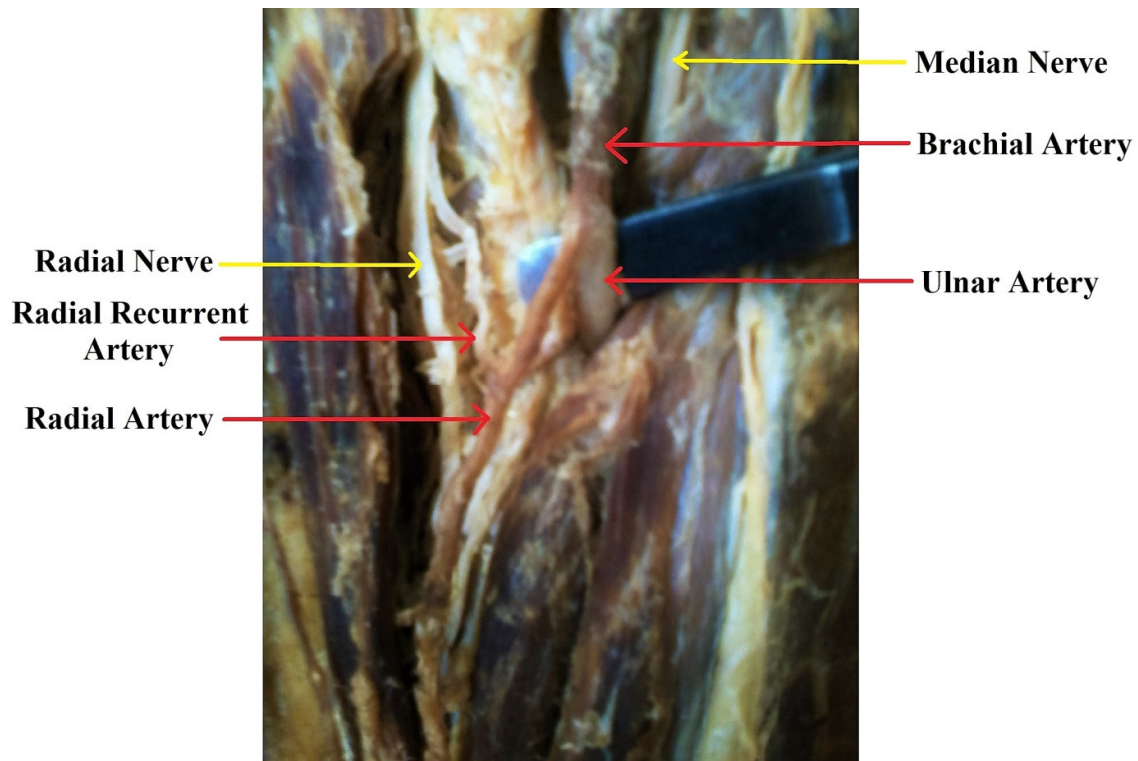


Figure:1

Trifurcation of Brachial Artery-Radial Artery ,Ulnar Artery and Radial Recurrent Artery

Acknowledgement:

The authors express their heartfelt gratitude to all the members of the Department of Anatomy, R GKar Medical College, Kolkata for their kind cooperation and generosity in the conduct of the study.

References:

- 1) Williams,Bannister,BerryMM,Collins P,Dussek JE,Ferguson MW,eds.Gray's Anatomy 38th edition,London,Churchill Livingstone.1999;319,1539
- 2) Bergman RA,Thompson SA,AfifiAK,Saadeh FA.Compendium of human anatomic variation .Baltimore:Urban&Schwarzenberg ;1988.
- 3) StandringS.Gray's anatomy:the anatomical basis of clinical practice.In:Upper arm Chapter 50.Spain:39thedn.2006;pp.856,Elsevier ChurchillLivingstone, New York.
- 4) BidarkotimathS, AvadhaniR, Kumar A. Primary pattern of arteries of upper limb with relevance to their variations.Int.J.Morphol.2011;29(4).p.1422-1428.
- 5) BidarkotimathS, Avadhani R, Kumar A. An anatomical study of primary pattern of arteries of upper limb with relevance to their variations.NUJHS.2012;2(1)p.08-14.
- 6) Williams PL, Bannister LH, Berry MM, Collins P,Dyson M, DussekJE, Ferguson MW, eds. Gray's Anatomy. 38th Ed., London, Churchill Livingstone.1999;319,1539.
- 7) Rodriguez-BaezaA,Nebot J,Ferreira B,Perez J,Sanudo JR,RoigM.An anatomical study andontogenic explanation of 23 cases with variations in the main pattern of the humanbrachio-antebrachialarteries.J Anat.1995;187:473-479.

- 8) Treves FB, Rogers L. In: The upper extremity. Surgical applied anatomy. 11th edn. 1947; pp. 230-231, Cassell & Co. Ltd. London.
- 9) Karlsson S, Niechajev IA (1982) Arterial Anatomy of the upper extremity. *Acta Radiologica* 23, 115-121.
- 10) Gonzalez-Compta X: Origin of the radial artery from the axillary artery and associated hand vascular anomalies. *Journal of Hand Surgery* 16A, 1991, 293-296.