

Case report

Non-rotated and incompletely ascended right kidney with varied vasculature and altered hilar anatomy- A rare case report

¹Dr. Dona Saha , ²Dr. Madhushree Pal

¹Demonstrator, Department of Anatomy, Nilratan Sircar Medical College, Kolkata – 700014, West Bengal, India.

²Demonstrator, Department of Anatomy, Nilratan Sircar Medical College, Kolkata – 700014, West Bengal

Corresponding author: Dr. Dona Saha

Abstract

Knowledge of the renal vascular anatomy may greatly contribute to the success of surgical, invasive and radiological procedures of the retroperitoneal region. Kidney, the excretory organs are supplied by right and left renal arteries at the level of second lumbar vertebrae. They are drained by right and left renal vein. During routine dissection of a 65 year male cadaver in the department of Anatomy, we observed a non-rotated and incompletely ascended right kidney with the hilum facing ventrally having a renal vein and pelvis of ureter emerging from the hilum. Right kidney was supplied by three arteries below the level of inferior mesenteric artery and that kidney was drained by two additional veins. These variations are due to persistence of embryonic vessels. Left kidney was normal. Though this type of variations is very rare, but proper knowledge is essential not only to the anatomists but also for the clinicians to perform radiological and surgical procedures more safely and efficiently.

Keywords: Kidney, Renal artery, Renal vein, non rotated kidney.

Introduction

Knowledge of the renal vascular anatomy may greatly contribute to the success of surgical, invasive and radiological procedures of the retroperitoneal region. Kidneys, the retro-peritoneal structure lies within the upper border of the 12th thoracic vertebra and the third lumbar vertebra, being the right is usually slightly inferior to the left. The anterior and posterior surfaces face anterolaterally and posteromedially, respectively. An appreciation of this orientation is important in percutaneous and endo-urolologic renal surgery. The inferior poles lie 2.5 cm above iliac crest. In each a deep vertical fissure opens anteromedially as the hilum, which contains the renal vein (anterior), the renal artery (intermediate) and the pelvis of the kidney (posterior). The paired renal arteries take about 20% of the cardiac output to supply organs that represent less than one-hundredth of total body

weight. They branch laterally from the aorta just below the origin of the superior mesenteric artery. A single renal artery to each kidney is present in approximately 70% of individuals. The arteries vary in their level of origin and in their calibre, obliquity and precise relations.¹ The accessory renal arteries supply renal hilum and aberrant (polar) ones are those which supply the kidney (poles) without passing through hilum. Satyapal (1995) has named any extra vein other than renal vein emerging out of kidney and draining separately in the Inferior Vena Cava as “additional” renal vein.² Knowledge of renal vascular variations is important in several conditions including renal trauma, renal transplantation, renovascular hypertension, renal artery embolization, angioplasty or vascular reconstruction in congenital and acquired lesions, abdominal aortic aneurysm

surgery, research and treatment concerning radical or conservative kidney surgery.³

Case report

During the routine dissection of a 65 year male cadaver in NRS Medical College and Hospital, Kolkata, an incompletely ascended and non-rotated right kidney was found in which 3 arteries were supplying and 3 veins were draining from it. Hilum of the right kidney faces anteriorly, retaining the embryonic position and the lower pole of right kidney remained below the iliac crest and reached at the level of first sacral vertebrae suggesting it as a abdomino-pelvic organ. (Fig: 1)

The 3 vein which were draining from kidney in the inferior vena cava were confined in the upper pole. First additional vein was located on the medial border in the upper pole, second vein was found in the upper part of hilum which may be described as renal vein and third vein, which was second additional vein was draining from the medial border at the level of middle of hilum. The pelvis of ureter in right side faced ventrally and emerged from the lower part of hilum in right kidney. (Fig: 1)

Among the 3 arteries which were supplying kidney, first aberrant artery was a direct branch of

abdominal aorta at the level of fourth lumbar vertebrae below the origin of inferior mesenteric artery and entered the kidney at the posterior surface close to medial border. Second aberrant renal artery was located at the medial border below the hilum and arose from the abdominal aorta at the level of bifurcation at lower border of fourth lumbar vertebrae. (Fig 2,3) Third aberrant renal artery was a branch from the right common iliac artery just above the formation of inferior vena cava at the level of body of fifth lumbar vertebrae. It wined round the posterior surface of right kidney and supply right kidney from the lateral border. (fig 3)

At the level of fourth lumbar vertebrae just below the origin of inferior mesenteric artery abdominal aorta overrides the inferior venacava and lies anterior to it. (fig: 3)

Left kidney was normal in position and have single renal artery and vein which are normal in position. Left renal artery arose laterally from the abdominal aorta below the origin of superior mesenteric artery. Left testicular vein drained in the left renal vein in right angle and right testicular vein drained in inferior venacava at an acute angle. (fig 1,3)

Indian Journal of Basic and Applied Medical Research

Is now with

IC Value 91.48

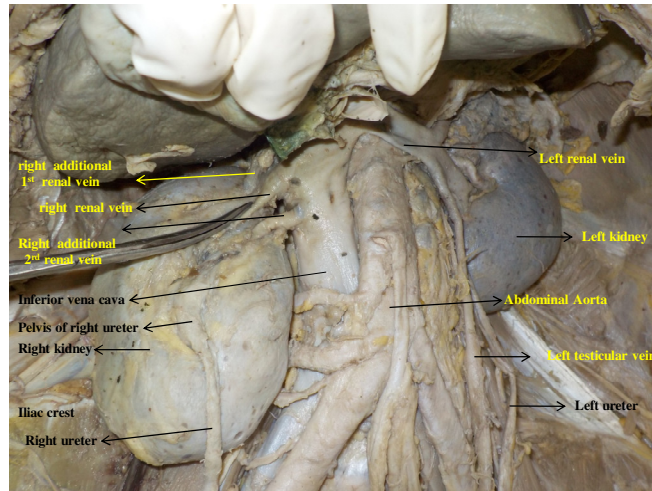


Figure 1: Non rotated right kidney, pelvis of right ureter facing ventrally. 3 veins from kidney draining into Inferior venacava. Lower pole of right kidney lies below the iliac crest. Normal left kidney .

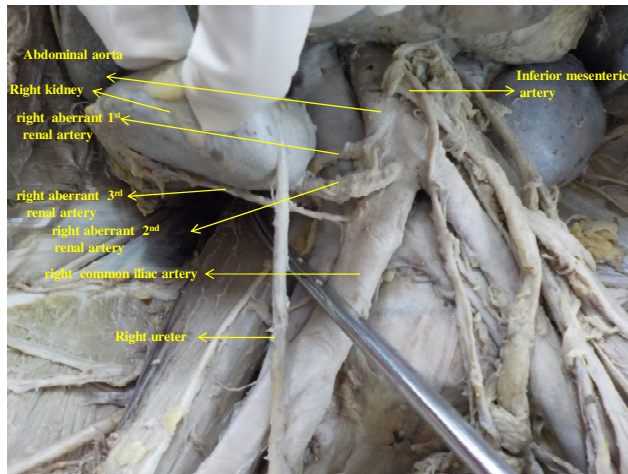


Figure 2: Right kidney with 3 aberrant renal arteries and third artery after originating from right common iliac artery winded round the posterior surface and supply from lateral border.

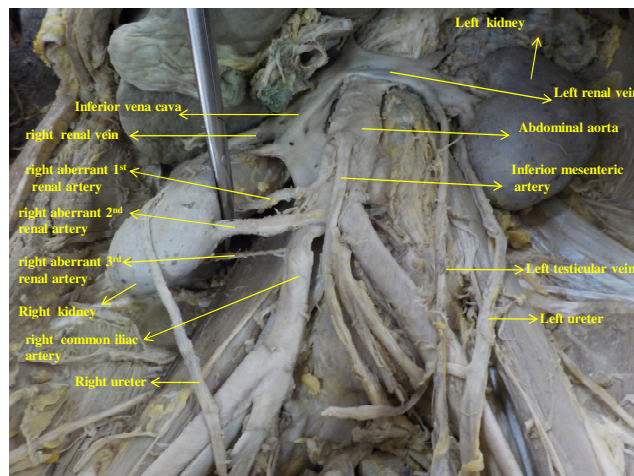


Figure 3: Non rotated right kidney with 3 aberrant renal arteries. Abdominal aorta in the lower part overrides the inferior venacava. Normal left kidney

Discussion

Clinicians should have a good knowledge of variations of renal vasculature as these are important in microvascular surgery, renal transplantation and pathogenesis of hydronephrosis. The different origins of renal arteries and frequent variations are explained by the development of mesonephric arteries. The

presence of an accessory/aberrant/abnormal renal artery at the lower pole is in fact a segmental vessel that is a persistent fetal vessel, with an abnormal origin.⁴

A single renal artery on one side and multiple (two, three, or four) renal arteries on the other is not unusual.⁵ The presence of accessory renal arteries can be explained embryologically as persistent

lateral splanchnic branches of abdominal aorta during ascent of kidney from groin to loin.⁶ The reported incidence of additional renal arteries has a wide range between 8.7% and 75.7%.⁷

Neelesh Kanaskar found that there were two additional renal arteries supplying the right kidney in addition to normal renal artery.⁸ Study of Patil ST showed renal pelvis was present anterior to renal vessel and malrotated right kidney showed lower lumbar position with three supplementary arteries and two vein.⁹ Pick and Anson found supernumerary arteries in 32.25% of kidneys but supernumerary veins in only 14.4%. They also reported bilateral extrahilar arteries in about 43% of cases.¹⁰ Gülsün et al reported a right pelvic kidney supplied by three arteries arising from bilateral common iliac arteries and from ipsilateral internal iliac artery.¹¹

In a study malrotation of both kidneys and a left lobulated ectopic kidney along with open hilum was observed. The left kidney showed a pelvic position in front of sacral promontory with three renal arteries retaining its embryological aortoiliac branches and two renal veins draining into right common iliac vein.¹² A study presented an additional inferior polar artery on the left side and an additional hilar renal artery on the right side with an accompanying additional renal vein associated with unrotated kidneys.¹³ Bergman et al. pointed that, the renal veins show less variation than do the renal arteries and multiple renal veins to be rare on the left side (1%) and common on the right side (28%).¹⁴

In human three successive kidney systems-pronephros, mesonephros and metanephros are formed in the intermediate mesoderm along with the capillary plexus in a cranial-to-caudal sequence during intrauterine life.¹ Embryological basis of the accessory renal arteries has been explained by Felix in an 18 mm fetus, the developing

mesonephros, metanephros, suprarenal glands and gonads are supplied by nine pair of lateral mesonephric arteries arising from the dorsal aorta. Felix divided these arteries into three groups as follows: 1st and 2nd arteries as the cranial, 3rd to 5th arteries as the middle and the 6th to 9th arteries as the caudal group. The middle group gives rise to the renal arteries. So the multiple renal arteries in our study are a result of persisting lateral mesonephric arteries of the middle group.¹⁵

With differential longitudinal growth of the lumbar and sacral region and the decrease in lumbar flexion of the embryo, the kidney "ascends" from its initial location in the pelvis to its final location in the upper retro peritoneum in between the end of 5th to the end of 8th week. During ascent, transient blood vessels serially arise from lower to higher level as lateral stem arteries from the dorsal aorta and degenerate until the proper renal arteries at the level of L2 is reached. Persistence of these arteries in lower level of abdominal aorta or from common iliac artery in the ectopic kidneys or unascended kidneys give rise to aberrant renal arteries.¹⁶ The ascent of kidneys is associated with concurrent rotation of kidneys around their vertical and horizontal axes, so that the hilum turns anteromedially from its ventral position and the upper pole lies more medial and anterior than the lower pole. Recent studies reveal that mutation of angiotensin type 2 receptor gene as a cause of kidney and urinary tract abnormalities.¹⁷

The formation of the renal vein is a complex process during embryologic development. On the medial aspect of each urogenital fold from longitudinal anastomoses of venous plexuses of rapidly growing mesonephros, subcardinal veins develop and they drain mainly the mesonephroi and the germinal epithelium and they terminate cranially and caudally in the corresponding posterior cardinal vein. Most of the right

subcardinal vein retained as the renal segment of inferior vena cava and the right renal vein which is a metanephric vein drains in the right subcardinal vein.¹⁵ The right subcardinal vein which during development received blood from mesonephros, may have persisted as extra communication, or there was an error on the fusion of the tributaries to the dorsal mesonephros derived from the right postcardinal vein and ventral branches of the right subcardinal vein giving rise to three veins which drained the right kidney in the present case.

So in our study, we got totally non-rotated and incompletely ascended right kidney with hilum facing ventrally and upper and lower poles in the same vertical line and persistence of primitive veins and lower lateral stem arteries.

Conclusion

These kind of multiple variations may remain silent clinically and unnoticed until discovered during operation, radiological investigation or during an autopsy. Variations in the origin and course of the

renal vasculature occur frequently and are of special interest to the urologist with respect to the disease associated with it and may cause systemic hypertension and urethral obstruction. With the advent of laparoscopic renal surgeries and donor nephrectomies, it becomes mandatory for the surgeon to assess for any abnormal position and rotation of kidney and variations in the renal vasculature before any surgical interventions. Therefore, considering the increase in incidence of abnormality in kidney and its vasculature the anatomical knowledge of such may be important for academic, surgical as well as radiological procedures and the present study is a humble effort to highlight the same.

Acknowledgement:

We are grateful to professor Dr. Hasi Dasgupta Head of Department of Anatomy of Nilratan Sircar Medical College, Kolkata, for cordial help regarding this case report.

References

1. Standring S, Healy JC, Collins P, Kidney and ureter. In: Gray's anatomy. The anatomical basis of clinical practice, 40th ed. Edinburgh, Churchill Livingstone Elsevier. 2008:1225-33.
2. Satyapal, K.S. Classification of drainage pattern of renal veins. J. Anat.1995; 186:329-33.
3. Fernandes RMP, Conte FHP, Favorito LA, Abidu-Figueiredo M, Babinski MA. Triple right renal vein: An uncommon variation. Int J Morphol 2005;23: 231-3.
4. Last RJ. Kidneys, ureters, and suprarenal gland. In: McMinn RM, editor. Last's Anatomy: Regional and Applied. 8th ed. Edinburgh: Churchill Livingstone; 1990. p.370.
5. Parimala NBS, Ratnaprabha CH, Prabhakara Rao M. Triple renal arteries and retro aortic left renal vein-A case report. National journal of clinical Anatomy. 2013; Vol 2(1) pp.38-40.
6. Subhra M, Prabir M, Ranjan B. Bilateral Accessory Renal Arteries, Additional Right Renal Vein and Retroaortic Left Renal Vein- A Case Report. International Journal of Health Sciences & Research. Vol. 3; Issue 2; February 2013; pp.88-89.
7. Necdet K, Bülent Y, Cenk K, Yalçın K, Hasan O. Accessory renal arteries and an anomalous testicular artery of high origin. Gülhane Týp Dergisi 2005; 47: pp. 141-143.
8. Neelesh K, Vaishali P, Jyoti K, Sapna S. Double Accessory Right Renal Arteries. Journal of Dental and Medical Sciences. Volume 1, Issue 5, Sep-Oct. 2012; pp.17-20.

9. Patil ST, Meshram MM, Kasote AP. Bilateral malrotation and lobulation of kidney with altered hilar anatomy: SRA, 2011; 33(10):941-4.
10. Anson B.J., Caudwell S.W., Pick J.W. and Beaton L.E.; Blood supply of kidney, suprarenal gland and associated structures, J. Anat 84:313, 1947.
11. Gülsün M., Balkancı F., Çekirge S., Deger A. Pelvic kidney with an unusual blood supply angiographic findings. Surgical and Radiologic Anatomy. 2000; 22(1):59–61. doi: 10.1007/s00276-000-0059-6.
12. Singh J, Singh N, Kapoor K, Sharma M. Bilateral malrotation and a congenital pelvic kidney with varied vasculature and altered hilar anatomy: Case Rep Med; 2015:848949. doi:10.1155/2015/848949.
13. Bayramoglu A, Demiryurek d, Erbil KM. Bilateral additional renal arteries and an additional right renal vein associated with unrotated kidneys: Saudi Med J 2003; Vol. 24 (5): 535-537.
14. Bergman RA, Thompson SA, Afifi AK, Saadeh FA, Compendium of Human Anatomic Variation, Urban & Schwarzenberg, Baltimore, Md, USA, 1988.
15. Felix W, Keibel F, Mall FP. Mesonephric arteries. In Manual of Human Embryology. Lippincott, Philadelphia, USA, 1912. (22):820-35.
16. Hamilton, Boyd, Mossman. Human Embryology, 4th Edition, The Macmillan Press Ltd, London and Basingstoke; 1972;391-2.
17. Moore KL, Persaud TVN, Torchia MG. Development of urinary system. In: The Developing Human. 9th ed. Philadelphia (PA): WB Saunders Company; Elsevier 2013. 247-55.