

Original article

Isolation of *Malassezia* yeast using Modified Dixon's Agar from Pityriasis versicolor lesions

¹Rathnapriya N, ²UshaKrishnan K, ³Janaki C, ⁴Sujatha Varadarajan, ⁵Shantha S

¹Assistant Professor, Institute of Microbiology, Madras Medical College, Chennai, Tamilnadu, India.

²Assistant Professor, Institute of Microbiology, Madras Medical College, Chennai, Tamilnadu.

³Former Professor of Dermatology, Madras Medical College, Chennai, Tamilnadu

⁴Deputy Director, King Institute of Preventive Medicine & Research, Guindy, Chennai.

⁵Former Director & Professor, Institute of Microbiology, Madras Medical College, Chennai.

Corresponding author: Dr.Rathnapriya.N.

Abstract:

Introduction: Pityriasis versicolor is one of the superficial fungal infections of the skin in which a pathogen is restricted to the stratum corneum. The causative organism of Pityriasis versicolor is the lipophilic yeast, of the genus *Malassezia*. *Malassezia* yeast gains more importance in recent times as it is associated with varied clinical spectrum of infections and its identification and culture plays a major role in the further understanding and treatment of fungal infections. Thus, this study was undertaken to evaluate the staining method and culture method for isolation of *Malassezia* spp.

Methods: This cross sectional study was conducted in the Institute of Microbiology, Madras Medical College, and the Mycology section of the Department of Dermatology, RGGGH, Chennai. From 112 outpatients with Pityriasis versicolor lesions, skin scrapings were collected and directly examined using Parker Quink's stain and Potassium hydroxide mount. Modified Dixon's Agar and Sabouraud Dextrose Agar (SDA) with Olive oil overlay were used for isolation of *Malassezia* yeast.

Observations & Results: Parker Quink's stain was found to be more useful in the identification of *Malassezia* yeast than Potassium hydroxide mount. Modified Dixon's Agar had higher isolation rate than SDA with Olive oil overlay for *Malassezia* yeast.

Conclusion: *Malassezia* yeast causes a wide range of infection from Pityriasis versicolor to fungemia in recent times. Therefore, to study the characteristics of *Malassezia* yeast, an ideal staining method like Parker Quink's stain and culture medium like Modified Dixon's Agar should be used for isolation of *Malassezia* yeast instead of the conventional methods.

Keywords: Pityriasis versicolor, *Malassezia* yeast, Modified Dixon's Agar

Introduction:

Superficial mycosis are by far the most common fungal infections in which a pathogen is restricted to the stratum corneum layer of the skin, with little or no tissue reaction. Pityriasis versicolor is one of the superficial fungal infections of the skin.¹

Pityriasis versicolor, also known as Tinea versicolor, is one of the most common pigmentary disorders worldwide.² In the United States, the name Tinea

versicolor is commonly used, whereas Pityriasis versicolor is the common name in Europe. The genus *Malassezia* was previously called *Pityrosporum*. The causative organism of Pityriasis versicolor is the lipophilic yeast, of the genus *Malassezia*. Clinically, patients with Pityriasis versicolor have scaly irregularly shaped macules and papules with brownish scales which may be hypopigmented or hyperpigmented, as implied by the name versicolor, they may appear yellowish to

brown, pale yellow or dark brown, occasionally reddish or pinkish in colour.²

The yeasts of the genus *Malassezia* have been associated with a number of diseases affecting the human skin such as Pityriasis versicolor, *Malassezia* (Pityrosporum) folliculitis, seborrheic dermatitis (dandruff), atopic dermatitis, psoriasis.³ *Malassezia spp.* also cause disseminated infections in infants and young children and even adults, who are receiving parenteral nutrition through indwelling catheters.^{4,5} The fungal agent, belonging to the genus *Malassezia*, which historically caused only superficial infections, is now an agent of disseminated infections in patients receiving parenteral therapy. Fungemia was reported as a complication of hyperalimentation in children and adults due to *Malassezia* yeast.⁶ In view of the wide spectrum of diseases caused by *Malassezia*, it was, therefore, felt necessary to evaluate the staining method and culture method for isolation of *Malassezia spp.*

Aims & Objectives:

1. To compare Parker Quink's stain with Potassium hydroxide mount for identification of *Malassezia* yeast in patients with Pityriasis versicolor.
2. To evaluate Modified Dixon's Agar for isolation of the *Malassezia* species.
3. To compare Modified Dixon's Agar and Sabouraud Dextrose Agar (SDA) with Olive oil overlay for isolation of *Malassezia spp.*

Material & Methods:

Study Design

This cross sectional study was done in the Institute of Microbiology, Madras Medical College, Chennai, Tamilnadu and the Mycology section of the Department of Dermatology, Rajiv Gandhi Government General Hospital (RGGGH), Chennai, Tamilnadu.

Study Population

The study group included both male and female outpatients of all age groups, who attended the mycology section of the Department of Dermatology, RGGGH with complaints of hypopigmented or hyperpigmented macular lesions. The skin scrapings were collected from 112 clinically diagnosed patients with Pityriasis versicolor. The study was proceeded after obtaining approval from the Institutional Ethics Committee.

Inclusion criteria

- a. All patients with Hypopigmented or Hyperpigmented macular lesions on the skin

Exclusion criteria

- a. Hypopigmented anaesthetic skin lesions with or without nerve involvement
- b. Patients with a history of application of topical steroids within past 7 days
- c. Patients with a history ingestion of systemic steroids within past 15 days
- d. Patients with a history of use of topical or oral antifungal agents within past 4 weeks

Sample Collection

Skin scrapings were collected under sterile precautions after thoroughly cleansing the skin with 70 percent ethyl alcohol, to remove the skin surface contaminants. The skin scrapings were collected by scraping the active edge of the hypopigmented or hyperpigmented macular skin lesion, using flame sterilized blunt 15 no. scalpel blade onto hot air oven sterilised two glass slides for evaluation of the staining methods and also in autoclaved filter papers and processed for isolation of *Malassezia* as per standard mycological procedures.⁷

Direct Microscopic Examination

Potassium Hydroxide Wet Mount

Skin scrapings were subjected to 10 percent Potassium Hydroxide wet mount, to detect the presence of yeast cells and hyphal elements.

A drop of 10 percent KOH was placed on the skin scrapings on a clean glass slide of size 2 inches length and 1 inch breadth and a clean coverslip was placed over it. The wet mount was examined after 15 to 20 minutes both under low and high power magnification of light microscope. The skin scrapings showing characteristic “spaghetti and meat balls” or “banana and grapes” appearance were identified in Pityriasis versicolor.⁷

Parker Quink’s Stain

Skin scrapings were also subjected to wet mount preparation using Parker Quink’s stain and examined for yeast cells and hyphal elements. Parker Quink’s stain is a mixture of 10 percent KOH and equal volume of Parker Quink’s permanent blue fountain pen ink. *Malassezia spp.* takes up the Parker Quink’s stain and appear light blue against the digested keratinocytes.⁸

Culture Characteristics

Growth requirement

Malassezia is a lipophilic fungus, therefore lipids are incorporated into culture media, which include Olive oil, glycerol monostearate and Tweens.

With the exception of *M.pachydermatis*, rest of the *Malassezia spp.* have an absolute requirement of medium or long chain fatty acids in the culture medium. Optimum temperature for incubation is between 32°C and 35°C.⁹

Observations & results:

Table 1: Type of lesion in patients with clinically diagnosed Pityriasis versicolor n=112

Type of skin lesion	No. of cases(%)
Hypopigmented	101 (90.2)
Hyperpigmented	11 (9.8)

Majority of the patients had hypopigmented lesions.(90.2%)

Culture

Skin scrapings were inoculated simultaneously onto two different culture media namely Modified Dixon’s Agar slants and Sabouraud Dextrose Agar slants with antibiotics and cycloheximide, overlaid with sterile Olive oil and incubated at 32°C and the slants were examined daily in the first week, then twice a week for next three weeks.¹⁰

Modified Dixon’s Agar -Composition

Mycological peptone-3g, Malt extract-30g, Dessicated Ox-bile-20g, Tween 40 -10ml, Glycerol-2ml, Agar-15g, Distilled Water-1L Final pH was adjusted to 6.0.¹¹

Colony Morphology

On Modified Dixon’s agar, cream to buff coloured colonies with smooth, convex surface was observed.⁷

Sabouraud Dextrose Agar

On SDA with cycloheximide and antibiotics, cream coloured colonies with smooth, flat or slightly convex surface was observed.⁷

Gram’s Stain

Gram’s stain was done for the colonies and found small, oval to spherical Gram positive budding yeast cells, 3-6µm in diameter. Hyphae were not seen in culture.⁷

Table 2: Direct Microscopic Examination of skin scrapings from Pityriasis versicolor lesions

n=112

Wet mount	Potassium Hydroxide	Parker Quink's Ink
Only yeast cells	8 (7.14%)	8 (7.14%)
Yeast cells & hyphae (banana & grapes appearance)	104 (92.86%)	104 (92.86%)

Both mounts found to be equally sensitive.

Table 3: Isolation rate of *Malassezia* fungus in patients with Pityriasis versicolor

n=104

Direct Microscopy	Culture on Modified Dixon's agar	
	Positive	Negative
104 Cases	66 (63.46%)	38 (36.54%)

Out of 104 Pityriasis versicolor patients, only 66(63.46%) were culture positive for *Malassezia* yeast.

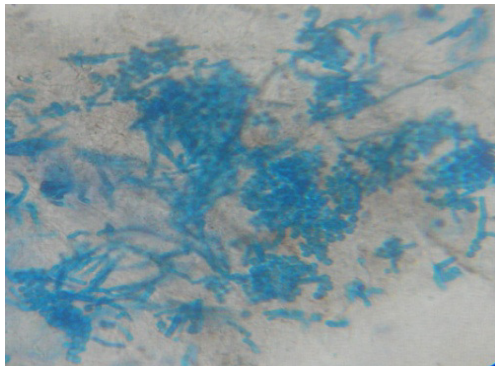
Table 4: Comparison of Modified Dixon's Agar with SDA with Olive oil overlay for isolation of *Malassezia* yeast

n=104

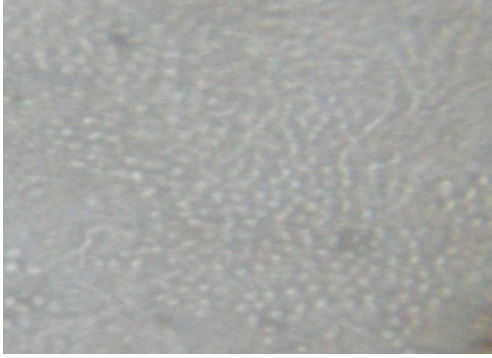
Culture media	Culture Positive %
Modified Dixon's Agar	66 (63.46)
SDA with Olive oil overlay	58 (55.77)

Modified Dixon's Agar had 7.69% higher isolation rates than SDA with Olive oil overlay.

Figure(1)Parker Quink's Ink stain showing the characteristic "spaghetti and meat balls" or "banana and grapes" appearance

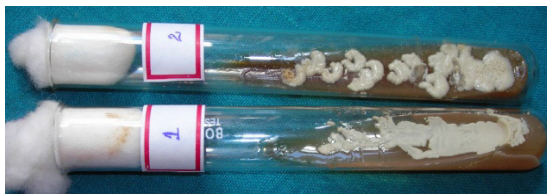

Figure(2)KOH mount from Pityriasis versicolor skin lesions

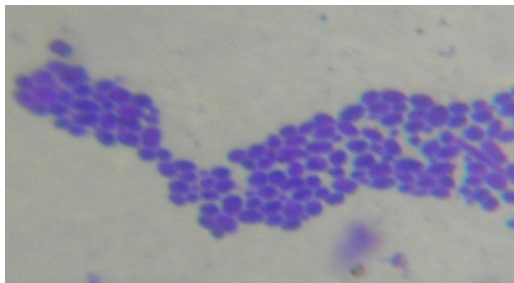


Figure(3) Malassezia Culture as seen in

- 1- SDA with Olive oil overlay
- 2- Modified Dixon's Agar



Figure(4) Gram stain from Culture media showing *Malassezia* yeast



Discussion:

In the present study, among the 112 outpatients clinically diagnosed with Pityriasis versicolor, 101 (90.2%) patients presented with hypopigmented lesions. (Table. 1). This study correlated with Gupta AK, *et al*, 2003,¹² in which hypopigmented lesions were more common and were particularly noticed in dark skinned individuals and sometimes, both hypopigmented and hyperpigmented lesions may coexist. Sunenshine PJ, *et al*, 1998,¹³ identified that most patients with Pityriasis versicolor were distressed by their alteration of skin colour rather than associated symptoms.

In the present study, direct microscopic examination of the skin scrapings from patients with Pityriasis versicolor showed the characteristic “spaghetti and meatballs” appearance in 104 patients (92.86%), under 10% potassium hydroxide mount Figure(2) and Parker Quink’s Ink stain. Figure(1)

Direct microscopic examination of the skin scrapings showed only yeast cells, in 8 cases (7.14%) with Pityriasis versicolor, under both the potassium hydroxide and Parker Quink’s Ink mounts. All patients showed similar findings in both potassium hydroxide and Parker Quink’s ink mounts. Therefore, both methods of direct

microscopic examination of skin scrapings were found to be equally sensitive for diagnosing Pityriasis versicolor. (Table 2) Xiong L, *et al*, 2004,¹⁵ showed that both *Malassezia spp.* and *Candida spp* could be stained by methylene blue, but only *Malassezia spp* could be stained by Parker Quink ink. Therefore, Parker Quink ink was found to be more specific for staining *Malassezia spp.*

Parker Quink's stain was found to be more useful for easier identification of the fungal elements than potassium hydroxide mount. In potassium hydroxide mount, as it is an unstained preparation, it needs practice and skill to identify the fungal elements with in the epithelial cell debris in the skin scrapings. To avoid confusion with artifacts in the potassium hydroxide mount and to help in correct identification, another staining method using Parker Quink's stain was found to be necessary for confirmation of fungal elements in direct examination of skin scrapings.¹⁶ In the present study, all of the 8 cases (7.14%) of Pityriasis versicolor showing only yeast cells in direct microscopic examination, gave a past history of topical application of antifungal preparation 4 weeks prior to reporting to the outpatient clinic and were complaining about persistence of the lesion. The application of antifungal agent might have resulted in the disappearance of the mycelial phase of *Malassezia* yeast.

The reason for the persistence of lesions, even after the treatment was found to be due to the metabolites of *Malassezia* species such as azelaic acid, a dicarboxylic acid, which causes hypopigmentation by injuring melanocytes. Hypopigmented lesions persist for months and some persist for years, due to the long-standing damage to melanocytes. The other reason might be that patients were more concerned about the alteration of their skin colour, for cosmetic reasons and therefore, visited the tertiary care hospital, even after treatment with

topical antifungal preparations.¹⁷ In the present study, out of 104 (92.86%) cases diagnosed as Pityriasis versicolor by potassium hydroxide mount and Parker Quink's stain, only 66 (63.46%) were culture positive for *Malassezia spp.* on Modified Dixon's Agar. (Table. 3)

The present study correlated with the study conducted by Dutta S, *et al*, 2001,¹⁸ at Allahabad, on 427 Pityriasis versicolor patients, in which only 250 (58.56%) were culture positive for *Malassezia* fungus on Modified Dixon's Agar.

In the present study, out of 104 direct microscopy positive samples 66 (63.46%) were culture positive on Modified Dixon's Agar and 58 (55.77%) grew on Sabouraud Dextrose Agar with Olive oil overlay. All cultures were confirmed by doing Gram's stain and Christensen's urease test. Gram's stain showed small, oval budding yeast cells without hyphae or pseudohyphae (Figure (4)) and all cultures hydrolysed urea, which is not so with *Candida* species. On comparison of both the culture media, Modified Dixon's agar had 7.69% higher isolation rates than the conventional Sabouraud Dextrose Agar with Olive oil overlay. (Table 4). Modified Dixon's Agar has malt extract and desiccated oxbile which provides nutrients which enable better growth of *Malassezia* yeast and hence colonies are larger and more prominent than in SDA with olive oil overlay. (Figure(3))

Another draw back in the conventional media was that the oil overlaid was a hindrance for the identification of colony morphology, which was overcome by incorporating the ingredients required for growth of the fastidious fungus in the Modified Dixon's agar itself.⁷ Desiccated oxbile, Olive oil, glycerol and Tween 40 were incorporated in the Modified Dixon's Agar which provide substantial growth of *Malassezia spp.*⁷

Conclusion:

In the present study, it was concluded that Pityriasis versicolor mostly presented clinically as hypopigmented lesions. Parker Quink's ink mounts was found to be more useful as it was easier to identify the *Malassezia* yeast on direct microscopic examination of skin

scrapings. Modified Dixon's Agar showed higher isolation rate than the conventional Sabouraud Dextrose Agar with Olive oil overlay. Therefore, Modified Dixon's Agar was found to be more useful for culturing *Malassezia* yeast from skin lesions in patients with Pityriasis versicolor.

References

1. Rook's Textbook of Dermatology, 7th edition, volume II, Blackwell Publishing Co., chapter 31, 2004: 5-15.
2. Schwartz RA. Superficial fungal infections. *Lancet* 2004; 364: 1173-1182.
3. Gupta AK, Batra R, Bluhm R, *et al.* Skin diseases associated with *Malassezia* species. *J Am Acad Dermatol* 2004; 51 s1: 785-798.
4. Koneman's Color Atlas and Textbook of Diagnostic Microbiology, 6th edition, chapter 17, Lippincott Williams & Wilkins, 2006: 945-1021.
5. Marcon MJ, Powell DA, Durrell DE. Methods for optimal recovery of *Malassezia furfur* from blood culture. *J Clin Microbiol* 1986; 24: 696-700.
6. Danker WM, Spector SA, *et al.* *Malassezia* fungemia in neonates and adults: Complication of hyperalimentation. *Rev Infect Dis* 1987; 9(4): 743-53.
7. Midgley G, Guého E, Guillot J. Diseases caused by *Malassezia* species. Topley and Wilson, 9th edition, volume 4, chapter 12: 201-211.
8. Cohen MM. A simple procedure for staining tinea versicolor with fountain pen ink. *J Invest Dermatol* 1954; 22: 9-10.
9. Murray PR, Rosenthal KS, Pfaller MA, Medical Microbiology 5th edition, Opportunistic mycoses. chapter 75: 789-791.
10. Kindo AJ, Sophia SKC, Kalyani J, Anandan S. Identification of *Malassezia* species. *IJMM* 2004; 22(3): 179 -181.
11. Woodgyer A.: *Malassezia* update, *Mycoses Newsletter*, Aug 2004.
12. Gupta AK, Batra R, Bluhm R, Faergemann J. Pityriasis versicolor. *Dermatol Clin* 2003; 21: 413-429.
13. Sunenshine PJ, Schwartz RA, Janniger CK. Tinea versicolor. *Int J Dermatol* 1998; 37(9): 648-655.
14. Mathes BM, Douglas MC. Seborrheic Dermatitis in patients with AIDS. *J Am Acad Dermatol* 1985; 13: 947-951.
15. Xiong L, *et al.* Application of methylene blue staining in detection of *Malassezia*. *Sichuan Da Xue Xue Bao Yi Xue Ban* 2004; 35(2): 277-9.
16. Jagdish Chander Textbook of Medical Mycology, 2nd edition, Mehta Publishers, section II, chapter 7, 2002: 70-79.
17. Nazarro Porro M, Passi SJ. Identification of tyrosinase inhibitors in cultures of *Pityrosporum*. *J Invest Dermatol* 1978; 71: 205-208.
18. Dutta S, Bajaj AK, Anupam Dikshit. Pityriasis versicolor: Socioeconomic and clinico - mycologic study in India. *Int J Dermatol* 2002; 41:7-12.