

Case Report:

Glycogen rich Clear cell carcinoma of the breast: A rare breast carcinoma subtype- case report

Bhaskar m¹, Vijith Shetty²

¹Junior Resident, Department of General Surgery, K S Hegde Medical Academy, Mangalore, Karnataka, India

bhaskar.mallaiah@gmail.com

²Consultant Medical Oncologist, Department of Radiation and Medical Oncology, K.S.Hedge Medical Academy, Mangalore, Karnataka, India

drvijithshetty@gmail.com



Abstract:

Background: Glycogen-rich clear cell breast carcinoma is a rare histological breast cancer subtype. Its prognosis may vary depending on specific clinical and pathological characteristics such as low grade, strong positivity of estrogen receptor (ER) expression and early diagnosis.

Case Presentation: We present the case of a 48 year old woman with a 10 x 08 cm diameter mass in the right breast with palpable right axillary lymph node. The histological examination showed a poorly differentiated tumor with malignant cells characterized by abundant clear cytoplasm Her2-neu enriched type. The diagnosis of clear cell carcinoma was based on the histological characteristics of the tumor. Immunophenotyping report showed ER-negative, PR-negative, her2-neu positive 3+, Ki67-10%. whole body bone scan showed areas of increased uptake over right iliac bone near sacro-iliac joint and over right acetabulum. patient is currently received 4 cycles of palliative chemotherapy with TAC regime.

Conclusions: Glycogen-rich clear cell carcinoma of the breast is a rare tumor. Early diagnosis, absence of lymph node metastases and ER/PR positivity are associated with a better prognosis, as in other common breast cancer subtypes.

Keywords: breast cancer, glycogen rich clear cell carcinoma.

1. Introduction

Glycogen Rich Clear Cell Carcinoma (GRCCC) is a rare variant of the breast carcinoma with incidence calculated to be 1.4 to 3%.⁽¹⁾ At least 90% of the neoplastic Cells of GRCCC have abundant clear cytoplasm containing glycogen. Minor component of eosinophilic granular cytoplasm may be present which suggest apocrine differentiation. Scant amount of mucin may be seen in some cases. Growth pattern is usually that of usual infiltrating ductal carcinoma. Other patterns may be lobular, tubular and medullary type. Intraductal clear cell component may be present. These tumors are PAS positive, diastase sensitive and fat stain negative. Immunohistochemical staining of the tumor cells are variably positive for cytokeratin, progesterone receptors, gross cystic disease fluid protein -15 (GCDFP15), neuron specific enolase, chromogranin and S100 protein and negative for estrogen receptor, smooth muscle actin, CD31 and CD34.⁽²⁻⁶⁾ Glycogen-rich clear cell mammary malignant

myoepithelioma is a variant of GRCCC which shows coexpression of vimentin, smooth muscle actin, epithelial membrane antigen, S-100 protein and cytokeratin as evidence of myoepithelial cell tumor.

2. Case Report

A 48yr old female patient presented with 1year history of a lump in right breast. On examination 10x8cm lump was palpable occupying the upper and lower outer quadrant, fixed to skin with peau de-orange, in central group Right side-axillary lymphnodes palpable.clinically T4b N1 Mx Trucut biopsy from the lesion showed glycogen rich clear cell carcinoma of breast Her2-neu enriched type.

Immunophenotyping report showed ER-negative,PR-negative, her2-neu positive 3+,
Ki67-10%

CECT thorax and abdomen pelvis showed no features of metastasis to liver,lung.however whole body bone scan showed areas of increased uptake over right iliac bone near sacro-iliac joint and over right acetabulum for which patient is currently received 4cycles of palliative chemotherapy with TAC regime.

Inj.TRASTUZUMAB was differed as patient was not willing for the same.

Discussion

Glycogen-rich clear cell carcinoma (GRCCC) of the breast is a tumor subtype with a distinct morphology different from common breast cancers. The first case of GRCCC was re-reported by Hull et al. [2] in 1981. In GRCCC, >90% of the neoplastic cells are polygonal with abundant clear cytoplasm, containing glycogen. The histological structure usually resembles ductal carcinoma, but lobular, tubular and mixed ductal-tubular features have also been reported [3–5]. Pure intraductal GRCCC is very rare [6]. GRCCC may form solid and papillary structures [7]. Clear cell breast carcinoma can be easily missed or misdiagnosed in a breast core biopsy specimen because it tends to show a papillary pattern with clear cell and pseudolactating changes, especially in young female patients [8]. Normal breast tissue may include clear cells as a consequence of physiological changes during pregnancy, and a clear cytoplasm may be found in myoepithelial cells and/or apocrine metaplasia.

Clear cell carcinoma of the breast accounts for 1.4–3% of all breast tumors [7, 9] and it is seen commonly in 5th decade of life [10]. The tumor size usually ranges from 1 to 6.5 cm; in our case, the clinical mass measured 10 x 8 cms [11]. The tumor growth period in the breast before clinical diagnosis may vary between 2 months and 2 years [6]. There are no sufficient published data about the imaging characteristics of GRCCC. Mammography may be inconclusive in case of a dense breast; however, MRI is important in pre-operative patient evaluation and surgical planning [6].

A differential diagnosis of GRCCC includes secretory carcinoma, lipid-rich carcinoma, apocrine carcinoma and mucinous carcinoma [1]. Primary GRCCC may also arise in the lung, endometrium, salivary gland, cervix and kidney [12]. It is therefore mandatory to discriminate between a breast primary and a breast metastasis, especially in case of a renal clear cell carcinoma.

In the series of Kuroda et al. [10] (20 cases, the majority with small tumor sizes), ER and PR positivity was less than in other breast cancer subtypes (ER and PR positive in 35 and 30% of the cells, respectively, as compared with 65 and 35% in invasive ductal carcinomas). No significant correlation was found between histological type and HER2 status (HER2 positivity in 20% of GRCCC and 31% of the other invasive carcinoma subtypes). In this series, lymph

node metastases were detected in 7 out of 20 cases, but more small-sized carcinomas were present than in a previous series. In 28 patients reported on in 2014 by Ma et al. [13], ER and PR were positive in 61% of the cases, and HER2 was positive in 12%. According to the molecular subtypes, 56% of the patients were luminal A, 12% were luminal B, and 32% were triple negative.

Because of the rarity of this disease (<150 cases reported so far), it is difficult to define a prognosis of GRCCC. A poor prognosis was reported in a small Finnish series (6 cases) [14], in which 80% of the patients had axillary metastases at diagnosis and died within 7 years. This outcome is in contrast with earlier reports, in which GRCCC showed a better prognosis [9]. Hayes et al. [15] published 21 cases of breast GRCC and suggested the prognosis is not different from that of other common breast cancers when tumors were matched by size, grade and lymph node status, as confirmed by other authors [5, 14]. In the series of Ma et al. [13], follow-up data were available for 24 patients: 21 women were disease free, and 3 cases had local recurrences or distant metastases. The median overall survival was 56.5 months. The number of positive nodes at diagnosis was significantly related to the risk of local or distant disease relapse. When compared to controls in their database (matched by age, year of diagnosis, tumor size, nodal status and phenotype), the authors found that overall survival and disease-free survival were not significantly different between GRCCC and control cases. In this series, a high proportion of carcinomas were ER and PR positive.

To better clarify the specific characteristics and prognosis of breast GRCCC and improve treatment strategies and outcomes, systematic study of a large number of cases with long-term follow-up will be of paramount importance.

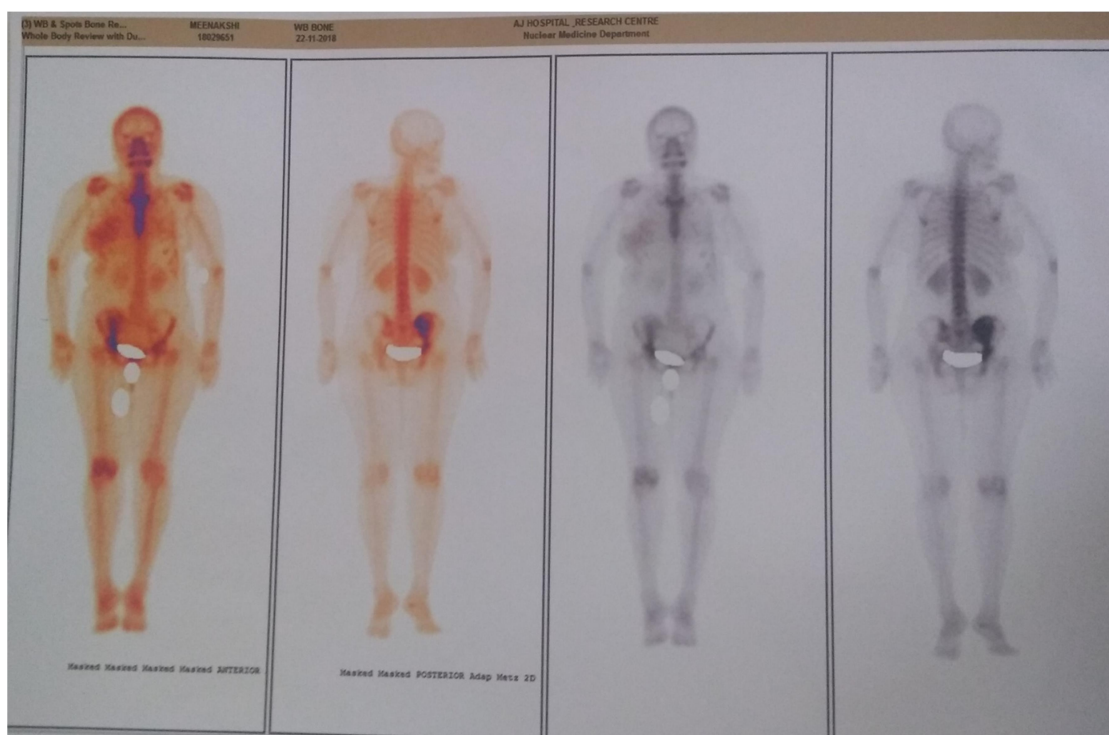


Fig 1. Whole body Bone scan showing areas of increased uptake over the right iliac bone near sacro iliac joint and over right acetabulum

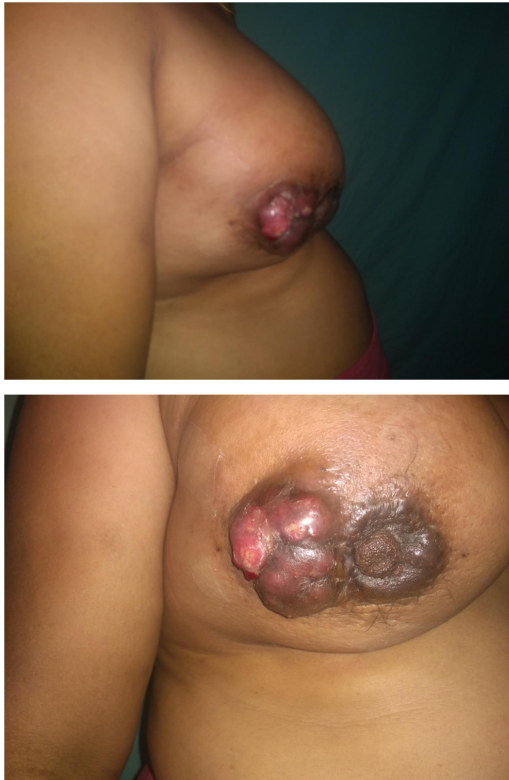

Fig 2, 3 : clinical photograph of the tumor

Reference:

- 1 Yerushalmi R, Hayes MM, Gelmon A: Breast carcinoma – rare types: review of the literature. *Ann Oncol* 2009;20:1763–1770.
- 2 Hull MT, Priest JB, Broadie TA, et al: Glycogen-rich clear cell carcinoma of the breast: a light and electron microscopic study. *Cancer* 1981;48:2003–2009.
- 3 Di Tommaso L, Pasquinelli G, et al: Glycogen-rich clear-cell breast carcinoma with neuroendocrine differentiation features (in Italian). *Pathologica* 2001;93:676–680.
- 4 Malla S, Shakya G, et al: Glycogen rich clear cell carcinoma of breast. *J Nepal Health Res Conc* 2008;6: 117–119.
- 5 Markopoulos C, Mantas D, et al: Glycogen-rich clear cell carcinoma of the breast. *World J Surg Oncol* 2008;6:44.
- 6 Salemis NS: Intraductal glycogen-rich clear cell carcinoma of the breast: a rare presentation and review of the literature. *Breast Care* 2012;7:319–321.
- 7 Gürbüz Y, Özkara SK: Clear cell carcinoma of the breast with solid papillary pattern: a case report with immunohistochemical profile. *J Clin Pathol* 2003;56:552–554.
- 8 Ovanez C, Crawford J, et al: Invasive ductal carcinoma of the breast with clear cell and pseudo-lactating changes. *J Surg Case Rep* 2014;2014:rju063.
- 9 Hull MT, Warfel KA: Glycogen-rich clear cell carcinomas of the breast. A clinicopathologic and ultrastructural study. *Am J Surg Pathol* 1986;10:553–559.
- 10 Kuroda H, Sakamoto G, Ohnisi K, Itoyama S: Clinical and pathological features of glycogen-rich clear cell carcinoma of the

breast. Breast Cancer 2005;12:189–195.

11 Martín-Martín B, Berná-Serna, et al: An unusual case of locally advanced glycogen-rich clear cell carcinoma of the breast. Case Rep Oncol 2011;4:452–457.

12 Botticelli A, De Francesco GP, Di Stefano D: Breast metastasis from clear cell renal cell carcinoma. J Ultrasound 2013;16:127–130.

13 Ma X, Han Y, et al: Clinicopathologic characteristics and prognosis of glycogen-rich clear cell carcinoma of the breast. Breast J 2014;20:166–173.

14 Toikkanen S, Joensuu H: Glycogen-rich clear cell carcinoma of the breast: a clinicopathologic and flow cytometric study. Hum Pathol 1991;22:81–83.

15 Hayes MM, Seidman JD, Ashton MA: Glycogen-rich clear cell carcinoma of the breast. A clinicopathologic study of 21 cases. Am J Surg Pathol 1995;19:904–911.

Author Declaration: Source of support: Nil, Conflict of interest: Nil

Was informed consent obtained from the subjects involved in the study? YES

For any images presented appropriate consent has been obtained from the subjects: NA

Plagiarism Checked: Urkund Software

Author work published under a Creative Commons Attribution 4.0 International License

DOI: 10.36848/IJBAMR/2020/29215.55890



Creative Commons Attribution
4.0 International License

CC BY 4.0