

Original article:

Comparative study between Novel Pull Through Technique with Jaboulay's procedure for Primary Vaginal Hydrocele" at Acharya Vinobha Bhave Rural Hospital, Sawangi (Meghe), Wardha

*Dr Akansha Dubey¹, Dr Y.R.Lamtur²

¹Department of Surgery, Jawaharlal Nehru Medical College, Wardha, Maharashtra, India

²Department of Surgery, Jawaharlal Nehru Medical College, Wardha, Maharashtra, India

Corresponding author*

Abstract

A hydrocele is a fluid collection within the tunica vaginalis of the scrotum or along the spermatic cord¹. These fluid collections may represent persistent developmental connections along the spermatic cord or an imbalance of fluid production versus absorption. There are different types of hydrocele, in which, primary vaginal hydrocele is the most common among these. There are different surgical procedures for hydrocele with some or the other limitations. In our study we compared a new novel pull through technique with Jaboulay's procedure for primary vaginal hydrocele in terms of postoperative complications like haematoma, infections, intraoperative blood loss, duration of surgery, postoperative time, postoperative tolerance of pain and recurrence.

Keywords: primary vaginal hydrocele, Jaboulay's procedure, novel pull through technique.

Introduction

A hydrocele is a fluid collection within the tunica vaginalis of the scrotum or along the spermatic cord¹. These fluid collections may represent persistent developmental connections along the spermatic cord or an imbalance of fluid production versus absorption. In rare cases, similar fluid collections can develop in females along the canal of Nuck due to failure of obliteration of the distal portion of evaginated parietal peritoneum within the inguinal canal which forms a sac containing fluid².

Hydrocele is the most common benign swelling of the scrotum and has been estimated to occur in as many as 1% of the adult male population and it usually appears in middle aged or elderly men³. A hydrocele usually is not painful and harmful and may disappear without treatment within the first year of life. It usually develops in hot climate^{4,5}.

Hydrocele can get complicated like rupture, calcification, haematocele, pyocele because of negligence, and it needs immediate hydrocelectomy^{4,6}.

Patients with primary vaginal hydrocele presented with painless scrotal swelling and some of them had pain and difficulty in walking. Hydroceles are typically translucent and it is possible to 'get above the swelling' on examination of the scrotum. Diagnosis of hydrocele is always clinical by taking thorough history, clinical assessment, examination like transillumination and fluctuation test and when transillumination is negative one should do ultrasonography of scrotum to rule out the underlying pathology or secondary hydrocele.

Indication for treating a hydrocele include pain, the cosmetic appearance of the scrotum, or the patient's preference and complications of hydrocele. The conservative management of a

hydrocele includes observation, aspiration, and sclerotherapy^{7,8,9}

In this study we will be comparing our new novel pull through technique with Jaboulay's procedure for primary vaginal hydrocele and this will be beneficial for our college use and the patients suffering from hydrocele as it is having less postoperative complication.

Materials and Methods

The present study was carried out in the Department of General surgery of JawaharLal Nehru Medical College, Sawangi (Meghe), Wardha, Maharashtra from 2014 to 2016. In this prospective study, 50 consecutive patients with primary vaginal hydrocele was divided in two groups-group A and group B, in which, group A was the study group and group B was the control group, in which, patients who were in study group underwent novel pull through technique and in control group they were operated with Jaboulay's method.

Inclusion Criteria- All cases of primary vaginal hydrocele above the age of 12 years.

Exclusion Criteria- Patients who had-

- Pyocele, haematocele, varicocele .
- Cystic swellings of scrotum other than hydrocele.
- All solid swellings of scrotum.
- Secondary hydrocele
- Hydrocele with elephantiasis of scrotum.

After thorough

history and proper physical examination with transillumination test, followed by ultrasonography (in some patients) was done to rule out any other intrascrotal pathological conditions.

In Novel pull through technique- With the patient in supine position the scrotal skin was thoroughly prepared with povidine-iodine and transverse incision of about 15mm was given on the scrotal wall using a scalpel knife. Dissection was continued

until parietal layer of tunica vaginalis is identified. The tunica was grasped on each side, the sac was minimally punctured and a small volume of fluid was aspirated to relieve scrotal tension. The sac was then gently mobilised and freed from adherent tissue with blunt dissection, followed by delivery of the sac out of the scrotal incision by applying gentle traction. During the procedure the hydrocele was aspirated gradually to facilitate easy delivery of sac. After maximum sac deliverance the mobilised tunica vaginalis was excised by electrocautery at its base, leaving minimum residual tunica vaginalis tissue around the testis. Bleeders were clamped and haemostasis was achieved with sutures ligation in the presence of visible bleeding from the tunica after electrocautery incision. The wound was closed with absorbable sutures without leaving any drains. Blood loss during surgery was measured using a digital scale by measuring the weight of the surgical gauze before and after the surgery (1gm=1ml)¹⁰. A wound dressing was applied and the scrotal support was given for 2 days.

In Jaboulay's operation testicles are released by ligating and dividing the gubernaculum testis and then the sac was everted and fixed with few sutures.

Observation and Results

The mean age of patients those who underwent Jaboulay's procedure was 43.44 years and in case of pull through technique was 49.04 years. The age varied between the range 24-70 and 23-79 years in case of Jaboulay's procedure and Novel pull through technique respectively. Out of 50 cases, USG was performed in only 17 patients those who were having transillumination negative.

The mean operative time of novel pull through technique was 17.80±3.84, whereas, for Jaboulay's procedure it was 23.70±5.45 minutes.

Postoperative complications like haematoma, infection and pain was compared in both the

procedures and found that in novel pull through technique,out of 25 patients only 4 patients had heamatoma which was managed conservatievely and no one had infection and minimal potoperative pain was experienced by the patient,where as,out of

25 patients,6 had heamatoma and 1 had infection with comparitively more postoperative pain in jaboulay's procedure.

Recurrence was not evident in any of the two procedures.

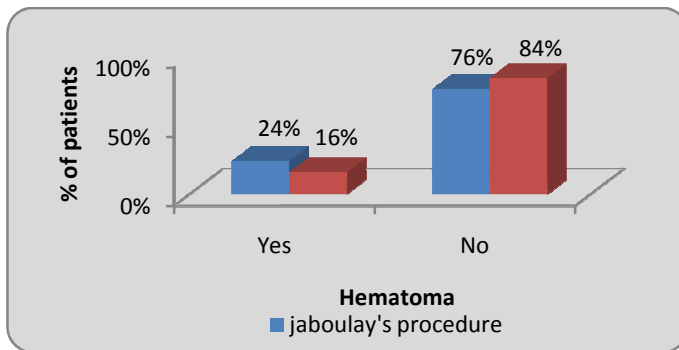
Table 1: Age wise distribution of patients

Age Group (yrs)	Jaboulay's procedure	Novel Pull Through Technique	χ ² -value
21-30 yrs	2(8%)	2(8%)	10.36 p=0.035,S
31-40 yrs	11(44%)	2(8%)	
41-50 yrs	7(28%)	10(40%)	
51-60 yrs	2(8%)	8(32%)	
>60 yrs	3(12%)	3(12%)	
Total	25(100%)	25(100%)	
Mean ±SD	43.44±11.46 (24-70 yrs)	49.04±11.62 (23-79 yrs)	

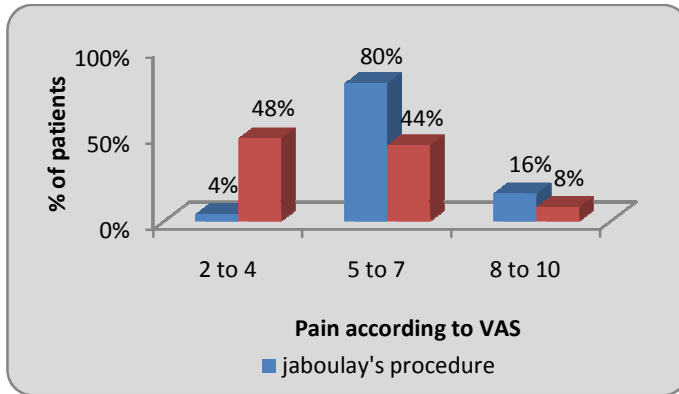
Table no 2. Distribution of patients according to duration of surgery

Duration of surgery(min)	Jaboulay's procedure	Novel Pull Through Technique	χ ² -value
10-20 min	12(48%)	23(92%)	11.60 p=0.0003,S
21-30 min	12(48%)	2(8%)	
31-40 min	1(4%)	0(0%)	
Total	25(100%)	25(100%)	

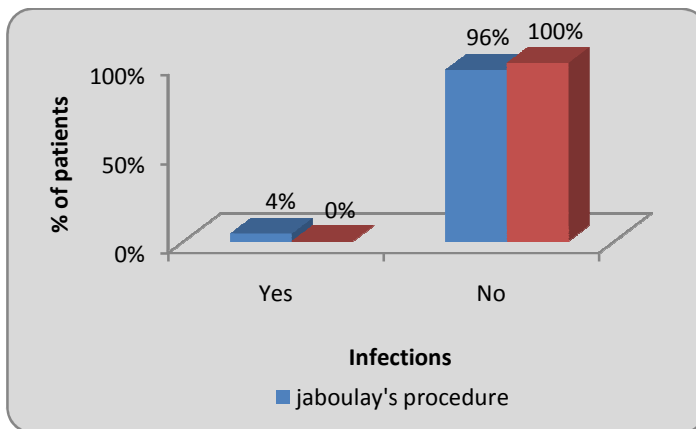
Graph 1 : Distribution of patients according to hematoma



Graph 2 : Distribution of patients according to pain according to VAS



Graph 3 : Distribution of patients according to infections



Conclusion

A Primary Vaginal hydrocele is one of the most common condition in General surgery department at A.V.B.R.H, Sawangi(meghe) .It usually appears in middle aged or elderly men.

This is caused by the collection of amber coloured sterile fluid between the parietal and visceral layers of tunica vaginalis,however,exact cause for primary vaginal hydrocele seems to be unknow.

In our setup,general surgeons preffered doing jaboulay's method for vaginal hydrocele but it has got certain limitations,so to overcome that,we did this comparative study.

According to this comparative study,the new novel pull through technique took less operative time,with mean time as 17.80 ± 3.84 ,as compared to jaboulay's method,for which mean operative time was 23.70 ± 5.45 and also less post operative complications as compared to jaboulay's method.

Out of the two procedures for hydrocelectomy,novel pull through technique is highly recommended over jaboulay's procedure and it is safe and least time consuming with no recurrence.

Bibliography

1. Chang YT, Lee JY, Wang JY, Chiou CS, Chang CC. Hydrocele of the spermatic cord in infants and children: its particular characteristics. *Urology*. 2010 Jul. 76(1):82-6.
2. Manjunatha Y, Beeregowda Y, Bhaskaran A. Hydrocele of the canal of Nuck: imaging findings. *Acta Radiol Short Rep*. 2012. 1(3).
3. Mihmanli I, Kantarci F, Kulaksizoglu H, Gurses B, Ogut G, Unluer E, et al. Testicular size and vascular resistance before and after hydrocelectomy. *AJR Am J Roentgenol*. 2004;183:1379-85.
4. Jat N, Bano F, Memon MS, Azmi MA. Primary vaginal hydrocele; different surgical procedures: a comparative study. *professional Med J* 2014;21(5):879-882.
5. Jahnson S, Johansson J E. Results of window operation for primary hydrocele. *Urology* 1993; 41 (1): 27-28.
6. Murillo Mirat J, Moran Penco J M, Cabello Padial J. Abdomino-Scrotal hydrocele: an unusual disease. *ActasUrolEsp* 1994; 18 (8): 838-840.
7. Lasheen, Adel. "Hydrocelectomy through the inguinal approach versus scrotal approach for idiopathic hydrocele in adults." *J Arab Soc Med Res* 7 (2012): 68-72.
8. Amuyunzu M. Community perception regarding chronic filarial swellings: a case study of the duruma of coastal Kenya. *East Afr Med J* 1997; 74: 411-415.
9. Gyapong M, Gyapong J, Weiss M, Tanner M. The burden of hydrocele on men in Northern Ghana. *Acta Trop* 2000; 77:287-294.
10. Al Kadri, H. M., Anazi, B. K., & Tamim, H. M. (2011). Visual estimation versus gravimetric measurement of postpartum blood loss: A 2 AWHONN Practice Brief prospective cohort study. *Archives of Gynecology and Obstetrics*, 283(6), 1207-1213.