

Original article:

Trifurcation of brachiocephalic trunk– A case report

Dr. Sushil Kumar, Dr. Ritwik Baidya

Assistant professor of Anatomy, Division of Anatomy, Department of Radiology
Weill Cornell Medicine, 1300 York avenue New York, NY 10065

Corresponding author: Dr. Sushil Kumar

Abstract:

During routine dissection a rare type of branching pattern of the arch of aorta was seen. The left common carotid artery was originating from the brachiocephalic trunk instead of the arch of aorta. This kind of anomaly occurs due to abnormal development of the arch of aorta. The surgeons while operating on the neck region have to keep in mind about such type of anomaly. Also it is important for interventional radiologists who do carotid angiograms.

Keywords:

Arch of aorta, Artery, Brachiocephalic trunk, Left common carotid artery, Mediastinum

Introduction:

The arch of aorta is a continuation of the ascending aorta. It first ascends diagonally and posteriorly to the left over the anterior surface of the trachea, then posteriorly across its left side, finally descending to the left of the fourth thoracic vertebral body, continuing as the descending thoracic aorta. ⁽¹⁾Three branches arise from the convex aspect of the arch of aorta: the brachiocephalic trunk, left common carotid artery and left subclavian artery. These branches may originate from the beginning of the arch or the upper part of the ascending aorta with varying distances between them. The distance between these origins from arch of aorta varies, the most frequent being approximation of the left common carotid artery to the brachiocephalic trunk. ⁽¹⁾ The anomalies of branches are due to variation in the extent of the fusion process and absorption of some of the aortic arch arteries into the aortic sac during embryonic development. Such process may cause an increase or decrease in the number of branches arising from the

arch of aorta. ^(2,3)This type of variations are usually asymptomatic, but they may cause difficulty in breathing, difficulty in swallowing, intermittent claudication, misinterpretation of radiological examinations and complications during neck and thorax surgery. Furthermore, these anomalies may be accompanied by other serious birth defects. ⁽²⁾

There are numerous variations in the branching pattern of the arch of aorta. Anson did analysis of variation in 1000 aortic arches and found out that: In 27%, the left common carotid artery originates from the brachiocephalic trunk. In 2.5%, each of the four arteries originates independently from the arch of the aorta, while in 1.2%, a right and left brachiocephalic trunk originate from the arch of the aorta. The most common pattern seen in 65% is formed by the separate origins of these three branches which was arising from the vessel's convex aspect: the brachiocephalic trunk, left common carotid and the left subclavian arteries. ⁽²⁾ In this case report we present an anomaly in which left common carotid

artery is originating from the proximal segment of the brachiocephalic trunk, making a loop on the anterior surface of trachea before taking a straight course.

Case report and observations

During dissection of an embalmed female cadaver at the division of anatomy, Weill Cornell Medicine, we found a variation in which brachiocephalic trunk was giving origin to the left common carotid artery. Brachiocephalic trunk was arising as a common trunk from the arch of aorta and had a normal course but branching pattern was anomalous. First, it gave left

common carotid artery and then gets divided into two terminal branches as usual in to the right common carotid artery and the right subclavian artery. The left common carotid artery first made a loop on the anterior surface of the trachea and then crossed to the left. Its remaining course and branching were normal. The course and relation of the left subclavian artery was normal. The initial part of right common carotid, right subclavian also had a tortuous course.

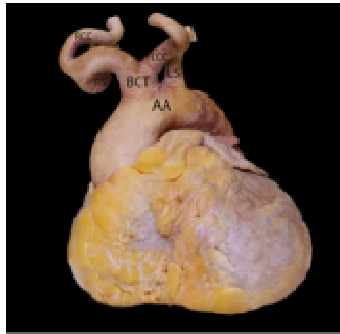


Fig. 1

Picture showing the left common carotid artery originating from brachiocephalic trunk. AA arch of aorta, BCT brachiocephalic trunk, LCC left common carotid artery, RS right subclavian artery, RCC right common carotid artery, LS left subclavian artery

Discussion

Variations in the branching pattern of the arch of aorta are not uncommon. It ranges from differences in the distance between the origins of the different branches to the number of branches. Adachi has classified the branches of arch of aorta into three categories. Categories in which the common trunk incorporating the left common carotid artery and the brachiocephalic trunk, leaving only two branches originating from arch of aorta has been classified as type B and its incidence is 11%. The two branches are common trunk and left subclavian artery.⁽⁴⁾ Sumit Tulshidas Patil et al had classified the similar branching pattern as aortic arch

pattern type II and this was found in eleven specimens (14.66%). Variation in the length of the common trunk in type II, led to the further sub-classification. In type IIA the length of the common trunk was nearly 4-6 cm, while in type IIB, it was very short and the origin of the left common carotid was at the root of the common trunk. Out of 11 specimens of type II, four were of type II A and seven were of type II B.⁽⁵⁾ The variation in our case fits into Adachi's type B and type II B of Sumit Tulshidas Patil et al study. Rekha, P. and Senthilkumar, S have classified the similar pattern into type II in their study and found it in 2.72% of specimens.⁽⁶⁾ Sanjeev Kumar et al have classified

similar pattern into type III and have found in 3.33% of specimens.⁽⁷⁾ SumitTulshidasPatil et al did a retrospective study into the clinical history and cause of death from the 'death certificate' of the donors in their study and tried to find a co-relation of the branching pattern of the arch of the aorta with cerebrovascular disease. Type I is normal branching pattern of the aortic arch in which out of 58 cadavers, 7 (12%) were diagnosed with cerebro-vascular disease, while in the case of variant branching pattern, type II, 4 (23.5%) cadavers out of 17 had cerebrovascular disease. In type II pattern, origin of left common carotid artery is slightly shifted to right side so that it is incorporated with brachiocephalic trunk and comes in a straight line with ascending aorta. This may be the reason to increase blood flow in left common carotid artery. This direct (straight line) flow of blood from the aortic arch to the brain or imbalance of flow of blood on the left and the right side at the circle of Willis may be the cause of increased incidence of cerebrovascular diseases in cadavers having type II pattern of aortic arch.⁽⁵⁾

Vey rarely, the left brachiocephalic trunk gives rise to the left common carotid and the left subclavian arteries. Sometime the right common carotid and right subclavian arteries arise separately from the arch of aorta. The right subclavian artery arises from the left end of the arch of aorta and passes behind the esophagus causing esophageal compression.⁽³⁾

Variation in the branching pattern of the arch of aorta is of great clinical significance, because ignorance may cause serious consequences during surgery in the lower part of the neck or in the upper part of the superior mediastinum.

Embryological basis

During early development, each side of the aortic sac is connected with the corresponding dorsal aorta by

six pairs of the aortic arches. Fifth aortic arch degenerates soon after its formation. At a later developmental stage, the other aortic arches are extensively transformed, and finally the normal blood supply system is achieved. All the aortic arches don't appear simultaneously. The first and second aortic arches appear first and largely disappear by the time the third to sixth arches begin to develop.

The aortic sac normally bifurcates into right and left horns. The right horn of the aortic sac forms the brachiocephalic trunk. The left horn of the aortic sac normally forms the part of the arch of aorta, which lies between the origins of the brachiocephalic trunk and the left common carotid artery. Sometimes, the aortic sac fails to bifurcate into the right and left horns. In such condition, the brachiocephalic trunk and the left common carotid would arise from a common trunk from the arch of aorta giving rise to the variations, as observed in the present case report.^(3,8,9)

Conclusion

Variations in the origin and course of the arteries from the arch of aorta is of immense surgical value, because lack of knowledge of these variations may lead to serious surgical complications during procedures occurring in the upper part of the superior mediastinum and the root of the neck. Most of the time, such variations are clinically silent. It could indirectly damages the brain in the form of cerebrovascular accidents like stroke because of high pressure on the variant arteries, which may lead to the formation of atherosclerosis.

By the results found in many studies shows that, this kind of variation is rare. It carries more importance in presenting this case by adding to the existing knowledge. It continues to remain important to report

unusual or rarely seen anatomical variations in the field of clinical anatomy.

Acknowledgments

Our sincere gratitude to the LinoTineo (audio visual technician) for taking good picture and Crandell Warner (Lab technician) for preparing the specimen.

References

1. Standring S, Gray's anatomy. The Anatomical Basis of Clinical Practice. 41st edition, London: Elsevier; 2016: 1024-1025.
2. Anson BH, Cardiology: The Aortic Arch And Its Branches (Volume 11). New York: McGraw-Hill; 1963: 68.
3. Moore KL, Persaud TVN, Torchia MG, The developing human: Clinically Oriented Embryology. 10th edition, Philadelphia: Saunders Elsevier; 2016: 305-306, 316-325.
4. Adachi B. Das Arterien system der Japaner (Volume 1): Verlag der Kaiserlich-Japanischen Universitat, Tokyo: Kenyusha Press; 1928 :29-41.
5. Sumit T.P, Meena M.M, Namdeo Y.K, Arun P.K, Madhukar P Parchand. Study on branching pattern of aortic arch in Indian. Anat cell biol. 2012; 45: 203-206.
6. Rekha P, Senthilkumar S. A study on branching pattern of human aortic arch and its variations in south Indian population. J Morphol Sci. 2013; 30(1): 11-15.
7. Sanjeev Kumar, ImtiazulHaq, Kathiresan K. Study of branching pattern of arch of aorta and its variations. National journal of clinical anatomy. 2012; 1(4):176-180.
8. Sadler TW: Langman's Medical Embryology. 12th edition, Philadelphia: Lippincott Williams and Wilkins; 2012: 185-195.
9. Nayak SR, PaiMM, Prabhu LV, Costa SD, ShettyP. Anatomical organization of aortic arch variations in the India: embryological basis and review. Journal Vascular Brasileiro. 2006; 5(2): 95-100.