

Case report:

Multiple Variations in the Arterial Branching Pattern of the Upper Limb – A Case Report

***Sanga Aradhana¹, Roy Sayongdeepa¹, Dey Saikat Kumar¹**

¹Junior Resident, Department of Anatomy, North Bengal Medical College & Hospital, Darjeeling, West Bengal – 734012.

Corresponding author*

Abstract:

Arterial variations in the upper limb is a common finding but a combination of high origin of the ulnar artery that lies superficially (commonly referred to as the superficial ulnar artery) along with a related variation in the formation of superficial palmar arch is quite rare. It has been reportedly seen in 0.17 – 2% of the cases, according to previous studies.

During routine dissection of the superior extremity of a 75 year old male cadaver, the superficial ulnar artery (SUA) was seen to arise from the brachial artery (BA) in the middle third of the left arm and ran along the medial side of the forearm before entering the palm superficial to the flexor retinaculum and continuing to form the superficial palmar arch. The BA itself divided at the level of the neck of the radius into the radial artery (RA) and the common interosseous artery (CIA).

The RA ran along the lateral margin of forearm and entered the dorsum of the hand without giving off any superficial palmar branch at the level of wrist. At the anatomical snuff box, the RA pierced the first dorsal interosseous muscle and entered the palm where it divided into two branches among which, the superficial branch anastomosed with the SUA to complete the superficial palmar arch (SPA).

The CIA gave off a smaller twig which was identified as the posterior interosseous artery (PIA) before itself dividing into the anterior interosseous artery (AIA) and another artery which accompanied the median nerve along the midline of the forearm and was hence referred to as the Arteria Nervi Mediana (ANM). Both the AIA and the ANM terminated at the level of the wrist by supplying the adjoining muscles. No such arterial anomaly was found in the right upper limb of the cadaver. The knowledge of these variations is important in both gross and clinical anatomy.

Key Words: Superficial Ulnar Artery, Arteria Nervi Mediana

Introduction

The knowledge of arterial system of upper limb and its variations is important in clinical practice. The brachial artery (BA) is the continuation of the axillary artery (AA) beyond the lower border of teres major. Under normal circumstances, it crosses elbow joint and terminates at the level of the neck of radius by dividing into the radial (RA) and ulnar (UA) arteries. The RA continues further distally along the lateral border of forearm. It gives a superficial palmar branch at the level of the wrist before winding around

its lateral margin to enter the anatomical snuff box dorsally. Thereafter it passes between the two heads of the 1st dorsal interosseous muscle and pierces adductor pollicis muscle to reach the palm. Before piercing adductor pollicis, it gives rise to three branches – the 1st dorsal metacarpal artery (DMA), arteria princeps pollicis (APP) and arteria radialisindicis (ARI).

The ulnar artery, after arising from the brachial artery, gives off a common interosseous branch (CIA) in the cubital fossa. The CIA further divides

into a posterior interosseous branch (PIA) and an anterior interosseous branch (AIA).

The PIA passes dorsally in between the radius and the ulna through a gap above the interosseous membrane and enters the extensor compartment of the forearm. The AIA moves distally in the anterior compartment of the forearm up to the wrist and pierces the interosseous membrane to enter the posterior compartment of the forearm and anastomoses with the PIA. The UA itself continues along the medial side of forearm and over the flexor retinaculum to enter palm lateral to pisiform bone. It then divides into superficial and deep branches, which anastomose with the corresponding superficial and deep branches of the RA, thereby completing the superficial and deep palmar arches respectively.^[1]

Case Report

During routine dissection of a cadaver of a 75 year old male for the purpose of undergraduate medical teaching at North Bengal Medical College and Hospital in September 2015, we came across multiple variations in the branching pattern of the BA and in the formation of the superficial palmar arch (SPA) in the left upper extremity of the cadaver.

In the middle third of the left arm, the BA was seen to give rise to a branch medially. This branch had a superficial course throughout its entire extent. It passed superficial to the muscles attached to the medial epicondyle of the humerus as well as the bicipital aponeurosis before entering the forearm and passing along its medial side. It was then seen to enter the palm, superficial to the flexor retinaculum, whereby it continued to form the SPA. This branch of the BA was hence identified as the superficial ulnar artery (SUA).



Figure 1: Origin & course of Superficial Ulnar Artery

[BA- Brachial Artery, SUA – Superficial Ulnar Artery, RA – Radial Artery, a – Origin of SUA]

The BA itself continued along its usual course and bifurcated at the level of the neck of radius into two branches.

One of the branches continued laterally along the forearm up to the wrist where it wound around the lateral margin and entered into the anatomical snuff box dorsally. This branch was hence identified as the

radial artery (RA). The RA did not supply any superficial branch to the palm at the level of the wrist.

In the anatomical snuff box, the RA pierced the 1st dorsal interosseous and entered the palm. Then it divided into two branches, the superficial of which anastomosed with the SUA to complete the SPA.

The second branch of the BA in the cubital fossa was identified as the common interosseous artery (CIA). The CIA divided into a smaller twig, the PIA, which passed posteriorly into the extensor compartment of the forearm by piercing the interosseous membrane, and a larger trunk. The larger trunk further subdivided into two divisions.

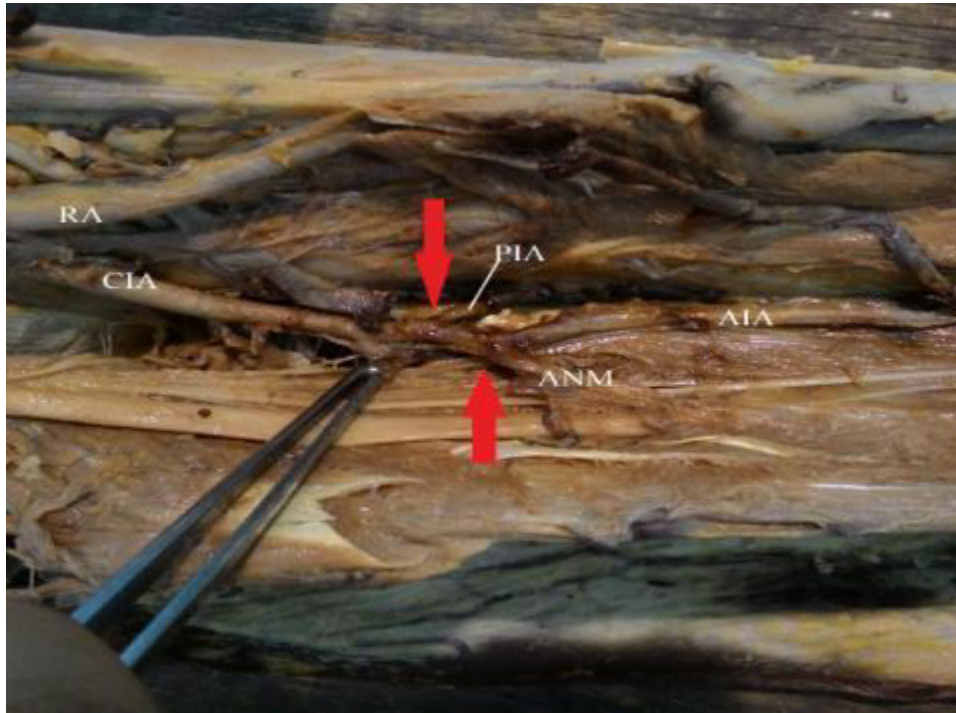


Figure 2: Branching of Brachial Artery

[RA – Radial Artery, CIA – Common Interosseous Artery, PIA – Posterior Interosseous Artery, ANM – Arteria Nervi Mediana, AIA – Anterior Interosseous Artery]

The deeper division was seen to rest on the interosseous membrane and was hence identified as the AIA. The superficial division was seen to run along the midline of the forearm accompanying the median nerve. It was hence identified as the arteria nervimediana (ANM).

Both the divisions terminated at the level of the wrist by supplying the adjoining muscles.

Upon further inspection, the SPA formed by the union of the superficial terminal branch of the RA and the SUA, gave rise to the following branches:

1. A proper palmar digital artery for the ulnar side of little finger.
2. Four common palmar digital arteries for the adjacent sides of little, middle and ring fingers.

The most lateral common palmar digital artery gave rise to two branches – the arteria princeps pollicis (APP) and the arteria radialisindicis (ARI).

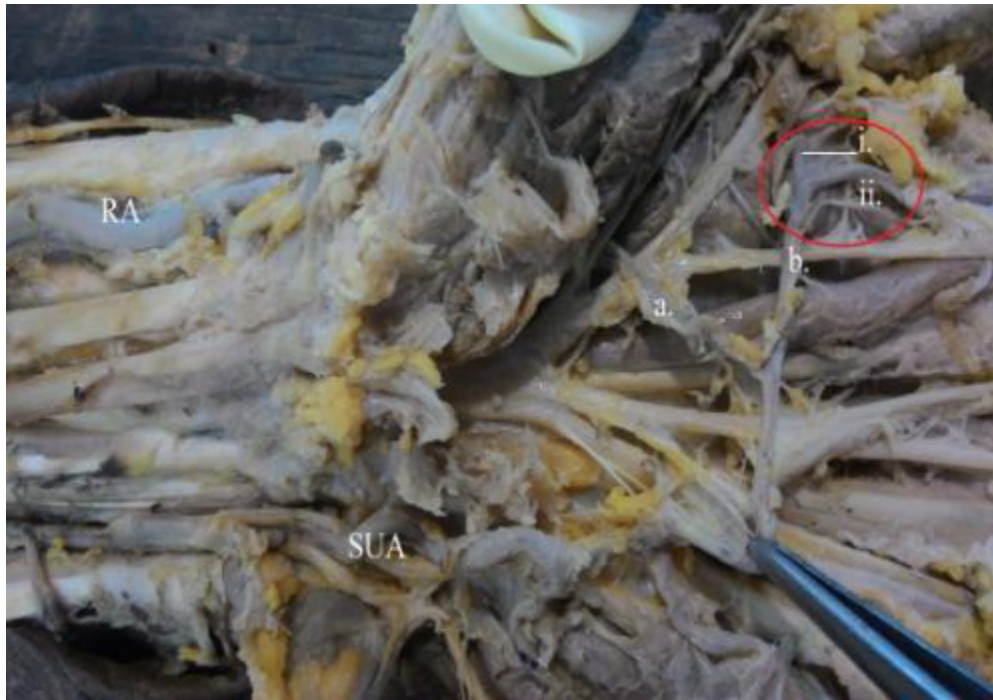

Figure 3: Anomalous branching of SPA

[RA – Radial Artery, SUA – Superficial Ulnar Artery, a – superficial terminal branch of RA, b – most lateral common palmar digital artery, i – arteria princeps pollicis, ii – arteria radialis indicis]

No such arterial anomaly was found in the right upper extremity of the cadaver.

Embryology:

Normally, a capillary network begins to develop at the tip of the developing limb bud from the 26th day of intrauterine life (IUL). Then, the Axis Artery sprouts from the 7th intersegmental artery and invades the limb bud from the 28th day of IUL. Proximal part of the Axis Artery gives rise to BA and the distal part

to interosseous arteries. This differentiation takes place by 41st to 44th day of IUL. All the arteries of upper limb sprout from the axis artery.^[2]The SBA is the first to sprout. It divides into a lateral radial branch and a medial branch known as the superficial antebrachial branch. The latter passes from the lateral to the medial side before dividing into median and ulnar branches. (Figure – 4a)

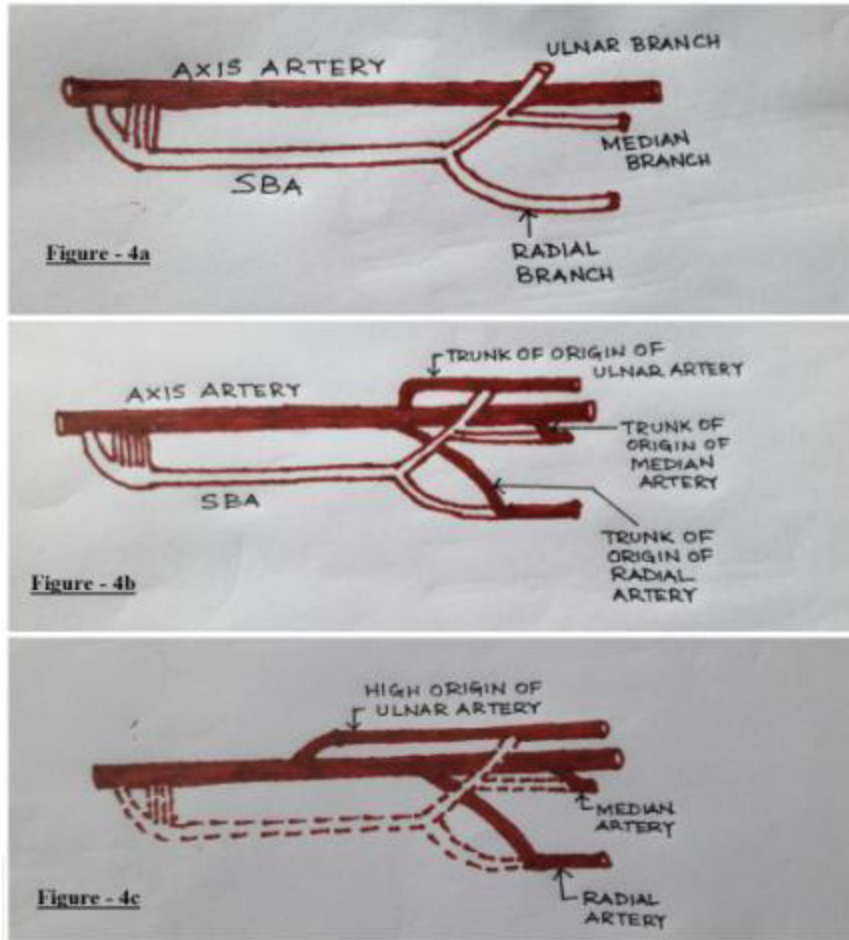


Figure 4: Development of arterial system of upper limb

Thereafter, the trunks of the main arteries, namely RA, UA and median, arise from the axis artery and finally they anastomose with the corresponding branches of SBA to complete the arterial network. (Figure – 4b)

Circulation through the main trunk arteries take precedence and over time the SBA and its branches are obliterated. (Figure – 4c) All the arteries as well as the palmar arches become well defined by 52nd day of IUL.

Mainly the UA and partly the RA joins the capillary network developing at the tip of the limb bud which differentiates to form the palmar arches. In our case,

the trunk of origin of UA seems to have arisen from the BA at a higher level than normal. Also, the BA has divided at a lower level into RA and another trunk which has formed the CIA, which in turn has sprouted a thin PIA, before dividing into median artery and AIA.

Discussion

Arterial variations of upper limb is a very common finding but the combination of a high origin of UA that lies superficially (and hence known as SUA) along with variations in SPA is relatively rare. In a study by Natsis et al., the incidence was placed at about 20% in human adult limbs. [2] Vollala et al.

found a similar pattern of high origin of ulnar artery from the brachial artery as well as APP and ARI arising from the SPA. But in that case, the SPA was incomplete with no communication from the RA. [3]

In a study by Rodriguez et al. it was found that when SUA is present, the BA commonly terminates into the RA and the CIA. They also postulated that the SUA arises most commonly from the lower 1/3rd, less commonly from upper 1/3rd and rarely from the middle 1/3rd of the BA. [4] In that light, our finding of the SUA arising from the middle 1/3rd of the BA seems to be a rare finding. Similar findings were reported by Shetty et al. [5] and Diego Casal [6] et al. in their studies on variant origin and course of UA with or without any variation in the formation and branching of SPA.

Adachi, in 1928, had enumerated three types of superficial palmar arch. [7]

- a. Ulnar Type – In which the contribution by the RA is absent or minimal.
- b. Radio-ulnar Type – Where there is equal contribution by RA and UA in the formation of SPA.
- c. Median-ulnar Type – Where the median artery is involved in formation of SPA.

According to this classification, the SPA found in our case is of the Ulnar Type.

According to sub classification by Coleman and Anderson [8], our case can be classified as Group - I (Complete Arch), Type E (formed mainly by the UA with negligible contribution from a small twig of RA).

In a study of palmar arterial arches within Indian population by Patnaik et al. in 2002 [9], the incidence of ulnar type of arches was found to be only 2%. However, Adachi reported the incidence in 1928 at 59% [7] and Karlsson&Niechajev in 1982 at 64%. [9]

In another report, Agur and Lee found a branch from RA piercing the 1st dorsal interosseous to reach the palm from the dorsum and named it Dorsalis Pollicis artery. [10] Mookambika et al. reported of SPA being formed only by the SUA, which was giving rise to ARI and APP apart from its normal branching pattern. [11] The knowledge of these variations is important as it decreases the chances of inadvertent arterial penetration during venipuncture. Orthopaedic surgeons must keep these variations in mind during repair of ruptured distal bicipital tendon. This knowledge can also be of great advantage to plastic surgeons in case of ulnar flap surgeries and to surgeons to treat thrombosed forearm arteries. Thus, this case report will enhance our knowledge in both gross and clinical anatomy.

Bibliography:

1. Standring S, Johnson D, Collins P, Healy JC, Evans DM, Lee J, Tickle S, Graham T. (Eds) Gray's Anatomy. The Anatomical Basis of Clinical Practice. In: Pectoral Girdle and Upper Limb. Vascular Supply and Lymphatic Drainage. 40th ed. Churchill Livingstone; Elsevier. Spain 2008, reprinted in 2011:815-17.
2. Natsis K, Papadopoulou AL, Paraskevar G, Totlis T, Tsikaras P. High Origin of Superficial Ulnar Artery arising from Axillary Artery: anatomy, embryology, clinical significance and review of literature. Folia Morph (Warsz) 2006; 65:400-5.
3. Vollala VR, Jetti R, Soni S. High Origin of Ulnar Artery – Development and Surgical Significance. Chang Gung Med J. 2011; 34(Suppl):39-42.

4. Rodriguez – Niedenfuhr M, Vazquez T, Nearn L, Ferreira B, Parkin I, Sanudo JR. Variation of the arterial pattern in upper limb revisited: Morphological and statistical study with a review of literature. *J Anat.* 2001; 199:547-66.
5. Shetty SD, Nayak S, Ashwini LS, Sirasanagandla SR. Variant Origin and Course of Ulnar Artery. *International Journal of Anatomical Variation.* 2013; 6:45-6.
6. Casal D, Pais D, Toscano T, Bilhim T, Rodriguez L, Figueiredo I, Aradio S, Almeida MA, Goyri-o-Neil J. A rare variant of ulnar artery with important clinical implications. *BMC Research Notes.* 2012; 5:660
7. Adachi B. Das arterien system des japaner. 1928; Kyoto Vol:365,368,389
8. Coleman S, Anson J. Arterial pattern in hand based upon a study of 650 specimens. *Surgery Gynaecology Obstetrics.* 1961; 96:43-54.
9. Patnaik VVG, Kalsey G, Singla RK. Palmar arterial arches – a morphological study. *J AnatSoc India.* 2002; 51(2):187-93.
10. Agur AMR, Lee MJ. Grant's Atlas of Anatomy. In: Upper Limb – Anterior aspect of palm and wrist. 9th Ed. Baltimore, Williams and Wilkins. 1991:434
11. Mookambika RV, Nair V, Nair R, Somayaji SN, Pamidi N, Vollala VR. Incomplete superficial palmar arch. *International Journal of Anatomical Variation.* 2010; 3:65-6.