

**Original article :**

## **Valgus subtrochanteric osteotomy for malunited intertrochanteric fractures : Our experience in 5 cases**

**Rajendraprasad Butala \* , Sunirmal Mukherjee, Prakash Samant, Ravindra Khedekar**

Dr D. Y. Patil Hospital, Navi Mumbai, India

Corresponding author\*

---

### **ABSTRACT:**

**Introduction:** Neglected Intertrochanteric fractures are a common presentation in Indian scenario, the incidence of which is not reported. Varus malunion is more commonly seen as compared to valgus malunion. Non-union is rarely seen in intertrochanteric fractures as the region has a good blood supply and comprises mostly of cancellous bone.

**Material and Method :** A total of 5 cases were operated between January 2013 to December 2015 at Dr. D. Y. Patil Medical College, Navi Mumbai. All the patients were above 65 year old and had comminuted fracture of intertrochanteric fracture. All the fractures occurred after fall during household activities or slip at bathroom.

**Results and conclusion:** To conclude, valgus osteotomy with DHS fixation is a useful technique for varus intertrochanteric malunion with good results and an effective alternative to arthroplasty in providing painfree mobile joint.

---

### **Introduction**

Neglected Intertrochanteric fractures is a common presentation in Indian scenario, the incidence of which is not reported. Varus malunion is more commonly seen as compared to valgus malunion. Non-union is rarely seen in intertrochanteric fractures as the region has a good blood supply and comprises mostly of cancellous bone. Due to this non-union is seen in patients with displaced comminuted fractures of intertrochanteric region in addition to presence of comorbidities like uncontrolled diabetes mellitus, hemiparesis, malignancies, poor nutrition etc. Literature is sparse regarding primary intertrochanteric nonunions and malunion and its treatment. A valgus angulation osteotomy is the most commonly described procedure for such cases. The advantages are that it helps in achieving compression at

fracture site by altering the fracture plane to more horizontal position and also helps in restoring the limb length discrepancy. A lateral based closed wedge valgus osteotomy is more commonly performed. We have done retrospective study of lateral closed wedge valgus intertrochanteric osteotomy performed in 5 cases of untreated intertrochanteric fracture.

### **Material and Method**

A total of 5 cases were operated between January 2013 to December 2015 at Dr. D. Y. Patil Medical College, Navi Mumbai. All the patients were above 65 year old and had comminuted fracture of intertrochanteric fracture. All the fractures occurred after fall during household activities or slip at bathroom.

All the patients did not take any treatment or refer to medical practitioner following fall. Patients

presented at 6 month to 9 month after history of fall, with inability to walk except 2 patients who were walking with limp. The usual clinical findings were supratrochanteric shortening with broadening of trochanteric prominence and external rotation attitude of limb and ipsilateral abductor insufficiency. Preoperative Abduction and adduction view were additionally taken apart from routine antero-posterior and lateral x-rays of the hip joint.

Preoperative neck shaft angle of bilateral proximal femur was calculated. The amount of correction needed was calculated and the angle of wedge to be resected was decided.

All patients were given spinal anaesthesia with epidural catheter insertion. Supine position on fracture table was given with the limb rotation adjusted to 10 degree external rotation.

Skin incision was taken from greater trochanter distally along the femur shaft approximately 10 cm in length. Vastus Lateralis was reflected from the vastus ridge in an inverted-L pattern. Excessive periosteal stripping from the anterior and posterior aspect was avoided and the dissection was confined only on the lateral aspect of shaft femur.

The 2.5 mm guide wire for the Richard's screw was inserted such that it lies in the centre of the femoral neck in AP and lateral.

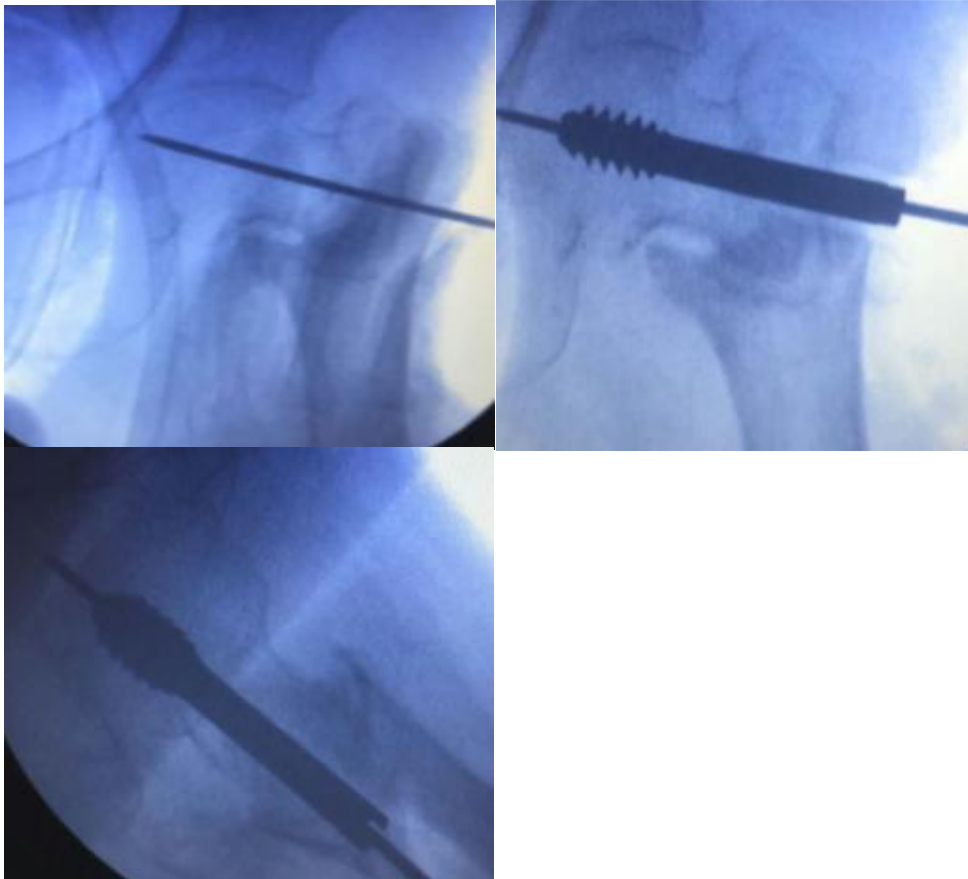


Figure 1 – Intraoperative Guide wire and Richard screw insertion

The guide wire was inserted along the axis of the femoral neck that has been achieved with traction. The track for the DHS lag screw was created with a triple reamer and an appropriately sized lag screw was inserted.

Technique of osteotomy and DHS fixation –

A drill hole was made at the level of osteotomy at the level of lesser trochanter using 3.5 mm drillbit from lateral to medial direction under fluoroscopic guidance. Another similar drill hole was made 1 inch distal to the first one from lateral aspect towards the lesser trochanter meeting the first drill

tract. From the drill hole on the lateral cortex multiple drill tracts were made both anteriorly and posteriorly to weaken the bone and for easier osteotomy using straight osteotome. A lateral based wedge of bone was removed and the osteotomy site closed by approximation of the proximal and distal segment of bone. This is achieved by abducting the limb on fracture table. The bone wedge resected was used as morcellised bone graft for the osteotomy site as well as intertrochanteric fracture site.

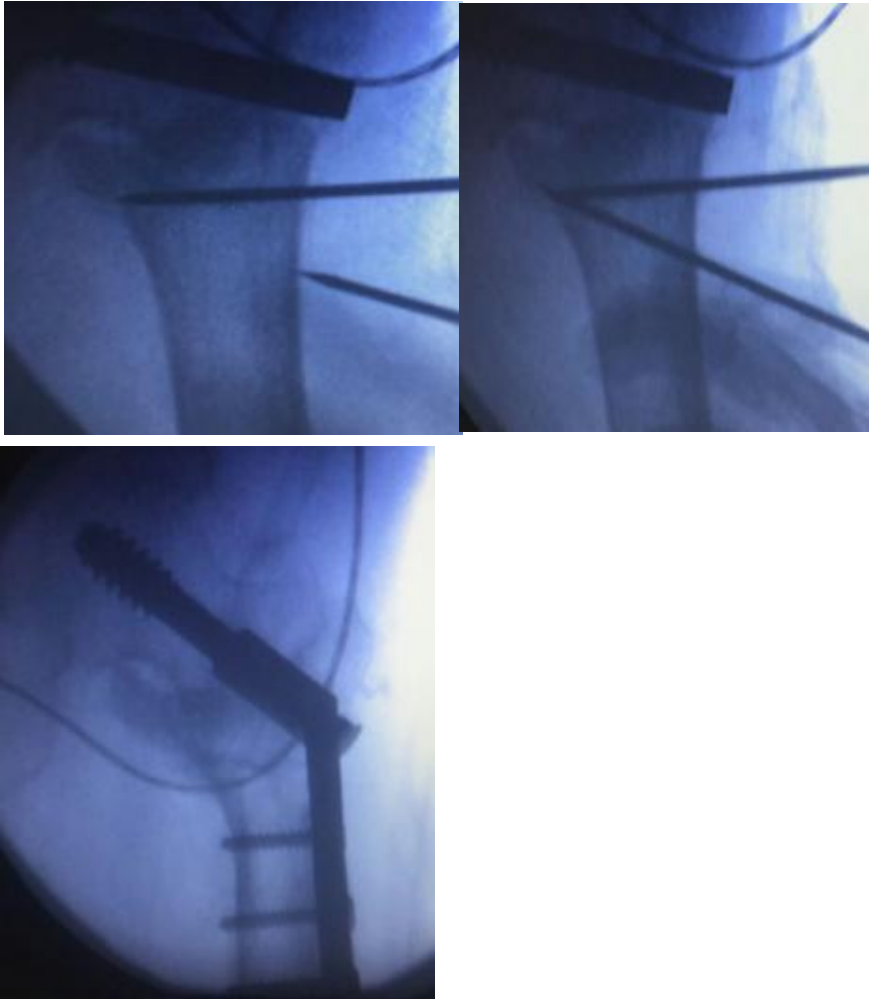

Figure 2 – Valgus osteotomy being performed

Post-operatively ankle pump exercises and static quadriceps exercises were started from immediate post-operative period followed by dynamic quadriceps exercises and gluteal muscle strengthening exercises depending on pain tolerance. Patients were discharged on 11<sup>th</sup> post-operative day after suture removal. Dietician consultation was taken postoperatively to start patients on protein and calcium rich diets along with nutritional supplements. All patients were mobilized immediately and were kept non weight bearing for 8 weeks, followed by partial weight bearing depending on pain tolerance and progressed to full weight bearing depending on radiological and clinical union which was generally by 12 weeks. Patients were followed up regularly every 4 weeks after discharge till fracture union. All patients were followed up to 6 months to review hospital records and radiographs. Follow up radiographs were assessed by the authors for fracture union, corrections in Pauwel's angle and neck shaft angle. Oxford hip score and limb length discrepancy were assessed at 6 months. The lowest clinically appreciable length discrepancy was set at 0.5 cm.

Out of the 8 patients, 5 were male and 3 were females. All patients were untreated cases of intertrochanteric fracture either due to negligent behaviour of patients belong to low socio-economic status or due to lack of nearby medical facility and subsequent treatment by quack. The average surgical time was 120 minutes {100 – 160 minutes}. The average blood loss was 290 ml {200 – 400 ml}. All fractures radiologically united at a mean time of 12 weeks {10 – 14 weeks}. The average pre operative neck-shaft angle was 102 degrees {95 - 110 degrees} which was corrected to 135 or 130 degrees. The mean Oxford hip score was 39 at 6 month follow up. There were no screw cut outs or loss of correction. One patient had implant loosening of barrel at the distal part for which revision surgery was required. There were no incidences of deep infection. 1 patient had clinically demonstrable limb shortening of 1 cm which required a heel raise during rehabilitation. 3 patients demonstrated mild trendelenberg lurch at 6 month follow up which required assistance of walking stick. One patient at 8 weeks follow up showed implant loosening of the plate which required revision using a longer plate and additional cerclage wiring

**Results**

Table 1 : Results in 5 patients

| Sr. no. | Time of surgery after trauma (weeks) | Duration of surgery (min) | Intra-op blood loss | Pre-op neck shaft angle (degree) | Post op correction achieved | Correction achieved (degrees) | Oxford hip score at 6 months | Limb length discrepency post surgery |
|---------|--------------------------------------|---------------------------|---------------------|----------------------------------|-----------------------------|-------------------------------|------------------------------|--------------------------------------|
| 1       | 12                                   | 125                       | 250                 | 108                              | 135                         | 27                            | 41                           | 1                                    |
| 2       | 12                                   | 100                       | 300                 | 110                              | 135                         | 25                            | 40                           | 0.5                                  |
| 3       | 14                                   | 105                       | 300                 | 100                              | 135                         | 35                            | 32                           | 1                                    |
| 4       | 24                                   | 110                       | 200                 | 95                               | 130                         | 35                            | 41                           | 0.5                                  |
| 5       | 10                                   | 160                       | 400                 | 98                               | 130                         | 32                            | 41                           | 1                                    |

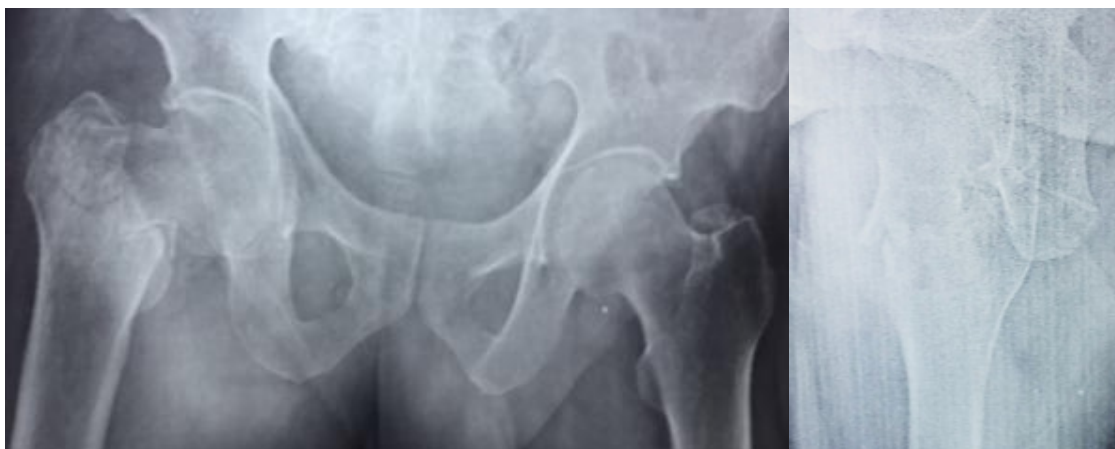

Figure 3 - Preoperative X-ray of varus malunited intertrochanteric fracture.

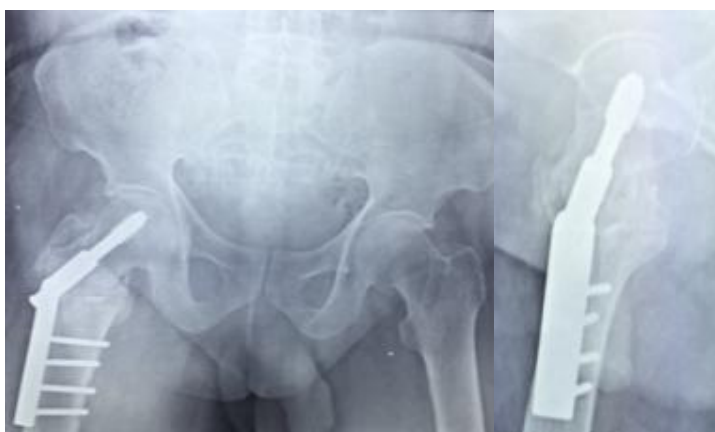

Figure 4 - Post operative xray after valgus osteotomy

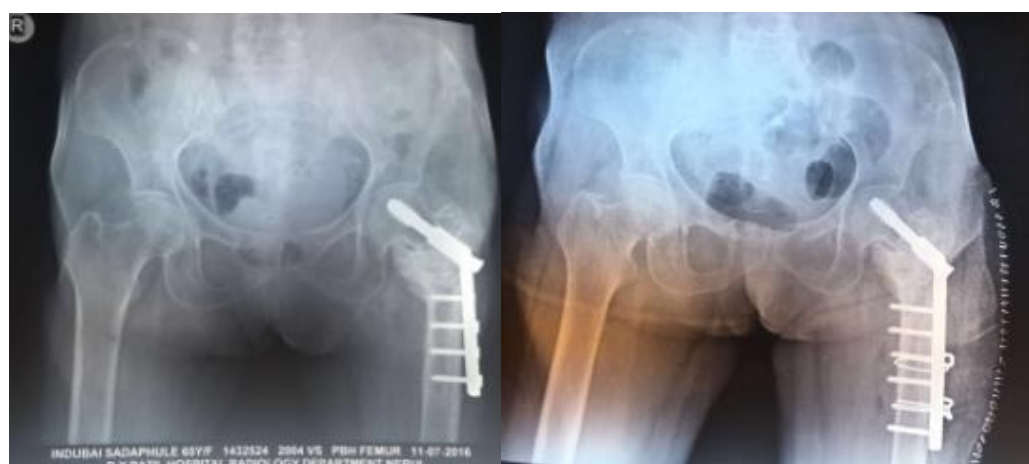

Figure 5 - Pre-op and post revision xray of implant loosening.

### Discussion

Numerous techniques have been described for valgus osteotomy. Lateral closed wedge osteotomy is the most commonly performed procedure. It requires simple preoperative planning regarding amount of wedge to be resected. A good area of contact at the osteotomy site can be maintained with minimal lateral displacement of the distal fragment and without significant opening up of the medial side.

A very low subtrochanteric osteotomy should be avoided as it will be through the cortical bone where union rates are poor due to higher stresses acting at the site and many cases of nonunion at the osteotomy site have been reported.

Valgus osteotomy has a high success rate and good reproducibility. In Indian scenario, valgus osteotomy is an effective alternative to hip replacement surgery due to the high cost of the procedure. In our patients, improvement was seen in hip range of motion and decrease in hip pain and lurch while walking following the procedure. Literature on nonunion of extracapsular fractures is sparse as these fractures commonly malunion rather than going for nonunion.

In our experience the surgical technique was easy to perform and easily reproducible with simple preoperative planning about the correction of valgus angle required. In all 5 patients, limb length

discrepancy was not an issue and was managed with providing heel raise with minimum functional disability during rehabilitation. In 2 patients limb length was restored and discrepancy of only 5 mm was present in 2 patients and 1 cm in one patient after valgus correction. All the patients were able to perform routine household activities when questioned at the end of 6 months which included sitting cross legged and squatting requiring support while getting up. Outdoor activities like walking on roadside and uneven surfaces was carried out with little difficulty and use of walking aid – a tripod walking stick.

The results were comparable to studies by Jan Bartonicek et al., who had published good results of valgus osteotomy in Intertrochanteric non-union and malunion.

Most of the published data of valgus osteotomy are for femoral neck non-union. Our surgical technique for osteotomy was similar to that of James M Hartford et al., who used full thickness lateral based wedge resection for achieving valgus.

### Conclusion:

To conclude, valgus osteotomy with DHS fixation is a useful technique for varus-inter-trochanteric malunion with good results and an effective alternative to arthroplasty in providing painfree mobile joint.

### References:

1. Anglen JO: Intertrochanteric osteotomy for failed internal fixation of femoral neck fracture. ClinOrthop. 1997, 341: 175-182.
2. Marti RK, Schuller HM, Raaymakers EL: Intertrochanteric osteotomy for non-union of the femoral neck. J Bone Joint Surg Br. 1989, 71: 782-787

3. Wu CC, Shih CH, Chen WJ, Tai CI: Treatment of femoral neck nonunions with a sliding compression screw: comparison with and without subtrochanteric valgus osteotomy. *J Trauma*. 1999, 46: 312-317. 10.1097/00005373-199902000-00019
4. Schoenfeld AJ, Vrabec GA: Valgus osteotomy of the proximal femur with sliding hip screw for the treatment of femoral neck nonunions: The technique, a case series, and literature Review. *J Orthop Trauma*. 2006, 20: 485-491. 10.1097/00005131-200608000-00006.
5. Hartford JM, Patel A, Powell J: Intertrochanteric osteotomy using a dynamic hip screw for femoral neck nonunion. *J Orthop Trauma*. 2005, 19: 329-333.
6. Bartonicek J, Skala-Rosenbaum J, Dousa P: Valgus intertrochanteric osteotomy for malunion and nonunion of trochanteric fractures. *J Orthop Trauma*. 2003, 17: 606-612. 10.1097/00005131-200310000-00002.
7. Mueller ME: The intertrochanteric osteotomy and pseudoarthrosis of the femoral neck. *ClinOrthop*. 1999, 363: 5-8.
8. Jan Bartoníček, MD, Jirí Skála-Rosenbaum, MD, and Pavel Douša, MD. Valgus Intertrochanteric Osteotomy for Malunion and Nonunion of Trochanteric Fractures *J Orthop Trauma* • Volume 17, Number 9, October 2003