

**Case report:**

## **Phyllodes tumour, a rare transformation of fibro adenoma: a case report and review of literature**

**Dr.Pragya Garg,Dr.Supreethi Kohli**

Name of the Institute/college: Post Graduate Institute Of Medical Science And Research(P.G.I.M.S.R). and Employee State Insurance(E.S.I)Model Hospital.

Corresponding author : Dr.Supreethi Kohli

---

**Abstract:**

The phyllodes breast tumour is a special kind of fibroadenoma that constitutes 0.3-1% of all breast tumours. Fibroadenomas transforming to phyllodes tumour is an unusual phenomenon with only a few cases reported in the literature. The appearance of these breast tumours, especially small lesions, on sonography and mammography usually do not allow the distinction of a fibroadenoma from a phyllodes breast tumor . Dynamic breast MRI aids in differentiation and further categorization of phyllodes breast tumours. The distinction between fibroadenomas and phyllodes tumors is clinically important. As, fibroadenomas may be safely followed without further investigation. But, phyllodes tumours require surgical management.

**Key words:** Phyllodes tumour, fibroadenoma, breast imaging

---

**Introduction:**

In this case we highlight issues surrounding the diagnosis, through an unusual case of transformation of fibroadenoma to unilateral, multifocal phyllodes tumour with calcification within. Reports of multifocal diseases are rare with only two cases of multifocality reported previously in the literature<sup>[1]</sup>. Phyllodes tumour, is a tumour of fibroepithelial cells with classically deep, leaf-like stromal fronds from which its name is derived<sup>[2]</sup>. It was first described by Johannes Müller in 1838, who coined the term “cystosarcoma phyllodes”. In total, more than 60 synonyms have been reported. But today, the World Health Organisation regards phyllodes tumour as the most appropriate nomenclature<sup>[3]</sup>. Triple assessment by clinical, radiological, and cytological or histological examination forms the fundamental basis for the evaluation of breast lumps. In our case, all three aspects were individually studied and were found to have a low sensitivity. Even in combination, the diagnostic accuracy is not very good<sup>[4]</sup>.

**Case presentation:**

We illustrate a case of 42 year old female, who had presented with rapidly progressive, multifocal disease of left breast. She had initially come with a biopsy proven fibroadenoma, which was excised in our hospital. She represented five years post surgery with two new lesions in the same breast. They had been present for some years but had now grown rapidly in size and were also intermittently painful. There was no associated pain, nipple discharge or skin involvement. No surrounding inflammation was observed. On palpation a bosselated swelling with variegated consistency was present in left breast. There were no palpable axillary lymph nodes. Opposite breast was lumpy with multiple, varying sized, firm swellings largest being approximately 1cm X 1cm in size.

Patient was subjected to a Mammogram which revealed, multiple (2), dense, round lesions with a radiolucent “halo” in left breast. On medio-lateral oblique (MLO) view [figure 1], the lesions had partially circumscribed margins and were located

in upper quadrant and lower retroareolar region. They were superimposed on each other in cranio-caudal(CC) view[figure2], seen predominantly in lateral and retroareolar region. There were coarse calcifications in regional distribution. Right Breast also showed multiple, round to oval shaped, poorly marginated lesions predominantly in upper lateral quadrant with amorphous calcification in segmental distribution.

Targeted ultrasonography of the lesion showed an oval, lobulated, circumscribed, isoechoic mass with cystic areas and fine low level moving internal echoes (s/o necrosis and haemorrhage). It measured 3.4cm x 2.0cm x 2.7cm. There was e/o a speck of calcification within. [figure3,figure4]. Right breast showed multiple, diffusely scattered, varying sized space occupying lesions (S.O.L.). Largest lesion measures 1.8x1.17cm and was at 9 O'clock position.

Breast MRI (performed on Philips 1.5T magnet, with T1,T2 sequences following i.v.gadolinium by patient weight) demonstrated a well-circumscribed, rounded predominantly isohypointense lesion on T1 and T2 WI with crescentic shaped, peripherally located hyperintense foci on T2WI. Slit-like hyperintense foci were noted in the center[figure5,figure6]. Another lesion of similar signal intensities was seen posteroinferior to the previously mentioned lesion[figure7]. On multiphase post-gadolinium augmented study, septae located in the centre of the lesion did not show any enhancement. Time-signal intensity kinetic curves reflected, a fast initial contrast enhancement with no washout in the later phases (Type I type of enhancement curve). Architectural distortion was observed, as the patient had been operated earlier for fibroadenoma. Right breast: showed features suggestive of fibrocystic disease. Histopathology

from lesion of left breast was found to be consistent with phyllodes tumour(borderline type).

#### **Discussion:**

Fibroadenoma transforming to phyllodes tumour is a very rare phenomenon with three cases reported by Noguchi et al.<sup>[5]</sup> and single case reported by Edna K Valdes et al.<sup>[6]</sup> Pacchiarotti A et al.<sup>[7]</sup> and Hodges KB et al.<sup>[8]</sup> each. Features suggestive of phyllodes are: older presentation (phyllodes being most common in 45–50 year old women)<sup>[9]</sup>, a large mass (phyllodes tending to be larger than fibroadenomas, up to 30 cm being commonly reported in the literature) and an increase in size of a previously stable mass. Tumours show no predilection for side but are more common in the upper half of the breast, particularly the upper outer quadrant (61%). Bilateral tumours are rare (1%). Though, both fibroadenoma and phyllodes tumour present as a firm, painless, smooth, well circumscribed and mobile mass; phyllodes tumour, usually grows rapidly to attain larger sizes at presentation and can occasionally cause pressure necrosis of overlying skin. Nipple retraction and bloody nipple discharge may occur when the tumour involves the areolar region<sup>[10]</sup>. In our case the lady was 42 years old, had also presented with a sudden increase in size of a previously stable lesion and the lesion is also located in predominantly in upper outer location. But, she had come with a painful lump in contrast to painless lump as has been described in literature.

Cosmacini et al.<sup>[11]</sup> observed mammograms of 99 patients from 1975-1989. They evaluated mammograms based on opacity, size, shape, margin characteristics, presence of calcifications and radiolucent halo and found that the most useful characteristics were opacity and the character of tumour's margins. They concluded by saying that mammographic features alone could not distinguish phyllodes tumour from fibroadenoma. Liberman et

al <sup>[12]</sup> studied 51 patients and showed a non spiculated soft-tissue mass in 49 cases of phyllodes tumour. According to them 3cm or greater dimension was associated with significantly higher likelihood of malignancy. Whereas, calcification was a pointer towards benignity. We gave BIRADS3 in our mammography report, keeping fibroadenoma as the first differential in view of calcification and phyllodes as second differential in view of the age and history.

On ultrasonography: lobulated shape (in some cases round or oval),well circumscribed smooth margins and echogenic rim are seen both in fibroadenoma and phyllodes tumour. Whereas, low level homogenous internal echoes, predominantly solid mass with fluid-filled clefts and lack of microcalcification are highly suggestive of phyllodes tumour<sup>[13,14]</sup>. Chao et al. <sup>[15]</sup> observed and compared sonographic features of phyllodes tumour and fibroadenoma during 1995-1998. A data from 110 phyllodes tumour and 2204 fibroadenomas was analysed. It was concluded that if lobulations, heterogenous hypoechoic internal echoes are observed and calcifications are absent, a diagnosis of phyllodes tumour should be considered. They concluded by saying that sonography cannot distinguish between the different types of phyllodes tumour. In our case, in view of fluid filled clefts and heterogenous internal echoes first differential of phyllodes was considered. But, presence of coarse calcification led us to consider involuting fibroadenoma with haemorrhage. Thus, the confusion of phyllodes tumour with fibroadenoma is understandable. This necessitated the need for Magnetic Resonance Imaging(MRI). Therefore, the role of dynamic breast MRI in differentiation and specification of phyllodes breast tumour was evaluated.

Wurdinger et al. <sup>[16]</sup> did a study to evaluate the MRI appearance of phyllodes tumour and to

differentiate them from fibroadenomas. MR images of 23 patients with 24 phyllodes breast tumours (one malignant, 23 benign) were compared with the MRI appearance of 81 fibroadenomas of 75 patients. Only one significant difference was noted. High signal intensity on T2-weighted images of surrounding breast tissue (i.e., a surrounding liquid accumulation) occurred significantly more often in phyllodes breast tumours than in fibroadenomas.

They also showed that round or lobulated shape, well-defined margins, heterogeneous internal structure, and nonenhancing internal septations are more common findings in phyllodes tumors than in fibroadenomas. Cysts and hemorrhage described as typical signs of phyllodes breast tumours are apparently due to rapid growth in size, with regressive changes occurring in larger tumours <sup>[17]</sup>. Our MRI findings were in accordance with those described in the literature for phyllodes tumour.

Buadu et al. <sup>[18]</sup> compared qualitative and quantitative magnetic resonance (MR) and mammographic features of breast lesions with histopathologic findings, especially tumor angiogenesis. They concluded that density and distribution of microvessels may play major roles in the determination of the initial rate of contrast medium uptake and the heterogeneity of tumor enhancement. In their study they demonstrated a different contrast enhancement pattern for a cystosarcoma phyllodes tumour and three benign phyllodes tumors.

Gary et al. <sup>[19]</sup> did MRI spectroscopy study on 19 carcinomas, 21 benign breast diseases and 6 phyllodes tumour. Spectroscopic results were positive for only for 17 out of 19 carcinoma patients. Thus, MR Spectroscopy could not aid in differentiating benign breast lesions and phyllodes tumour. Pierart et al. <sup>[20]</sup> reported that thermography can distinguish phyllodes from fibroadenomas by demonstrating increased heat

generation from the enhanced stromal cell activity seen in phyllodes tumours.

Phyllodes tumors are histologically similar to intracanalicular fibroadenomas<sup>[21]</sup>. Both consist of stromal and epithelial (ductal) structures originating from the terminal duct lobular unit. However, phyllodes tumors contain hypercellular stroma and a characteristic leaf like pattern, which differentiates them from fibroadenomas. In addition, phyllodes tumours often have irregular margins that can extend into adjacent mammary tissue<sup>[22]</sup>. Genetic clonal analysis have shown that a Fibroadenoma can transform into a benign or malignant phyllodes tumour<sup>[23]</sup>.

The efficacy of fine-needle aspiration in the diagnosis of phyllodes tumour have not been very useful. In one series, fine-needle aspiration failed to allow the correct diagnosis in 22% of cases<sup>[24]</sup>. Whereas, in a second series, fine needle aspiration was considered inadequate or nondiagnostic in 86% of cases<sup>[25]</sup>.

If tumours are small, besides fibroadenoma; the differentials should also include debris-laden cysts, and well-circumscribed carcinomas (including medullary, mucinous, and rarely invasive but not otherwise specified ductal carcinomas)<sup>[12]</sup>. Primary sarcomas cannot be differentiated mammographically from phyllodes tumors . Fibroadenomas can be safely followed

and if an excisional biopsy is needed, simple enucleation is adequate<sup>[26]</sup>. Phyllodes tumours, on the other hand require wide local excision as primary treatment. Total mastectomy is indicated only for very large tumours and for recurrences of borderline and malignant tumors.

#### **Conclusion:**

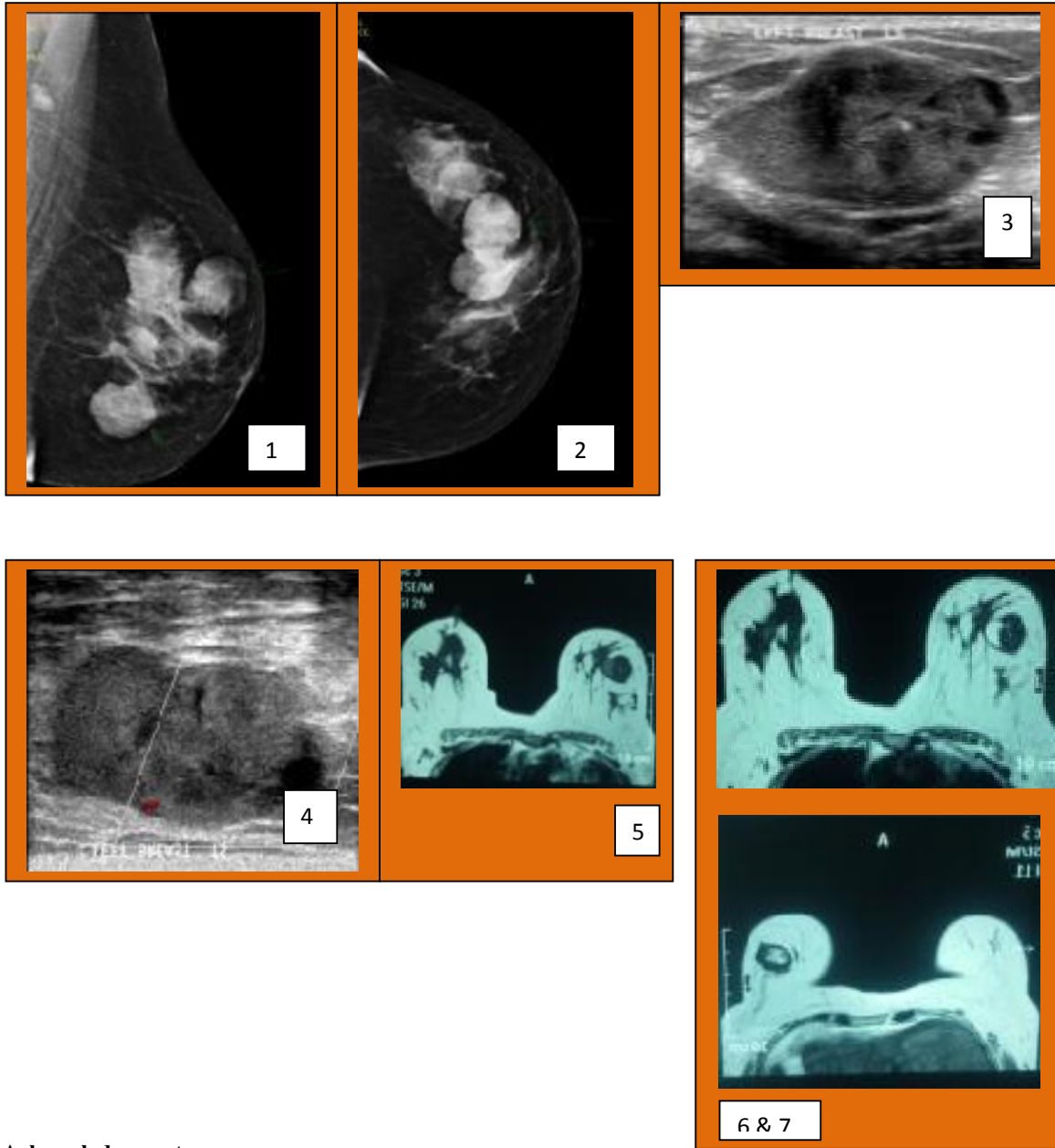
The transformation of fibroadenoma to Phyllodes tumour is rare. The 5-years period of stability in our case suggests that the timing of transformation is unpredictable. The present study emphasized a multidisciplinary approach to distinguish phyllodes tumour from fibroadenoma.

Clinical findings associated with the mass, particularly the symptom of breast pain and sudden increase in a previously dormant lesion should be documented. Mammographic finding of hyperdense lesion with a radiolucent "halo". Ultrasonographic characteristics, particularly the presence of clefts or cysts within solid mass and hyperintense cleft on T2 Weighted imaging should be all looked for carefully by radiologist. Pathologists should look for the key diagnostic features in the stromal components like- increased cellularity, pleomorphism, nuclear atypia and mitotic figures and then, make suggestions as to the most likely diagnosis. All these data could help the surgeon to decide whether the lesion should be surgically removed or followed up.

## **Indian Journal of Basic and Applied Medical Research**

Is now with

# **IC Value 91.48**



**Acknowledgements:**

We would like to thank our radiographer, Mrs.Kitty for helping us in data collection and for providing us with good quality radiographs.

**References:**

1. Salm R. Multifocal histogenesis of a cystosarcoma phyllodes. *Journal of Clinical Pathology*. 1978;31:897-903.
2. Azzopardi . Sarcoma in the breast. In: Bennington J., editor. *Problems in Pathology*. WB Saunders Co.; Philadelphia: 1979. pp. 355-359
3. World Health Organisation (1982) Histological typing of breast tumors. *Tumori*. 68:181-198.

4. Iau PTC, Lim TC, Png DJC, et al. (1998) Phyllodes tumour: an update of 40 cases. *Ann Acad Med Singapore* 27:200–203.
5. Noguchi S, Yokouchi H, Aihara T, Motomura K, Inaji H, Imaoka S, Koyama H. Progression of fibroadenoma to phyllodes tumour demonstrated by clonal analysis. *Cancer* 1995; 76: 1779-85.
6. Valdes EK, Boolbol SK, Cohen JM, Feldman SM. Malignant transformation of a breast fibroadenoma to cystosarcoma phylloides. *The Am Surg* 2005; 71(4): 348-353.
7. Pacchiarotti A, Frati P, Caserta D, Pacchiarotti A, Frega A, Moscarini M. First case of transformation for breast fibroadenoma to high-grade malignant cystosarcoma in an in vitro fertilization patient. *Fertil Steril*. 2011 Nov;96(5):1126-7.
8. Hodges KB, Abdul-Karim FW, Wang M, Lopez-Beltran A, Montironi R, Easley S, Zhang S, Wang N, MacLennan GT, Cheng L. Evidence for transformation of fibroadenoma of the breast to malignant phyllodes tumor. *Appl Immunohistochem Mol Morphol*. 2009 Jul;17(4):345-50.
9. Umpleby HC, Moore I, Royle GT, Guyer PB, Taylor I. An evaluation of the preoperative diagnosis and management of cystosarcoma phyllodes. *Ann R Coll Surg Engl* 1989; 71: 2858.
10. M.Larribe, J.Thomassin-Piana, A.Jalaguier-Coudray. 2013. Breast cancers with rounded lumps: Correlation between imaging and anatomopathology. *Diagnostic and Interventional Imaging*.
11. Cosmacini P, Zurrada S, Veronesi P, Bartoli C, Coopmans de Yoldi GF. Phyllodes tumor of breast: mammographic experience in 99 cases. *Eur J Radiol* 1992 Jul-Aug; 15(1):11-4.
12. Liberman L, Bonocccio E, Hamela-Bena D, Abramson AF, Cohen MA et al. Benign and malignant phyllodes tumors: mammographic and sonographic findings. *Radiology* 1996; 198(1):121-124.
13. Feder JM, de Paredes ES, Hogge JP, et al. Unusual breast lesions: radiologic/pathologic correlation. *Radiographics* 1999; 19:11–26.
14. Cole-Beuglet C, Soriano R, Kurtz AB, et al. Ultrasound, x-ray mammography, and histopathology of cystosarcoma phylloides. *Radiology* 1983; 146:481–6.
15. T.-C.Chao, Y.-F.Lo, S.-C.Chen and M.-F.Chen. Sonographic features of phyllodes tumors of the breast. *Ultrasound Obstet Gynecol* 2002; 20:64-71.
16. Susanne Wurdinger, Aimée B. Herzog, Dorothee R. Fischer, Christiane Marx, Gerd Raabe, Achim Schneider, Werner A. Kaiser. Differentiation of Phyllodes Breast Tumors from Fibroadenomas on MRI. *AJR* 2005; 185:1317–1321.
17. Farria DM, Gorczyca DP, Barsky SH, Sinha S, Basset LW. Benign phyllodes tumor of the breast: MR imaging features. *AJR* 1996; 167:187–189.
18. Buadu LD, Murakami J, Murayama S, et al. Breast lesions: correlation of contrast medium enhancement patterns on MR images with histopathologic findings and tumor angiogenesis. *Radiology* 1996; 200:639–649.
19. Gary M.K.Tse, Humairah S.C. et al. Characterization of Lesions of the Breast with Proton MR Spectroscopy: Comparison of Carcinomas, Benign Lesions and Phyllodes Tumours. *Tomors* November 2003, Volume 181, Number 5.
20. Pierart J, Burmeister R, Steinberg J, Schalperts J, Cid L. Use of thermography in the differential diagnosis of phylloides tumour. *Br J Surg* 1990; 77: 783-4.

21. Buchberger W, Strasser K, Heim K, Muller E, Schreksnadel H. Phyllodes tumor: findings on mammography, sonography, and aspiration cytology in 10 cases. *AJR* 1991; 157:715-719.
22. Sewell CW. Pathology of benign and malignant breast disorders. *Radiol Clin North Am* 1995; 33:1067-1080.
23. Valdes EK, Boolbol SK, Cohen J-M, et al. Malignant transformation of a breast fibroadenoma to cystosarcoma phyllodes: case report and review of the literature. *Am Surg* 2005; 71: 348–353.
24. Stanley MW, Tani EM, Rutqvist LE, et al. Cystosarcoma phyllodes of the breast: a cytological and clinicopathologic study of 23 cases. *Diagn Cytopathol* 1989; 5:29-34.
25. Salvadori B, Cusumano F, Del Bo R, et al. Surgical treatment of phyllodes tumors of the breast. *Cancer* 1989; 63:2532-2536.
26. Jacklin RK, Ridgway PF, Ziprin P, Healy V, Hadjiminias D, Darzi A. Optimising preoperative diagnosis in phyllodes tumour of the breast. *J Clin Pathol* 2006; 59:454–459.