

Case Report

Rare clinical entity- Fibroadenoma of ectopic breast tissue

Dr Supreethi Kohli, Dr Pragya Garg, Dr Suman Kharkwal, Dr Anand Kumar Verma

Name of the Institute/college: . Post Graduate Institute Of Medical Science And Research(P.G.I.M.S.R). and Employee State Insurance(E.S.I)Model Hospital

Corresponding author: Dr Pragya Garg

Abstract:

A 34 year old female presented with bilateral axillary masses, of 1 year duration. The masses exhibited similar consistency to adjacent breast tissue but lacked an associated nipple complex. The clinical impression was lipoma; however mammography and ultrasonography revealed ectopic breast tissue with fibroadenoma. Ectopic breast tissue(EBT) may constitute a diagnostic challenge and is often misdiagnosed as lipoma, follicular cyst or lymphadenopathy. In addition, some studies have suggested that ectopic breast tissue may be at higher risks of malignant degeneration. Therefore it's important that physicians be familiar with this condition as this may contribute to the early detection of ectopic breast cancer.

Keywords: Ectopic breast tissue, axillary breast, fibroadenoma.

Introduction:

Accessory breast tissue is defined as “residual [breast] tissue that persists from normal embryologic development”.^[1] Also known as ectopic breast tissue, accessory breast tissue can be found in up to 6% of the population.^[2] The term “aberrant breast tissue” is defined as “an island of breast tissue usually located in proximity to the normal breast” and consist of accessory fragments of breast tissue outside the periphery of the gland.^[3] More specifically, ectopic breast tissue[EBT] is an umbrella term that refers to both supernumerary breasts as well as aberrant breast tissue.^[4] Fibroadenoma is a common benign lesion of normal breast tissue. Its occurrence in accessory breast tissue is very rare and only few cases have been reported in the literature. They are clinically significant as they are associated with other congenital anomalies of the urinary and cardiovascular systems.^[5,6]

Case Report:

A 34 year-old female presented with bilateral subcutaneous axillary swellings of 1 year duration. The swellings were gradually increasing in size and were associated with pain and discomfort. The patient had no personal or family history of breast cancer. The breasts were bilaterally symmetrical, with no lump or nipple discharge. Examination of axilla on right side revealed a swelling of 6cm x 5cm in size. On palpation a freely mobile lump was felt within soft boggy mass which measured approximately 3cm x 3cm. Rest of the swelling was soft and tender. In the axilla on left side, the swelling was completely boggy and measured 4 cm x 4 cm. Skin over both the axillary swellings was normal. No nipple or areola were identified clinically at both the sites.

Mammogram of both pectoral breasts was normal. The right axilla demonstrated an oval, well circumscribed lesion, isodense to breast parenchyma measuring 2.5cm x 1.4 cm. There was no calcification within the mass. Skin overlying the lesion was normal. No nipple was identified over the swelling [Figure1]. Ultrasonogram of

the right axilla showed an oval, well circumscribed, smoothly marginated ,isoechoic space occupying lesion ,measuring 2.8 cm x 1.6cm. A thin layer of echogenic tissue discontinuous with pectoral breast,but resembling normal mammary tissue s/o ectopic breast was identified around the lesion. [Figure 2]. Color flow Doppler study showed low vascularity in the lesion, characteristic of fibroadenoma.Left axilla showed a predominantly hyper echoic lesion ,consistent with fat. Both pectoral breasts were normal.The lesion was classified as Breast Imaging Reporting and Data System(BI-RADS)2. Ultrasonography of both urogenital and cardiovascular system was normal. Fine needle aspiration cytology was done and a diagnosis of fibroadenoma with no malignant change was made. Both axillary breasts were excised under general anaesthesia and all clinically visible tumor was totally excised. The surgical excision of the lump showed a whitish cut surface [Figure 3]. The sections taken from the mass revealed ductules lined by cuboidal epithelial cells resting on myoepithelial cell layer surrounded by abundant loose fibrous tissue . The histopathological picture showed fibroadenoma arising in normal breast tissue [Figure4].

Discussion:

Fibroadenomas are a frequent cause of nodules and lumps in young women, with the highest incidence between 20 and 30 years of age. Fibroadenomas are rarely described in EBT. Sawa et al.^[7] reported a case involving a fibroadenoma in an axillary accessory breast in a 41-year-old woman who presented with a right axillary mass associated with 5 small nodules in the normally situated breast. Coras et al.^[8] reported a fibroadenoma in the axillary accessory breast of a 23-year-old woman which was histologically identical to the fibroadenomas existing in the breast.

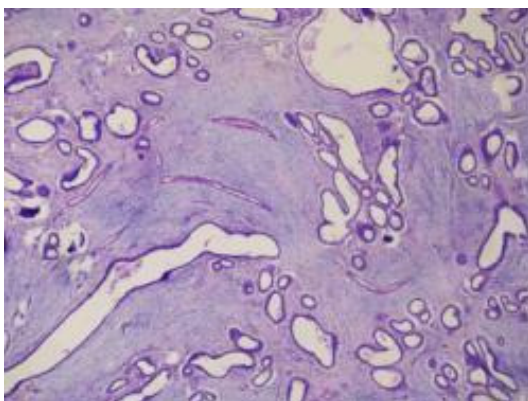
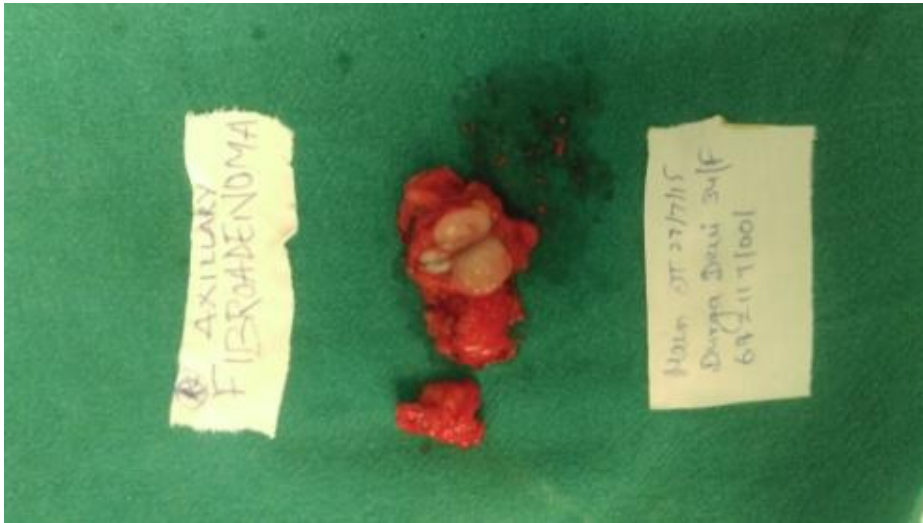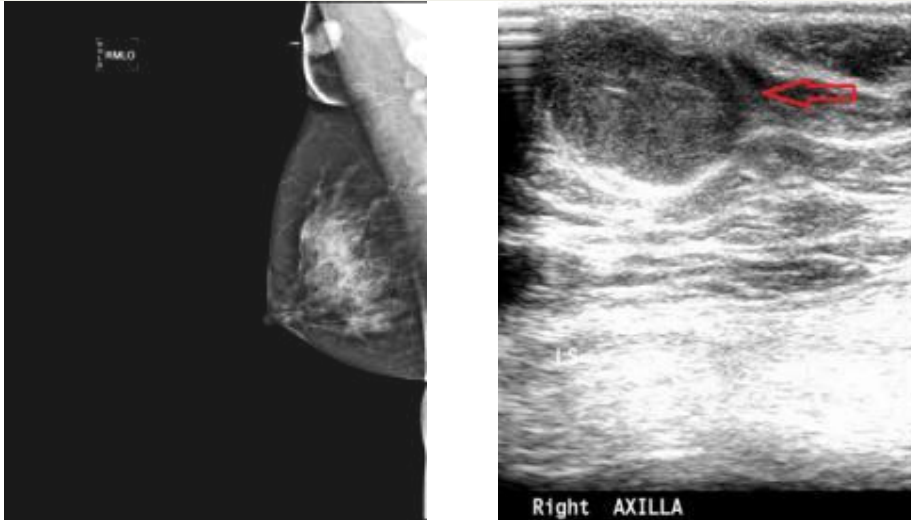
Ultrasound is usually the first-choice imaging modality for evaluation of any palpable soft-tissue mass outside the breast and may be the imaging modality of initial choice for a palpable breast mass if the patient is younger than 30 years old.^[9] On ultrasound, EBT is visualized as an echogenic area with the same appearance as normal glandular tissue Mammogram shows patch of pliable fibroglandular tissue with interspersed fat discontinuous with majority of breast tissue more inferiorly, which is consistent with accessory breast tissue. On MRI, accessory breast tissue can appear as a subcutaneous ill-defined mass or non mass like area that has signal intensity and contrast enhancement similar to the rest of the breast parenchyma but is discontinuous with that tissue.

A relatively frequent sighting is the axillary tail of Spence, which is a continuous extension of the tissue of the breast that extends into the axilla. Whereas, accessory breast tissue in the axilla is discontinuous with the main breast parenchyma.^[10] In our case, we first ruled out malignant disease because of the clear margins. Enlargement of lymph nodes is often present as a hyperechoic hilum. Lipomas are often isoechoic or hypoechoic to the surrounding fat . Neuromas are derived from the sheaths of peripheral nerves. Neuromas are usually located intracutaneously, and less frequently subcutaneously. The sonograms depicting epidermal inclusion cysts show a smoothly marginated, complex-echo mass with good through-transmission, and extension of the mass into the dermal layer. Mammographically ,the lesion was well defined, isodense and smoothly marginated leading to a diagnosis of benign lesion and the axillary breast tissue was discontinuous with pectoral breast tissue.

Conclusion:

Ectopic breast is common in masses of the axilla and malignant and benign tumors may develop from this lesion. One of the benign lesions is fibroadenoma, but its location in the axilla is rare It is clinically wise to

evaluate and screen carefully cases of supernumerary breast for any pathology and for any associated urogenital anomalies. FNAC is very valuable in diagnosing the lesion in EBT. Excision is the only treatment of choice for symptomatic EBT.



Source(s) of support:

Department of Radio-diagnosis, Department of Surgery and Department of pathology. Post Graduate Institute Of Medical Science And Research (P.G.I.M.S.R). and Employee State Insurance (E.S.I) Model Hospital.

References

1. Laor T, Collins MH, Emery KH, Donnelly LF, Bove KE, Ballard ET. MRI appearance of accessory breast tissue: a diagnostic consideration for an axillary mass in a peripubertal or pubertal girl. *AJR* 2004; 183:1779–1781.
2. Goyal S, Puri T, Gupta R, Julka P, Rath G. Accessory breast tissue in axilla masquerading as breast cancer recurrence. *J Cancer Res Ther* 2008; 4:95–96.
3. Marshall MB, Moynihan JJ, Frost A, Evans SR. Ectopic breast cancer: case report and literature review. *Surg Oncol* 1994; 3:295–304.
4. Bakker JR, Sataloff DM, Haupt HM. Breast cancer presenting in aberrant axillary breast tissue. *Commun Oncol* 2005; 2:117–120.
5. Grossl NA. Supernumerary breast tissue: Historical perspective and clinical features. *South Med J* 2000; 93:29–32.
6. Mukhopadhyay M, Saha AK, Sarkar A. Fibroadenoma of the ectopic breast of axilla. *Indian J Surg* 2010; 72:143–145.
7. Sawa, M., Kawai, N., Sato, M., Takeuchi, T., Tamaki, T. and Oura, S. Fibroadenoma of the Axillary Accessory Breast: Diagnostic Value of Dynamic Magnetic Resonance Imaging. *Japanese Journal of Radiology* 2010; 28: 613–617.
8. Coras, B., Landthaler, M., Hofstaedter, F., Meisel, C. and Hohenleutner, U. Fibroadenoma of the Axilla. *Dermatologic Surgery* 2005; 31: 1152–1154.
9. American College of Radiology website. ACR Appropriateness Criteria for palpable breast masses. . Published 1996. Updated 2012. Accessed June 27, 2013.
10. Adler DD, Rebner M, Pennes DR. Accessory breast tissue in the axilla: mammographic appearance. *Radiology* 1987; 163:709–711.