

Case report:

Anomalous origin and anomalous course of v1 segment of left vertebral artery

Dr. B. Anbumalar

Assistant Professor, Department of Anatomy,
Govt. Stanley Medical College,
Chennai – 600001, Tamilnadu, India
Corresponding author: Dr. B. Anbumalar

Abstract

Arterial anomalies are common in the thorax, head and neck region. The Vertebral artery is important to posterior cerebral circulation. Several researchers have reported abnormal origin and course of Vertebral artery. The anatomical variation of Vertebral arteries are significant for diagnostic and interventional procedures in the head and neck region. The present study reports the anomalous origin of the Left Vertebral artery along with variation in the course of V1 segment of the same artery, entering the foramen transversorium of the fourth Cervical Vertebra.

Key words : Left Vertebral artery, Aortic arch, Cervical vertebra, Foramen transversorium

Introduction

The Vertebral artery is mainly distributed to the brain. It arises from the superoposterior aspect of the first part of Subclavian artery. It passes through the foramina in the transverse process of all the cervical vertebrae except the seventh, curves medially behind the lateral mass of the atlas and enters the cranium via the foramen magnum. At the lower border of pons, it joins its fellow to form the Basilar artery. Occasionally it may enter the cervical column via the fourth, fifth or seventh Cervical Vertebrae. In the present study, the Left Vertebral artery originated directly from the Aortic arch between the Left Common Carotid artery and the Left Subclavian artery. In addition to that the V1 segment of the Left Vertebral artery had a unusual entry through the foramen transversorium of the fourth Cervical Vertebra.

Case report

The present observation was made during the routine dissection for undergraduate students, in the department of anatomy, Stanley medical college, Chennai, in 2014-15. In a 56 year old male cadaver it was found that the Left Vertebral artery arose directly from the Aortic arch unusually and v1 segment of the same artery followed an unusual course to enter foramen transversorium of fourth Cervical Vertebra. However, the origin and course of the Right Vertebral artery was normal.

Discussion

(i) Abnormal origin of Left Vertebral artery :

Gray's anatomy (2010), G.J. Romanes (1993), Last's (2011) stated that the Vertebral artery arises from the first part of the Subclavian artery. R.K. Singla (2010) suggested that nearly 3.1 – 8.3% of aortic origin of vertebral artery reported by several authors.

R.K. Shetty (2013), in a case study reported origin of left vertebral artery from arch of aorta.

Comparative study of anomalous origin of vertebral arteries from aortic arch is given in table 1

Table 1: Incidence of aortic origin of vertebral artery

Authors (Year)	Percentage (%)
Adachi (1928)	5.4
Anitha (2012)	2
Fischer's (2012)	5
Jayanthi (2010)	5
Nurcan imre (2010)	2.5
Panicker (2002)	5
Pillai.T.J(2014)	8.3
Rutherford (2010)	6
Surya .E(2014)	16.67

(ii) Abnormal course of Left Vertebral artery : Keith. L Moore (2011), Kadasne (2009) mentioned that the vertebral artery may enter the higher vertebrae. Hollinshed(1997) stated that sometimes the vertebral artery enters the higher vertebrae, but very rarely the lower vertebra. Various studies done on the variation of vertebral artery entering the foramina transversoria of cervical vertebrae is given table 2.

Table 2: Incidence of abnormal course of ‘V1’ segment of Vertebral artery

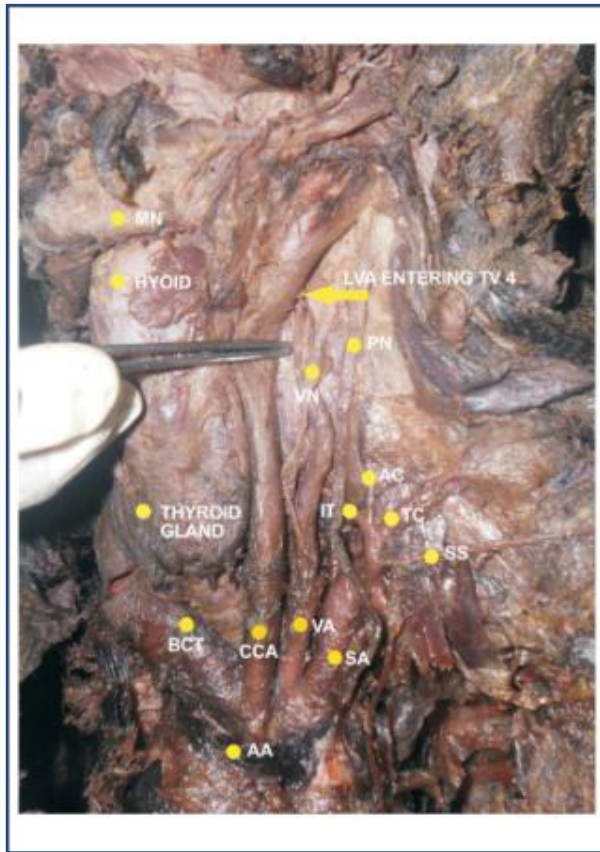
Authors (year)	Incidence of Vertebral artery entering various cervical vertebrae (%)					FT of
	CV7	CV6	CV5	CV4	CV3	
Adachi(1928)	1.2	93.6	4.5	0.7		
Aprajita(2012)	0.3	94.9	3.3	1.6		0
Bruneau.M(2006)	0.8	93	5	1		0.2
Gray’s (2010)	2	90	5	2		1
Pillai.T.J(2014)	0	91.7	8.3	0		0
Ranganatha sastry(2006)	18.42	71	5.3	2.6		2.6
Rawal.D.Jidendra (2012)	8	92	0	0		0
Rieger&Hubner (1983)	5.4	87.5	6.6	0.5		0

Embryological basis

The Vertebral artery is a composite artery develops from dorsal ramous of seventh intersegmental artery and from series of dorsal rami of dorsal intersegmental arteries of cervical region. Except the seventh intersegmental artery, rest of the cervical arteries regress and are modified to form the vertebral artery. In the present case, the left sixth dorsal intersegmental artery might have persisted as the first part of vertebral artery, so left vertebral artery was arising from the arch of aorta directly.

Conclusion

Anomalies in the origin and course of left Vertebral artery have been studied and documented by several researchers. The knowledge about variation in the origin and course of vertebral arteries are important for diagnostic and surgical interventions in the head and neck region, to avoid critical complications.



References

1. Adachi.B. Das Arterien System der Japaner :vol 1 Kankyusha Press,Kyoto,Japan,1928;138- 154
2. Anitha .V,Abnormal origin of vertebral Artery, international journal of Anatomical Sciences,2012,3(1):01-03
3. Aprajitha sikka et al, Bilateral variation in origin and course of vertebral artery,Anatomy research international vol.2012,artID580765,3 pages
4. Bruneau.M.et al,Anatomical variations of the V1 segment of the
5. A.K.Dutta,Essentials of Human Embryology, 6th edition, 2010, pg 181-183
6. Fischer's - Mastery of surgery,6th edition vol.2:Josef E Fischer (2012);p-2175
7. Gray 's anatomy- The anatomical basis of clinical practice ,40th edition,Susan Standring (2010);pg-449
8. Hollinshed's Textbook of Anatomy,5th Edition,Cornelius Rosse, 1997, pg 725,726
9. Jayanthi.V.et al, Anomalous origin of the left vertebral artery from arch of aorta:A case report, Folia Morphol,2010,vol.69,no 4,pg 258-260
10. Kadasne's textbook of Anatomy, Vol 3,D.K.Kadasne,2009, pg 908-909
11. Keith.L.Moore,Essentials clinical anatomy,4th Edition,2011, pg 615
12. Nurcan Imre et al; unusual origin of left vertebral artery – A Case report, international journal of Anatomical variations,,2010, 3;80-83
13. Panicker.H.K.et al, Anomalous origin of left vertebral artery, J.Anat. Soc. India 51(2) 234-235 (2002)
14. Pillai.T.J et al,Abnormal origin and course of Left Vertebral Artery,International journal of Research Studies in Biosciences,vol2,Issue 8,2014, pg 17-19

14. Ranganatha Sastry.V. et al, annal sofian.org,The course of the V1 segment of the Vertebral artery,2006, vol9 ,issue 4,pg 223- 226
15. Rawal.D.Jitendra et al, Anatomical study of variation of VA entering the Foramen Transversoria of cervical vertebrae, National journal of medical research,vol2, Issue 2,2012, pg 199-201
16. Rieger P & Huber G, Fenestration and Duplicate origin of the Left Vertebral Artery in angiography, Neuroradiology, 1983,25; 45-50 (Pubmed)
18. Romanes. G.J.Cunningham's manual of practical anatomy (1993), 15th Edition, vol 3,pg- 70-94
19. Rutherford's Vascular surgery -7th Edition, vol 2 ,(2010) pg 1531- 1532
20. R.K. Shetty et al, Abnormal origin of the Left Vertebral Artery - A Case report, International journal of Biomedical Research, 2013,04(05)
21. R.K.Singla et al, Variant origin of Left Vertebral Artery - A Case report, International Journal of Anatomical Variations (2010)3: 97-99