

Case Report:

Nasopharyngeal angiofibroma- Case report

Dr. Yash Devckar, Dr. A. Lathi, Dr. K. Shinde, Dr. S. Kishve, Dr. C. Anand, Dr. P. Saha, Dr. V. Chaudhary, Dr. K. Sankhe

Department of ENT, Rural Medical College, Loni, Rahata, Ahmednagar 413736

Corresponding author: Dr. Yash Devckar

Abstract

Nasopharyngeal angiofibroma is a rare, benign, locally invasive tumor that accounts for less than 0.5% of head and neck tumors. The common age group affected being adolescent. It is even rarer in age group above 20 yrs. Other terms used for this tumor are bleeding fibroma of the adolescent, and fibroangioma. In this paper we present a very rare case of an Angiofibroma in a 50 years old male patient.

Keywords: Nasopharyngeal angiofibroma

Introduction

Nasopharyngeal angiofibroma is a rare, benign, locally invasive tumor that accounts for less than 0.5% of head and neck tumors. Hippocrates describes this tumor in 5th century and Friedberg first used the term “angiofibroma” in 1940. Nasopharyngeal angiofibroma (JNA) occurs almost exclusively in male teenagers.(1) The tumor contains both vascular and fibrous elements intermingling together. The site of origin of JNA remains controversial. According to some authors, it originates from the superior lip of the sphenopalatine foramen at the junction of the pterygoid process of the sphenoid bone and the sphenoid process of the palatine bone but, others

believe that it arises from the bone of the vidian canal.

The blood supply to these benign tumors is most commonly from the internal maxillary artery, but may also be supplied by the external carotid artery, the internal carotid artery, the common carotid artery, or the ascending pharyngeal artery.(2) The tumor lacks a capsule and spreads submucosally. Angiofibromas are slow growing and initially expand intranasally into the nasopharynx and nasal cavity and then into the pterygomaxillary space. Over time, JNAs will eventually erode bone and invade the infratemporal fossa, orbit, and middle cranial fossa.(3)

Indian Journal of Basic and Applied Medical Research

Is now with

Impact Factor: 0.34 (2014)

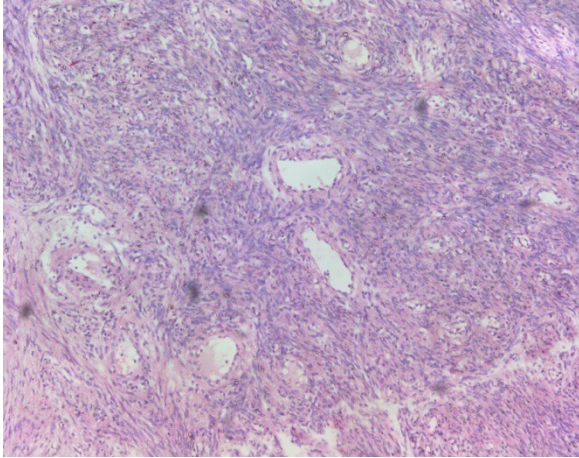


Fig.1

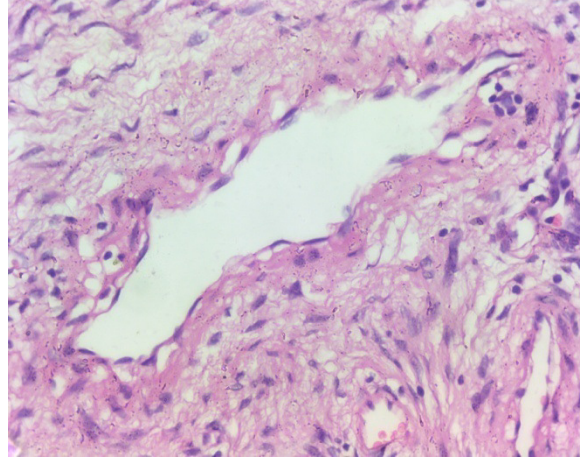


Fig.2

Case Report

A 50 years old, male patient presented with the chief complaint of right sided nasal obstruction since 6 months and bleeding from right nostril since 2 months. The nasal obstruction was progressive with no relieving factors. The epistaxis was recurrent and stopped on its own, with 1-2 episodes occurring per week. On clinical examination, a pinkish solid mass was seen in the oropharynx extending upto the level of epiglottis. Posterior rhinoscopy revealed the mass, seen arising from the posterior end of the middle turbinate extending into the nasopharynx. MRI revealed a mass in the nasopharynx extending into right nasal cavity and inferiorly into the oropharynx upto the level of epiglottis. No erosion or extension into the parapharyngeal space nor any intracranial extension was seen.

Based on clinical examination and history, an angiofibroma was suspected and mass was excised through a lateral rhinotomy incision. Intraoperatively mass was confirmed to be arising from the posterior end of the middle turbinate. The excised soft tissue specimen was greyish white firm with size of 6x3 cms. Microscopy showed tissue with abundant fibrous stroma and intermixed with blood vessels.

Vessels were of varied calibre and irregular shaped.(Fig.1) Vessels had an incomplete muscle coat.(Fig.2) Based on clinical, radiological and histopathological findings, the mass was diagnosed as a nasopharyngeal fibroangioma.

Discussion

Nasopharyngeal angiofibromas are benign tumors that are life threatening because of the vascularity and location.(4) They account for 0.5% of all head and neck neoplasms. The tumors develop almost exclusively in adolescent boys.(1)(5) Average age of onset is 15 years which ranges from 9-28 yrs.(2) Patients above this age group have been very sporadically reported in literature. According to some authors, it originates from the superior lip of the sphenopalatine foramen at the junction of the pterygoid process of the sphenoid bone and the sphenoid process of the palatine bone but, others believe that it arises from the bone of the vidian canal. Very rarely, it originates from other sites.(6) Other sites which can be involved include maxillary sinus, ethmoid sinus, sphenoid sinus, nasal septum, middle turbinate, inferior turbinate, pterygomaxillary fissure, and infratemporal fossa and laryngotracheal tree. Clinically, the tumor is a red polypoid tissue

which may protrude into the anterior nasal cavity or into the pharynx. On examination, tumor may be noticed as nasal mass (80%), orbital mass (15%), proptosis (10- 15%). The tumor does not cause pain but it is manifested by nasal obstruction (80-90%), epistaxis (45-60%), sinusitis & headache (25%), facial swelling (10-18%). Intra-Oral Manifestations of JNA is palatal or tonsillar mass with nasal obstruction. Occasionally, swelling of posterior portion of maxilla may be seen.(3)

On macroscopic examination, the angiofibroma is lobulated in appearance and its consistency ranges from spongy to a varying degree of firmness depending on the proportion of vascular tissue and fibrous component that forms the tumour. Microscopically, tumour is unencapsulated and formed by numerous blood vessels of varying calibre coursing through a fibrous tissue stroma. The thickness of the muscular coat of these vessels varies and in general elastic fibres in these vessels are lacking, thus the ability to retract is reduced.(7)

Main stay of treatment for an angiofibroma is surgical excision through various approaches like transpalatal – Wilsons approach, transpalatal and sublabial, transantral - Denkers procedure and lateral rhinotomy with medial maxillectomy.(8) Radiotherapy is indicated when there is orbital involvement or intracranial extension or in cases of recurrence or residual disease, also it can be used to preoperatively shrink the tumor. 3000-3500 cGy is given over 3 weeks. Chemotherapy with Doxorubicin- 60 mg/m²IV 1ST day or Vincristine-2 mg/m²IV once a week for 12 weeks can be given. Oestrogen therapy or embolization can be used to reduce vascularity of the tumor. (9)

Conclusion

Nasopharyngeal angiofibroma is a very rare tumor. Even more rare in patients in 6th decade of age. Also, an angiofibroma arising from the middle turbinate is a rare entity. Thus, angiofibroma should not be ruled out from your differential diagnosis even in patients of older the age groups.

References

1. Hauptman, Garrett; Ulualp, Seckin; Quinn FB. Juvenile Nasopharyngeal Angiofibroma SOURCE : Grand Rounds Presentation , UTMB , Dept . of Otolaryngology DATE : January 3 , 2007 RESIDENT PHYSICIAN : Garrett Hauptman , MD FACULTY PHYSICIAN : Seckin Ulualp , MD SERIES EDITORS : Francis B . Quinn. Gd Rounds Present , UTMB. 2007;
2. Gupta, AK; Bansal S. Nasopharyngeal Angiofibroma — Staging and Selecting a Surgical Approach : Changing Trends. Clin Rhinol An Int J. 2009;2(December):5–10.
3. Harrison DF. The natural history, pathogenesis, and treatment of juvenile angiofibroma. Personal experience with 44 patients. Arch Otolaryngol Head Neck Surg [Internet]. 1987 Sep [cited 2014 Nov 8];113(9):936–42. Available from: <http://www.ncbi.nlm.nih.gov/pubmed/3038146>
4. Hiraide F, Matsubara H. Juvenile nasal angiofibroma: a case report. Arch Otorhinolaryngol [Internet]. 1984 Jan [cited 2014 Nov 8];239(3):235–41. Available from: <http://www.ncbi.nlm.nih.gov/pubmed/6329151>
5. Lund VJ, Stammberger H, Nicolai P, Castelnovo P, Beal T, Beham A, et al. European position paper on endoscopic management of tumours of the nose, paranasal sinuses and skull base. Rhinol Suppl [Internet]. 2010 Jan [cited 2014 Oct 31];(22):1–143. Available from: <http://www.ncbi.nlm.nih.gov/pubmed/20502772>

6. Sinha R, Das S, Ray S, Banerjee P, Sadhu P. Nasopharyngeal angiofibroma: rare presentations. *Ear Nose Throat J* [Internet]. 2008 Dec [cited 2014 Nov 8];87(12):E26. Available from: <http://www.ncbi.nlm.nih.gov/pubmed/19105131>
7. Stiller D, Küttner K. [Growth patterns of juvenile nasopharyngeal fibromas. A histological analysis on the basis of 40 cases]. *Zentralblatt für Allg Pathol u Pathol Anat* [Internet]. 1988 Jan [cited 2014 Nov 8];134(4-5):409–22. Available from: <http://www.ncbi.nlm.nih.gov/pubmed/2849264>
8. Mistry R, Qureshi S, Gupta S, Gupta S. Juvenile nasopharyngeal angiofibroma: A single institution study. *Indian J Cancer* [Internet]. 2005;42(1):35. Available from: <http://www.indianjcancer.com/text.asp?2005/42/1/35/15098>
9. Bremer JW, Neel HB, DeSanto LW, Jones GC. Angiofibroma: treatment trends in 150 patients during 40 years. *Laryngoscope* [Internet]. 1986 Dec [cited 2014 Nov 8];96(12):1321–9. Available from: <http://www.ncbi.nlm.nih.gov/pubmed/3023771>