

Case report

Knee swelling

Shrinivasan.S¹, Chidambaram. R¹, Vijayaragavan.R², Thirugnanasambanthan²

¹Assistant Professor ,Department of Radiology,²Department of Orthopaedics,Sri Lakshmi Narayana Institute of Medical Sciences,Agaram Village, Affiliated to Bharath University, Chennai, Puducherry- 605502, India.

Corresponding author: Dr.S.Shrinivasan

Abstract

A swollen knee is a common problem. Swelling may be acute or chronic. It may be associated with a recent injury or may have a gradual onset. The swelling can be within the knee joint or around the knee in the soft-tissues. When fluid is outside the joint space, and in the soft tissues surrounding the knee, the most common cause is Bursitis. We discuss the imaging findings of a 80 years old male presented with osteoarthritis changes and multiple soft tissue swellings around both knee joint.

Key words: Knee Swelling, Bursitis, synovial cyst, Housemaid and Clergyman's knee

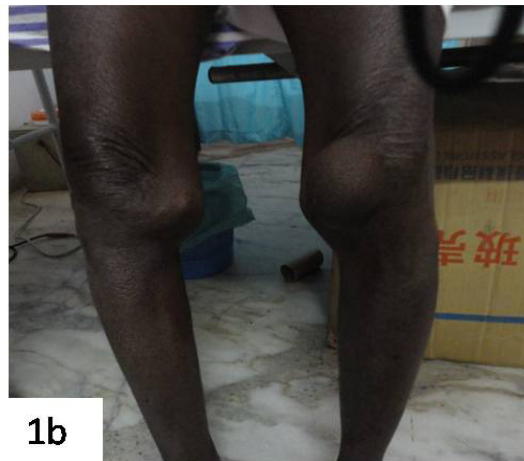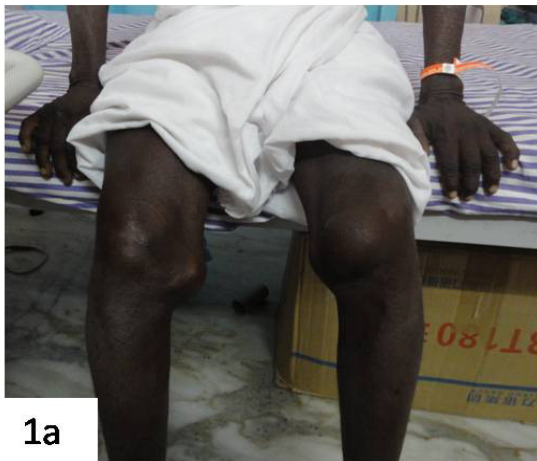Introduction

A swollen knee occurs when excess fluid accumulates in or around the knee joint. The knee joint is surrounded by a capsule. This capsule forms the "joint space." which has a small amount of lubricating fluid called synovial fluid . Some conditions cause an accumulation of this fluid called a knee effusion. When fluid is outside of the actual joint space, and in the soft tissues surrounding the knee, the most common cause is Bursitis. A Bursa is a fluid-filled structure present between the skin and tendon or tendon and bone. The main function of a bursa is to reduce friction and typically located around large joints such as the shoulder, knee, hip, and elbow.¹ Trauma, infection, overuse, and hemorrhage are some of the common causes for inflammation.² Other causes include systemic illness like collagen vascular disease and inflammatory arthropathy; in some instances the cause is unknown.³

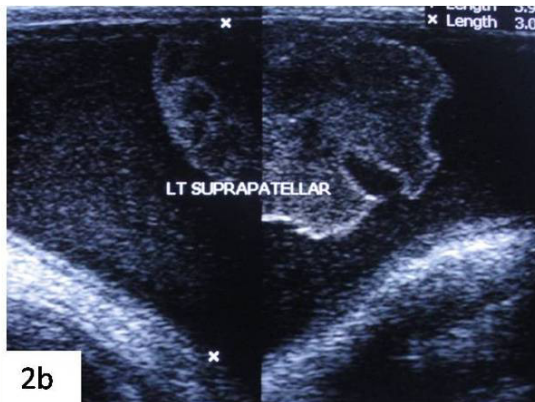
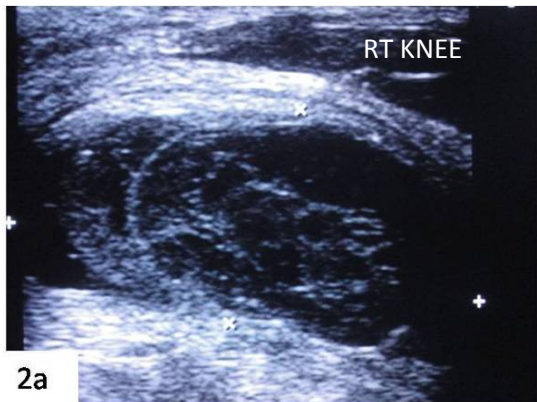
Ultrasonography (USG) and magnetic resonance imaging (MRI) are the most useful imaging modalities which helps in evaluating these cystic lesions.

Case Report

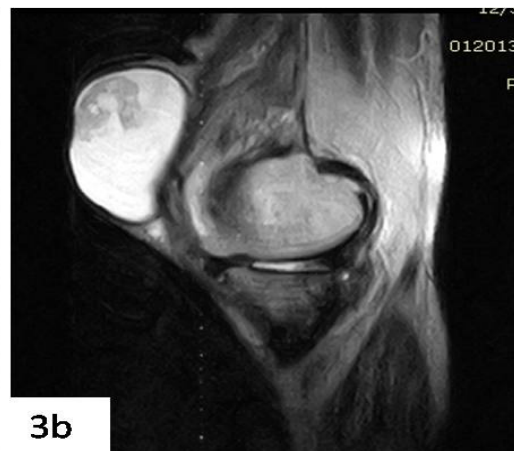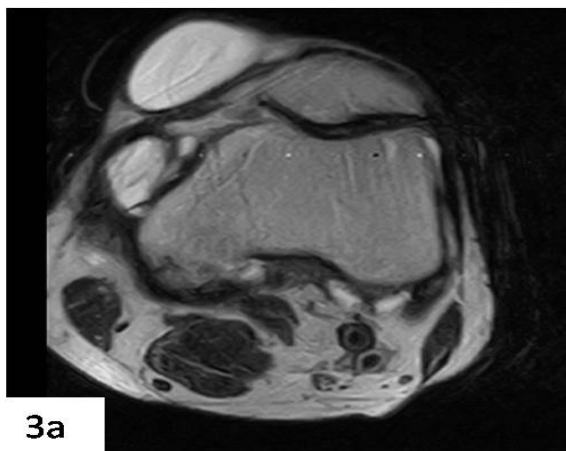
Here we present a case of eighty years old male presented with complaints of difficulty in walking due to chronic knee pain and swellings around the knee joint on both sides for last two years. Initially the swellings were painless, smaller in size and subsequently shows gradual increase in size. On examination, the swellings around knee joints appear smooth marginated, cystic, non-tender and in subcutaneous region. The swelling was seen in medial aspect of right knee and in both pre/intra patellar region of left knee (Fig 1a,b)which was clinically diagnosed as Bursitis.(Housemaid, Clergyman Knee)

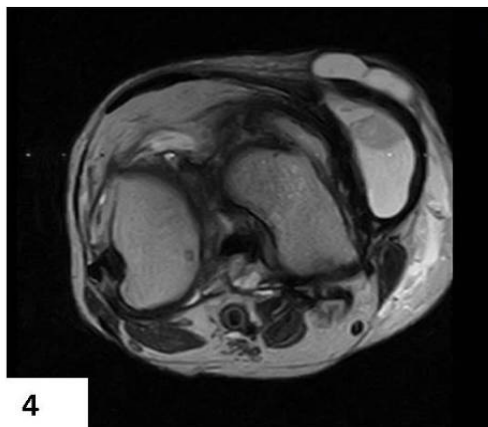


Ultrasonography of both knee (Fig2a,b) was done as first line of investigation which shows thick walled subcutaneous cystic lesion with floating internal echoes and membranes reflecting the chronicity of Bursitis.



Magnetic resonance imaging was also done where T2W axial and sagittal sections shows well defined smooth marginated T2 Hyperintense cystic lesion in left pre-patellar and medial infrapatellar region(Fig 3a,b).Axial T2W image (Fig 4) of right knee shows thick walled bursitis in infra-patellar region at medial aspect.





Discussion

The bursae of the knee are the fluid sacs and synovial pockets that surround and sometimes communicate with the joint cavity. When a bursa becomes inflamed, the condition is known as Bursitis. Bursae around the patella include the prepatellar bursa, the superficial and deep infrapatellar bursae, and the suprapatellar bursa. Bursae that are not anatomically close to the patella include the pes anserine bursa, the iliotibial bursa, the tibial and fibular collateral ligament bursae and the gastrocnemius-semimembranosus bursa.⁴ During embryologic development, the septum separating the suprapatellar bursa from the remainder of the joint will perforate and involute, leaving only a small transverse residuum of the septum.⁵Prepatellar bursitis, sometimes referred to as carpet-layer or housemaids knee, results from the bursa undergoing repetitive compressive and shear forces between the skin and the patella owing to the positioning the individual's weight on to the anterior knee over the patella. The superficial infrapatellar bursa, or pretibial bursa, resides within the subcutaneous fat superficial to the tibial tuberosity at the level of the distal patellar tendon.^{6,7}USG can distinguish cysts from solid

lesions and assess the degree of vascularity within the lesion. MRI can help delineate the location of the lesion in relation to anatomic structures .MRI with its multiplanar imaging capability shows internal derangement and associated osteoarthritis changes. When a bursa is not only inflamed but also infected, it is called septic bursitis. Unlike most cases of aseptic bursitis, septic bursitis is a potentially serious medical condition. Post-Gado contrast MRI can distinguish infective septic arthritis from other non-inflammatory conditions.

Most patients with bursitis are treated conservatively to reduce inflammation. Conservative treatment includes rest, cold and heat treatments, elevation, administration of non steroidal anti-inflammatory drugs (NSAIDs), bursal aspiration, and intrabursal steroid injections (with or without local anesthetic agents).⁸Patients with suspected septic bursitis should be treated with antibiotics while awaiting culture results. Surgical excision of bursae may be required for chronic or frequently recurrent bursitis. Our case presented with chronic aseptic bursitis in both knee pre-patellar and infra-patellar region which was confirmed by USG and MRI .Since it was chronic bursitis with large fluid collection, surgical resection

(Bursectomy) was advised to avoid recurrence and other complications.

Conclusion

To conclude many different types of bursae are seen around the knee joint. The specific anatomic location of the swelling often permits the correct diagnosis. USG and MRI helps in ruling out other

conditions and internal derangements. The majority of cases with bursitis can be treated conservatively, but some may require surgical treatment. Awareness of the different types of lesions and its imaging findings helps in diagnosis and for prompt management.

Bibliography:

1. Koh WL, Kwek JW, Quek ST, Peh WC. Clinics in diagnostic imaging (77). Pes anserine bursitis. Singapore Med J 2002; 43: 485-91.
2. Hirji Z, Hanjun JS, Choudur HN. Imaging of Bursae. J Clin Imaging Sci 2011;1:22.
3. McCarthy CL, McNally EG. The MRI appearance of cystic lesions around the knee. Skeletal Radiol 2004; 33: 187-209.
4. Priyank S Chatra. Bursae around the knee joints. Indian Journal of Radiology and Imaging, Year 2012, Volume 22, Issue 1 [p. 27-30]DOI: 10.4103/0971-3026.95400
5. McCarthy CL, McNally EG. The MRI appearance of cystic lesions around the knee. Skeletal Radiol 2004; 33: 187-209.
6. Steiner E, Steinbach LS, Schnarkowski P, et al. Ganglia and cysts around joints. Radiol Clin North Am 1996; 34: 400-410.
7. Janzen DL, Peterfy CZG, Forbes JR, et al. Cystic lesions around the knee joint: MR imaging findings. AJR Am J Roentgenol 1994;163: 155-161.
8. Rowand M, Chambliss ML, Mackler L. Clinical inquiries. How should you treat trochanteric bursitis. *J Fam Pract.* 2009; 58:494-500.