

Original article

Comparison of morphology of placenta in normal Vs pregnancy induced hypertension with ultrasonography and in gross specimen

¹Durgesh Singh , ²Pratap Chandra Shukla , ³Anshu Mishra , ⁴Parmatma Prasad Mishra

¹M. Sc. student, Department of Anatomy , Integral Institute of Medical Sciences and Research, Kursi Road, Lucknow

²Assistant Professor, Department of Radiodiagnosis , Integral Institute of Medical Sciences and Research, Kursi Road, Lucknow

³Assistant Professor, Department of Anatomy , Integral Institute of Medical Sciences and Research, Kursi Road, Lucknow

⁴Assistant Professor, Department of Anatomy , Integral Institute of Medical Sciences and Research, Kursi Road, Lucknow

Corresponding author: Anshu Mishra , Assistant Professor, Department of Anatomy , Integral Institute of Medical Sciences and Research, Kursi Road, Lucknow

Abstract:

Introduction: The placenta is the primary site of nutrient and gas exchange between mother and fetus. This describes the importance of study of morphology of placenta.

Materials and Methods: For the present study 50 fullterm pregnant females (25 normal and 25 pregnancy induced hypertension) were included. Diameter of placenta in them was measured with ultrasonography. After delivery weight and diameter of placenta was measured in same subjects.

Observation and Results: In this study we found that average diameter measured by ultrasonography in normal subject was 19.27 ± 2.31 cm and in PIH cases it was 19.15 ± 2.31 cm. When the placenta from case was measured after delivery mean diameter in normal subjects was 18.02 ± 2.40 cm and in PIH cases it was 18.09 ± 2.50 cm. The differences in diameter of placenta in normal Vs PIH cases measured with both the methods, was not significant. The mean weight measured in placenta of normal subjects was 452.80 ± 140.93 gm and was in PIH cases 330.00 ± 178.89 gm. The difference of mean weight in two groups was statistically significant.

Conclusion: Morphology of placenta is a good indicator of pregnancy associated hypertension.

Key words: morphometry, placental diameter, placental weight

Introduction:

Placenta is a highly vascular organ which maintains the maternofetal circulation via its connection by the umbilical cord. Amongst its functions are exchange of metabolic and gaseous products between maternal and foetal blood streams and production of hormones¹. At term, the placenta is discoid with a diameter of 15 to 25cm and is approximately 3cm thick and weighs about 500-600g¹. Alterations in the morphology of placenta are associated with fetal and

maternal abnormalities including intrauterine growth retardation (IUGR). Hypertension is one of the common conditions affecting the pregnancy that may be preexisting or appears for the first time during pregnancy. Hypertension is a sign of an underlying pathology that PIH is divided into three clinical types: pre-eclampsia, eclampsia, and gestational hypertension. It has been recorded that the maternal utero placental blood flow decreases in pre-eclampsia because of maternal vasospasm^{2, 3}. Maternal

vasospasm may lead to hypoxia resulting in IUGR and associated with the changes seen in the placenta. Ultrasound during pregnancy is an invaluable imaging method to assess the size and structural features of the placenta. After delivery if the placenta is examined minutely it provides much insight into the prenatal health of the baby and the mother⁴.

Aims and objectives is to establish morphometric measurements of placenta and to compare them in normal pregnancies from pregnancies affected from hypertension.

Material and methods

It was a case-control study conducted at Department of Anatomy and Department of Radiodiagnosis, Integral Institute of Medical Sciences & Research. Ethical approval was given by the Institutional ethical committee. The duration of study was october 2014 to july 2015 (10 month).

Inclusion Criteria

- a. Singleton pregnancy
- b. Maternal age between 22 -35 Year
- c. Pregnancy induced hypertension (PIH)

Exclusion criteria:

Pregnancy with any other complication

A total of 50 subjects (25 normal fullterm pregnancies and 25 fullterm cases of pregnancy induced hypertension) admitted in labour room of department of obs & gynae were included in the study after giving informed consent.

The subjects were then adviced to undergo ultrasonography. The examination was done while the subject lied supine on ultrasound table. The placenta was evaluated with curvilinear probe of 3.5 mega htz. It was firstly localized and then the diameter was measured by electronic scale (figure 1 & 2)

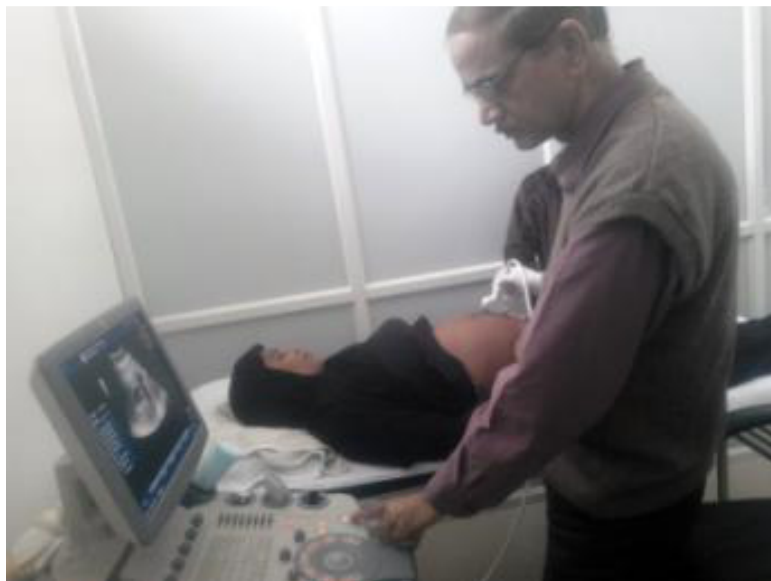


Figure 1: measurement of diameter of placenta with ultrasonography

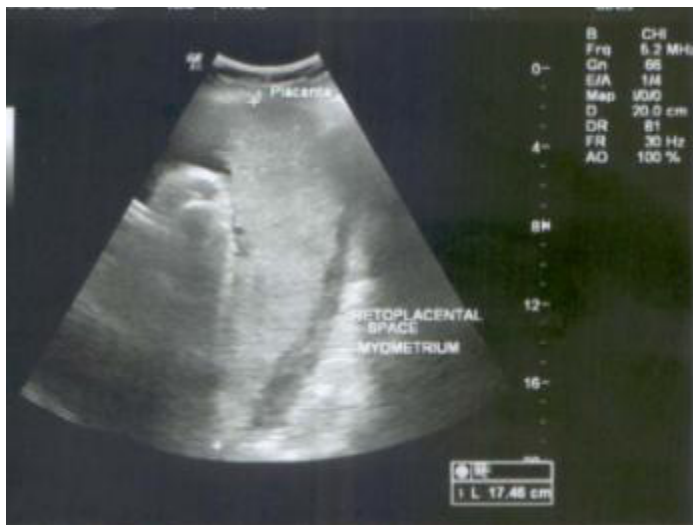

Figure 2: ultrasonographic film showing measurement of diameter of placenta

Placenta with a portion of umbilical cord, from the same subjects was collected in a clean tray after delivery. The membranes were cut off from their attachment to the placenta. Then it was gently expressed so as to remove its blood content and then washed thoroughly under tap water, mopped with dry

cotton pad. The specimen was transported to the department of anatomy in formalin (10%) filled plastic containers. All the specimens were tagged with numbered disc for the purpose of identity (figure 3).



Figure 3: collection of placentae

In the collected placenta the following parameters were observed:

1. weight of placenta
2. Maximum diameter of placenta

Weights of placentas were measured by electronic weighing machine after correcting the error of the machine (figure 4)

The maximum diameter was measured with help of thread and metallic scale in centimeter (figure 5).



Figure 4: Measurement of weight of placenta

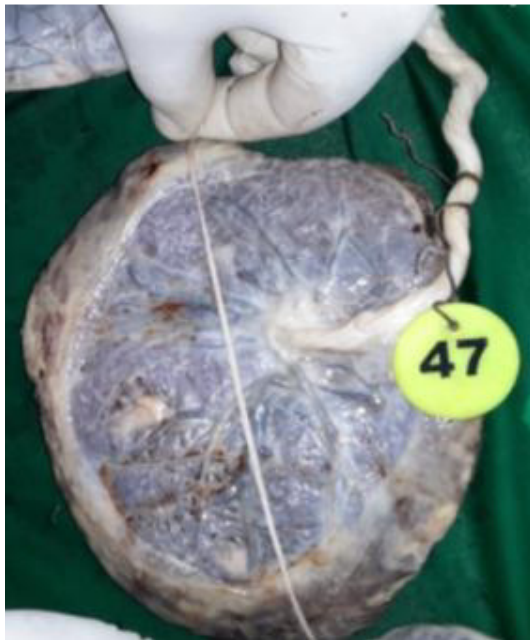

Figure 5: Measurement of diameter of placenta.

Observations and results

Weight of placenta: the weight of placenta in normal cases was ranged between 280 gm to 550 gm, whereas in cases of pregnancy induced hypertension it ranged between 250 gm to 450 gm. The

measurements were noted, categorized and then tabulated (table 1). The mean weight was calculated and compared in both groups. The difference in mean weight in two groups was statistically significant.

Table-1: Pattern of weight of placenta in cases and control

Weight of placenta (in gram)	Control (N=25)	Cases (N=25)
< 300gm	4	8
301-400gm	6	14
>400gm	14	3

Table-2: Comparison of mean weight of placenta in cases and control

	Control (N=25)	Cases (N=25)	p- value
Weight of placenta (in gram)	452.80±140.93	330.00±178.89	0.001

Table-3: Pattern of diameter of placenta in case and control

Diameter of placenta (in cm)	Control (N=25)	Cases (N=25)
15-16.9cm	4	3
16-17.9 cm	12	9
18-20.9 cm	8	11
21-22.9 cm	5	2

Table-4: Comparison of mean diameter of placenta in cases and control

Study variable	Control (N=25)	Cases (N=25)	p- value
Diameter of placenta (in cm)	18.02±2.40	18.09±2.50	0.92

Table-5: pattern of diameter of placenta measured by ultrasonography

Diameter of placenta (in cm)	Control (N=25)	Cases (N=25)
<18 cm	10	9
18-22 cm	11	12
>22	4	3

Table-6: Comparison of mean diameter of placenta in cases and control measured by ultrasonography

Study variable	Control (N=25)	Cases (N=25)	p- value
Diameter of placenta (in cm)	19.27±2.31	19.15±3.61	0.69

The mean diameter of placenta was found slightly higher in ultrasonography, though the difference was not statistically significant.

Discussion:

Placenta is a mirror that reflects the intrauterine status of the fetus and postnatal fetal outcome⁵. It is the most accurate record of the infants' prenatal experience. Any condition which is affecting the morphology of placenta will definitely affect the fetal outcome. The weight of placenta is an important and functionally significant parameter to villous area and fetal metabolism. Fox and neil (1978) reported that placenta tend to be smaller in preeclampsia than those in uncomplicated pregnancies⁶. Although the placenta adopts itself to hypoxia but the compensatory changes are insufficient and result in reduced placental weight.

Keche and Keche (2015) studied the morphometric differences of placenta in normal pregnancy and pregnancy-induced hypertension (PIH)⁷. A total of 100 placentas (50 from normal pregnancy and 50 from PIH group) were studied for different parameters including weight and diameter. They

found mean placental weight and diameter were lower in the PIH group. Similarly Majumdar, et al 2005, Udaina and Jain (2001), Raghavendra, et al 2013 and Agarwal et al (2015), and also found significant decrease in weight and diameter of placenta in PIH cases^{4, 5, 8, 9}. In contrast to above mention studies we do not found any significant difference in the diameter of placenta. This was similar to the study by Devishankar, et al. (2012), who reported in their study that the difference in placental diameter was not significant¹⁰.

In the present study, the placenta diameter was observed both by ultrasonography and in gross specimens. Though the mean diameter of placenta measured by USG was higher than mean diameter measured in gross specimen, the difference was not significant.

Conclusion:

We conclude that there should be strict screening for hypertension in antenatal cases as effect of pregnancy induced hypertension on morphology of placenta, indicates status of fetal stress.

References:

1. Sadler, T.W., 2004. Langman's medical embryology., 9 Edn. Baltimore, MD: Lippincott Williams and Wilkins, pp: 177-148.
2. Browne JCM, Veall N. The maternal blood flow in normotensive and hypertensive women. J Obstet Gynaecol Br Emp 1953; 60:141-7.
3. Landesman R, Douglas RG, Holze E. The bulbar conjunctival vascular bed in the toxemias of pregnancy. Am J Obstet Gynecol 1954;68(1):170-3
4. Majumdar S, Dasgupta H, Bhattacharya K, Bhattacharya A. A study of placenta in normal and hypertensive pregnancies. J Anat Soc India 2005; 54(2):1-9.
5. Udaina and Jain ML. Morphological study of placenta in pregnancy induced hypertension with its clinical relevance. Journal Anatomical Society of India, 2001; 50(1): 24 -27.
6. Fox H, Neil J, editors. Pathology of the placenta. 3rd edition. Philadelphia: Elsevier Saunders, 2007
7. Keche HA, Keche AS. Morphometric differentiation between placenta in PIH and normal pregnancy. International Journal of Medical Science and Public Health, 2015; 4 (2).
8. Raghavendra AY, Veena P, Ramesh ST, Vinay KK. Study of placental diameter and surface area in normal and hypertensive pregnancies. Anatomica Karnataka, 2013; 7(3): 18-22
9. Agarwal GC, Saini P, Pankaj JP, Pandey LN, Jain A. Morphological study of placenta in normal and hypertensive pregnancies. IAIM, 2015; 2(5): 121-128
10. Devishankar K, Bhanu PS, Kiran S, Ramakrishna BA, Shanthi V. Vasculo syncytial membrane in relation to syncytial knots complicates the placenta in preeclampsia: A histomorphometrical study. Anat Cell Biol., 2012; 45: 86-91