

Case report

Variation in the branching pattern of axillary artery: Thoracodorsal Pedicle

¹Dr Aradhana Sanga, ²Dr Sayongdeepa Roy, ³Dr Maitreyi Mondol, ⁴Dr Maitreyee Kar, ⁵Dr Pallab Kumar Saha, ⁶Dr Anupam Baske, ⁷Dr Saiket Kumar Dey, ⁸Prof(Dr) Sudeshna Majumdar

^{1,2,6,7}Junior Resident, Department of Anatomy, North Bengal Medical College, Sushrutanagar, Darjeeling – 734012,

³Associate Professor, Department of Anatomy, North Bengal Medical College, Sushrutanagar, Darjeeling – 734012,

⁴Associate Professor, Department of Anatomy & Dean of Students' Affairs North Bengal Medical College, Sushrutanagar, Darjeeling – 734012

⁵Assistant Professor, Department of Anatomy, North Bengal Medical College, Sushrutanagar, Darjeeling – 734012,

⁸Professor & Head, Department of Anatomy, North Bengal Medical College, Sushrutanagar, Darjeeling – 734012

Corresponding author: Dr. Aradhana Sanga

Abstract

Superior extremity is a common site for surgical and invasive procedures so knowledge of different variations is necessary. The arteries of upper extremities show a large number of variations. The subclavian artery is the main arterial trunk in the upper extremity and it is continued as the axillary artery and then as brachial artery in the arm.

In the present case, a common trunk was found originating from second part of axillary artery giving the following branches: (a) lateral thoracic artery, (b) unnamed muscular branch, (c) accessory subscapular artery, and (d) the main trunk continuing as Thoracodorsal Artery. The usual lateral thoracic artery from second part of axillary artery was found missing. The knowledge of this variation may be useful for surgeons, especially plastic surgeons who use thoracodorsal and serratus anterior flaps.

Key Words: Axillary artery, Thoracodorsal Pedicle, Accessory Scapular Artery

Introduction

The arterial system of upper extremity shows a large number of variations in human. It is so frequently observed that it appears that variation is a rule rather than exception¹. Normally, the axillary artery is a direct continuation of subclavian artery from outer border of first rib to the lower border of teres major, being divided by pectoralis minor into three parts. First part extends between outer border of first rib to medial border of pectoralis minor. It gives one branch, the superior thoracic branch. Second part extends behind the pectoralis minor and gives two

branches, the thoracoacromial artery (TAA) with its four branches and lateral thoracic artery (LTA). The third part extends from lateral border of pectoralis minor to the lower border of teres major giving three branches, Anterior Circumflex Humeral (ACH), Posterior Circumflex Humeral (PCH) and Subscapular (SA) arteries. The SA further divides into Circumflex Scapular Artery (CSA) which winds around lateral border of scapular and a thoracodorsal artery (TDA) which reaches anterior border of latissimus dorsi².

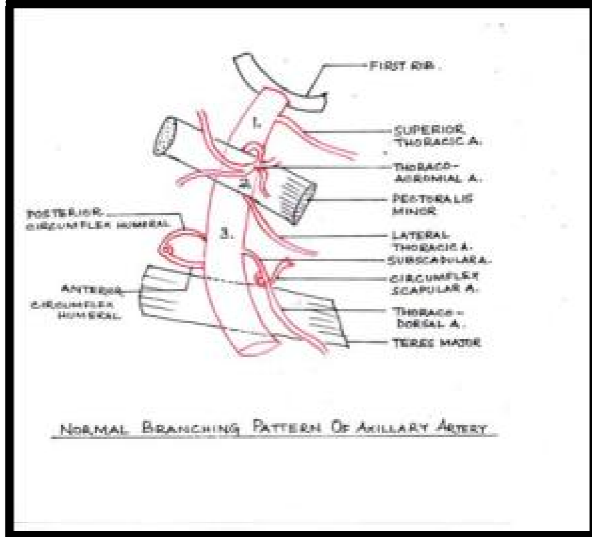


Figure 1: Normal Branching Pattern of Axillary Artery

Superior extremity is a common site for invasive procedures, so knowledge of different variations is necessary. In the previous researches, one such variation was noted where the Thoracodorsal Pedicle was seen to arise directly from second part of axillary artery and hence separated from the subscapular vascular pedicle arising from the third part of the axillary artery³. The prevalence of this variation was found to be 3% in previous studies⁴.

Case Report

During a routine dissection of an approximately 70 year old male cadaver for the undergraduate students of North Bengal Medical College, Darjeeling, West Bengal we came across a variation in branching pattern of second and third part of left axillary artery. The second part gave its usual thoracoacromial branch but the lateral thoracic artery (LTA) was

replaced by a trunk. This trunk gave the following branches: a) LTA supplying the upper 2-3 digitations of serratus anterior. b) A muscular branch (MB) supplying lower digitations of serratus anterior. c) An accessory subscapular artery (ASA) crossing above the thoracodorsal nerve to lie on the subscapularis muscle and supplied it.

The trunk itself continued to supply the latissimus dorsi as the thoracodorsal artery. When further dissection was done to observe the branches of third part of the axillary artery, it was found that the PCH and ACH arteries had their normal origin. The third artery arising was SA giving rise to two branches: the CSA to the dorsal surface of scapula, and another branch supplying teres major.

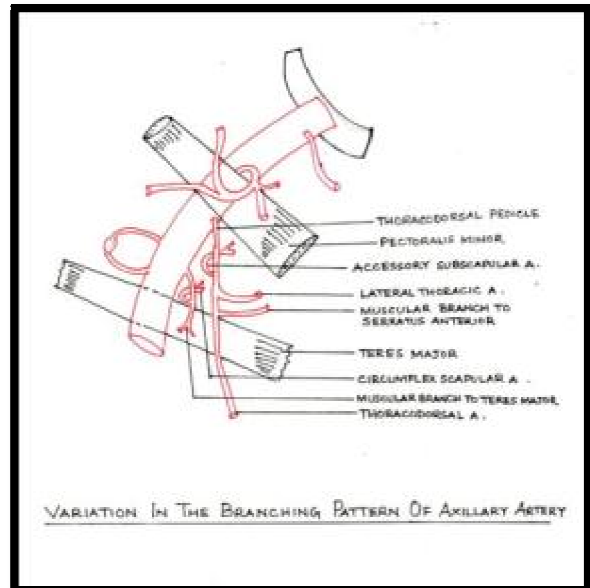


Figure 2: Variation in the Branching Pattern of Axillary Artery



Figure 3: Thoracodorsal Pedicle and its branches arising from 2nd part of Axillary Artery

[AA – Axillary Artery, TAA – Thoraco-acromial artery, LC – Lateral cord of brachial plexus, MPN – Medial Pectoral Nerve, TDP – Thoracodorsal Pedicle, LTA – Lateral Thoracic Artery, ASA – Accessory Subscapular Artery, MB – Muscular Branch to Serratus Anterior, TDA – Thoracodorsal Artery, CSA – Circumflex Scapular, MB-1 – Muscular Branch to Teres Major]

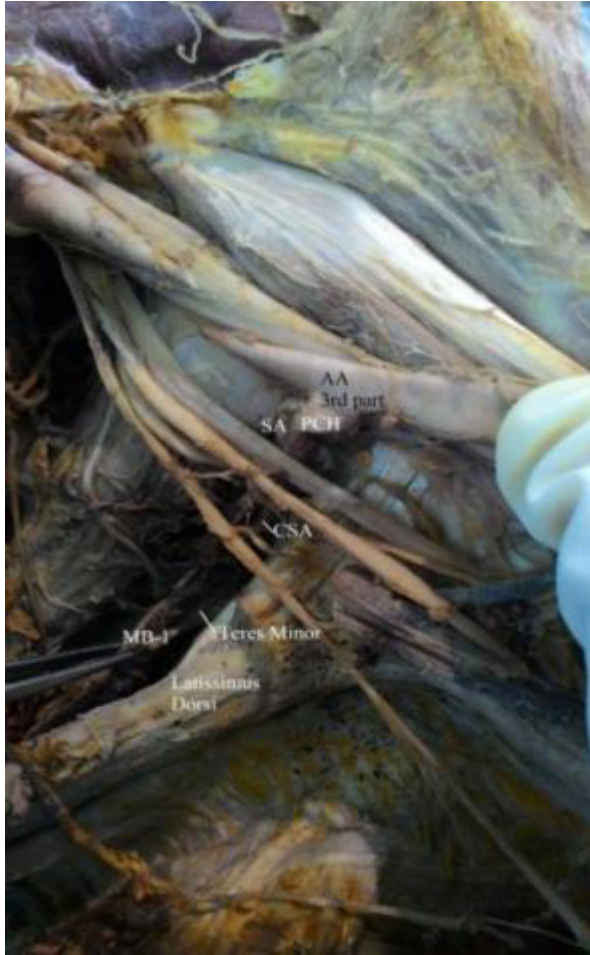


Figure 4: Branches from the 3rd part of Axillary Artery

[PCH – Posterior Circumflex Humeral, SA – Subscapular Artery]

Discussion

Embryological Consideration: The axillary artery develops from the proximal part of axial artery which is derived from lateral branch of 7th intersegmental artery⁵. The developmental variations may be due to:

- 1) Unusual primitive path of vascular plexus.
- 2) Persistence of normally obliterated vessels.
- 3) Disappearance of normally retained vessels.
- 4) Incomplete development, fusion and absorption of the parts usually

prominent⁵. Goldberger et al, in his study on serratus anterior flap in plastic surgery operations, noted that the artery to serratus anterior could originate directly from the SA². The thoracodorsal pedicle arose directly from axillary artery in that case.

According to Jain et al, a common trunk from second part of the axillary artery gave origin to LTA, TDA and CSA. The third part gave rise to ACH and PCH arteries⁶. Another contributor Srimathi T found a common trunk from the second part of axillary artery giving origin to TAA, LTA, SA and PCH. The third part gave origin to ACH only⁷.

Occasionally, the second part of axillary artery gives origin to a common trunk for LTA and SA. ACH and PCH came out of third part as observed by Shantakumar et al⁸. In a case report by Bhat et al, a common trunk from second part of axillary artery was seen giving origin to muscular branches supplying pectoralis major and deltoid. The LTA, SA and TAA were also seen coming out of the same trunk⁹.

Applied Importance:

The knowledge of this type of variation may be useful for plastic surgeons in case of reconstruction surgeries using serratus anterior flap and thoracodorsal flap. In general, the knowledge of branching pattern may be of concern for general surgeons during radical mastectomy, cardiovascular surgeons during coronary bypass surgeries, for radiologists to view the antegrade cerebral perfusion and to orthopaedic surgeons during repair of fracture of surgical neck of humerus and shoulder dislocation.

References

1. Sharma T, Singla R K, Sachdeva K. Bilateral Superficial Brachial artery. Kathmandu Univ. Med. J (KUMJ) 2009 Oct-Dec; 7 (28):p.426 – 28.
2. Standing S, Johnson D, Collins P, Healy J C, Evans D M, Lee J, Tickle C, Graham T. (Eds.) Gray's Anatomy. The anatomical Basis of Clinical Practice. In: Pectoral girdle and upper limb. Vascular supply and Lymphatic drainage. 40th edition. Churchill Livingstone; Elsevier; Spain 2008, reprinted in 2011: p. 815-17.
3. Doyle J A, Bolte M J. Surgical Anatomy of Hand and Upper Extremity, In; Vascular systems, Lipincott Williams and Wilkins, 2003: p.243
4. Goldberg J A, Lineaweaver W C, Bancke H J. An aberrant independent origin of Serratus Anterior pedicle. Ann. Plast. Surg. 1990 Dec; 25 (6): 487 – 90.
5. Arey L B, Developmental Anatomy. A Textbook and Laboratory Manual of Embryology, In: Development of arteries. 6th edition; Philadelphia. W B Saunders Co; 1957, p.375 – 7
6. Jain S R, Kulkarni P R, Baig M M. Variation in the Origin of Branches of Axillary Artery – a case report. Indian Journal of Research and Reports in Medical Sciences. June 2013, Vol 3 (2):43-44
7. Srimathi T. Abnormal branching pattern of axillary artery – a case report. International Journal of Basic Medical Sciences. September 2011, Vol 2 (4):73-76
8. Shantakumar S K, Rao K G M. Variant branching pattern of 3rd part of Axillary Artery. Case Report in Vascular Medicine, 2012:1-3
9. Bhat K M, Gowda S, Potu B K, Rao M S. A unique branching pattern of the axillary artery in a South Indian male Cadaver. BratislLekListy; 2008; 109 (12): 587-89.