

## Original article

# Comparison between operative versus conservative treatment of fracture clavicle

<sup>1</sup>Dr. Vipin Garg , <sup>2</sup>Dr. Anjul Agarwal

<sup>1</sup>MS Orthopaedics, Assistant Professor, Department of orthopaedics, S.S. Medical College and associated Hospital , Rewa, M.P., India.

<sup>2</sup>MS Ophthalmology, S.S. Medical College and associated Hospital , Rewa, M.P., India.

Corresponding author: Dr. Vipin Garg

---

### Abstract

**Background and objectives:** Fractures of the clavicle is one of the most common injuries of human skeleton. It has been traditionally treated non-operatively. The present study was undertaken to evaluate the selected group of patients who required surgical intervention

**Methods:** Twenty adult patients with clavicular fractures treated surgically between July 2011 to May 2013 were included for this study. Sixteen middle third clavicle fractures were fixed with plate and screws and four lateral third clavicle fractures were fixed with Kirschner wires with tension band. The functional outcome compared with 20 patients with fracture clavicle treated conservatively by figure of 8 bandage and cc sling

**Keywords;** clavicle, k wire ,plates,fracture

---

### Introduction

Fractures of the clavicle have been traditionally treated nonoperatively. In the past few years several publications have described about poor outcomes like malunion and nonunion (15%) after conservative treatment of severely displaced clavicular fractures.<sup>2,3</sup>The proponents of early fixation of fresh clavicular fractures to prevent complications like malunion and nonunion emphasize the value of accurate reduction and rigid fixation in affording quick pain relief and promoting early functional recovery<sup>5</sup>. The purpose of this study is to gain experience with the surgical management of fresh displaced, comminuted middle third clavicle fractures with plate and screws and Kirschner wires with tension band construct for displaced lateral third clavicle fractures.

**Methodology:** The present study was carried out from July 2011 to July 2013 at Orthopaedics

Department at my institute. During this period 20 patients of clavicular fractures were treated surgically and 20 patients treated conservatively.

**Inclusion criteria:** Patient of any age who require surgical intervention for displacement and comminution at middle third clavicle fracture and displaced lateral third clavicle fracture were included for this study after taking written consent from them.

### Exclusion criteria :

- Patients not willing for surgery
- Patients medically unfit for surgery.

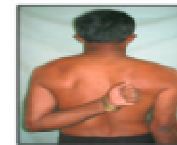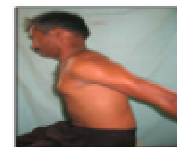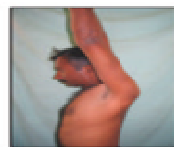
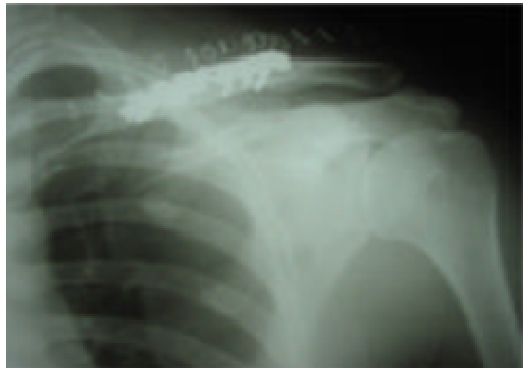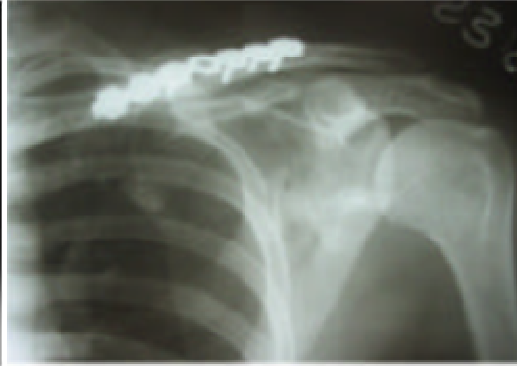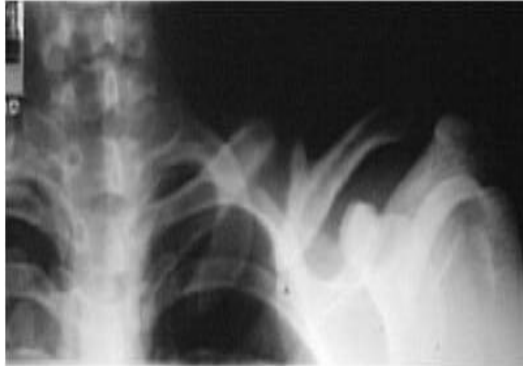General information like name, age, sex, occupation and address were noted. Then a detailed history was elicited regarding mode of injury like fall on the shoulder, Road traffic accident, direct injury to shoulder and fall on outstretched hand. Enquiry was made to note site of pain and swelling over the affected clavicle. Past medical illness and family history were also recorded. Middle third

clavicle fracture treated by plating and lateral third clavicle fracture treated by tension band wiring .The functional outcome were assessed by constant and murley score

**Results and observations**

The present study consists of 40 patients of fresh fracture of the clavicle 20 were treated surgically with plate and screw for middle third clavicle

fracture and Kirschner wire with tension band wire for lateral third clavicle fracture and 20 were treated conservatively with figure of 8 bandage and CC sling between July 2011 to July 2013. All the patients were available for follow-up and they were followed every 6 weeks. Results were analyzed both clinically and radiologically.



**Site of fracture:**

**Table- 1**

Site of Clavicle fracture	Number of Cases	Percentage
Middle third	32	80
Lateral third	8	20
Medial third	0	0

All the patients in both middle and lateral third clavicle fracture were closed type. There were no associated medical illness in any patient.

**Mode of injury:**

**Table –2**

Mode of Injury	No. of Middle third clavicle fracture	%	No. of Lateral third clavicle fracture	%
1. Fall on shoulder from two wheeler	10	25	6	15
2. Road traffic accident	8	20	2	5
3. Simple fall on shoulder	8	20	-	-
4. Run over by a bullock cart	2	5	-	-
5. Fall on outstretched hand (Indirect)	4	10	-	-
Total	32	80	8	20

**Age incidence :**

**Table –3**

Age in Years	No.of middle Third clavicle fracture	Percentage	Percentage No of lateral third clavicle fracture	Percentage
19-29	16	40	2	5
30-39	8	20	0	-
40-49	2	5	4	10
50-59	6	15	2	5
Total	32	80	8	20

**Sex incidence:**

**Table – 4**

Sex	No. of Middle third clavicle fracture	%	No. of lateral third clavicle fracture	%
Male	28	70	8	20
Female	4	10	-	0
Total	32	80	8	20

**Side affected:**

**Table - 5**

Side	No. of Middle third clavicle fracture	%	No. of lateral third clavicle fracture	%
Right	12	30	4	10
Left	20	50	4	10
Total	32	80	8	20

**Associated injuries :**

**Table – 6**

Type	No. of Middle third clavicle fracture	%	No. of Lateral third clavicle fracture	%
Scapular body fracture	2	5	2	5
Glenoid fossa and acromion process fracture	0	0	2	5
Bimalleolar fracture	2	5	0	0

All the Patients were immobilized in an arm pouch.

**Classification :**

Plain radiograph of clavicle with shoulder is taken in anteroposterior view to assess the site of fracture and the type of fracture (like Displacement, Angulation, Comminution). In this study Robinson classification was followed.

**Table -7**

Type	No. of cases
<b>Type -1 Medial third</b>	<b>0</b>
Type –2 Middle third	B1
	B2
Type –3 Lateral third	B1
	B2

Type-2 B1-displaced with simple or single butterfly fragment

Type-2 B2-displaced with comminuted or segmental

Type-3 B1-displaced with extra articular

Type-3 B2- displaced with intra articular

**Time interval for surgery :**

20 patients were operated as early as possible once the general condition of the patients were stable and 20 patients treated conservatively with figure of 8 bandage and CC sling.

**Table - 8**

Time of surgery	No. of Middle third clavicle fracture	%	No. of Lateral third clavicle fracture	%
< 7 days	14	70	4	20
7-14 days	2	10	-	-

**Types of implant : For middle third clavicle fracture :**

The middle third fracture are fixed with plate and cortical screws.

The following types of plates are used.

**Table –9.1**

Type of plate	No. of cases	%
Reconstruction plate	11	68.75
Semi tubular plate	3	18.75
Dynamic compression plate	2 + 1*	12.50

One reconstruction plate breakage occurred at 8 weeks postoperatively which was replated with dynamic compression plate.

**Fracture type and type of plate used :**

**Table –9.2**

Type of fracture (Robinson type)	Reconstruction plate	Semi tubular plate	Dynamic Compression Plate
Type II B1	9 (64.29%)	3 (21.43%)	2 (14.29%)
Type II B2	2	0	0

**Types of plate and length**

The plates were intraoperatively bent to the contour and curvature of the clavicle. The length of the plate to be used was determined according to the extent of comminution at the fracture. The aim was to place at least three screws in the medial and lateral main fragments through both cortices of the bone.

**Table –9.3**

Type of plate	6 hole	7 hole	8 hole
Reconstruction plate	3 (18.75%)	5 (31.25%)	3 (18.75%)
Semitubular plate	0	3 (18.75%)	0
Dynamic compression plate	2 (12.50%)	0	1*
Total	5(31.25%)	8(50%)	3(18.75%)+1*

\* For one broken reconstruction plate 8 hole dynamic compression plate was used during replating.

**Procedure : For lateral third clavicle fracture :**

4 patients of lateral third clavicle fracture were fixed with Kirschner wire and tension band wire through the distal end of clavicle. Suture removal was done on 10th post-operative day on all patients. Rehabilitation of the affected side shoulder were done at the end of 2 weeks. All patients were followed up every 6 weeks.

**Duration of union :**

The fracture was considered to be united when clinically there was no tenderness, radiologically the fracture line was not visible and full unprotected function of the limb was possible.

**Table-10**

Time of union	Patient treated surgically	%	Patient treated conservatively	%
8-12 week	18	90	0	0
>12 weeks	2	10	14	70
> 18 weeks			4	20
Non union			2	10

We advise the patient for removal of the plate at the end of 1 year. No patient has turned up for implant removal. So Implant removal was not done in any patient till the end of this study.

**Complications :**

Major complication : A complication requiring inpatient treatment and resulting in an additional morbidity of 2 months or more was regarded as a major complication.

**For middle third clavicle fracture treated surgically:**

**Table-11.1**

	<b>Types</b>	<b>No. of cases</b>	<b>%</b>
Minor	Hypertrophic skin scar	4	20
	Plate prominence	3	15
	Delayed union	2	10
	Plate loosening	1	5
Major	Pate breakage	1	5

**For lateral third clavicle fracture treated surgically:**

**Table- 11.2**

<b>Type of complications</b>		<b>No. of cases</b>	<b>%</b>
Minor	Superficial infection	1	5
Major	Restriction of shoulder movements	1	5

In 1 patient (5%) superficial infection occurred which was treated with oral antibiotics for 5 days and in another 1 patient (5%) restriction of shoulder movements occurred due to associated glenoid fossa fracture. The patient was not able to follow the shoulder exercises because of pain.

**Functional outcome :**

The functional outcome is assessed by Constant and Murley score.

**Table-12**

<b>Functional outcome</b>	<b>Patient treated surgically</b>	<b>%</b>	<b>Patient treated conservatively</b>	<b>%</b>
Excellent	15	75	0	0
Good	3	15	4	20
Fair	2	10	10	50
Poor	0	0	6	30
Total	20	100	20	100

**Summary**

Twenty patients with clavicular fracture were treated surgically, among them 16 patients of mid third clavicular fracture were fixed with plate and screws and 4 patients of distal third clavicle fracture were fixed with tension band wire between July 2011 to July 2013 .Patients all the age group were included in this study and the patients age ranged from 19 to 57 years. Middle third clavicle fracture is common between 19 to 29 years and lateral third clavicle fracture between 50 to 59 years in this study.Fall from the two wheeler was the cause for this fracture in most of the patients. Males are more commonly affected. 20% of the patient had associated injuries like scapular body

fracture, bimalleolar fracture and glenoid fossa fracture that were treated conservatively.In 18 patients (45%) surgery was done within the 1st week. The indication for surgery in middle third clavicle fracture was Robinson type-2B1 in 14 patients (displacement with simple or single butterfly fragment) and type-2 B2 in 2 patients (displacement with comminution). For lateral third clavicle fracture Robinson Type-3 B1 (Displaced and Extraarticular) in all the 4 patients.

20 patients were operated under general anesthesia with plate and screws for middle third clavicular fractures. Reconstruction plates were used in 11 patients semi tubular plates in 3 patients and dynamic compression plates in 2 patients.

Kirschner wires with tension band wiring was done for lateral third clavicular fractures in 4 patients and 20 patients treated conservatively figure of 8 bandage and CC sling. All our patients who were operated immobilized in an arm pouch for 4 weeks. Average duration of stay in the hospital was 10.7 days. All the patients were mobilized at the end of 2nd week with the sling. The duration of union in operated group of patients range from 8-12 weeks (average 11.13 weeks) in 14 patients. 2 patients went for delayed union, one fracture united at 14 weeks. Another one patient of middle third clavicle fracture fixed with reconstruction plate broke at 8 weeks post operatively. It united after replating at 20 weeks. Duration of union in patient treated conservatively was 14-18 weeks (average 16 weeks) in 14 patients 4 patients had delayed union and 2 patients had non union.

The functional outcome assessment according to Constant and Murley score for middle third clavicle fracture treated by plate and screws showed excellent functional outcome in 12 patients (60%) and good functional outcome in 3 patients (5%) and 1 fair functional outcome in 1 patients who was reported for plate breakage. Lateral third clavicle fracture treated by Kirschner wire with tension band wiring showed excellent functional outcome in 3 patients and fair functional outcome in 1 patient. The functional outcome assessment according to Constant and Murley score for patients treated conservatively showed good outcome in 4 patients fair functional outcome in 10 patients and poor in 6 patients.

#### **Conclusion**

- Clavicle fractures are usually treated conservatively but there are specific indications for which operative treatment is needed like comminuted, displaced

middle third clavicle fractures and displaced lateral third clavicle fracture.

- Among the internal fixation methods intramedullary fixation do not control rotation so they require longer period of immobilization till union.
- In this study primary open reduction and internal fixation with plate and screws of fresh middle third clavicle fractures provides a more rigid fixation and does not require immobilization for longer periods.
- □ In this study reconstruction plates were used as it can be contoured to the shape of the clavicle. It is necessary to put the plate superiorly and atleast three screws to be applied medially and three screws laterally. In this
- Dynamic compression plate is strong but it gives excessive prominence through the skin and it is difficult to contour.
- Now a days precontoured clavicle plates are available which are strong easy to apply but costly
- All the fractures united and there was no non union.
- No implant removal was done till the end of this study.
- For displaced, comminuted middle third clavicle fracture plate and screws fixation and early mobilization gave excellent results in 12 patients.
- □ For displaced lateral third clavicle fractures in a small study of 4 patients Kirschner wire with tension band wiring and early mobilization gave excellent results in patients without associated injury.

**References :**

1. Craig EV, Basamania CJ, Rockwood CA. Fractures of the clavicle. Chapter-11, In : Rockwood CA, Matsen FA, Wirth MA, Lippitt SB, editors, The shoulder. 3rd edition Philadelphia : Saunders, 2004 ; 455-519.
2. Jupiter JB, Leffert RD. Non-Union of the clavicle. Associated complications and surgical management . J Bone Joint Surgery (Am) , 1987;69: 753-760.
3. Hill JM, Mc Guire MH, Crosby LA. Closed treatment of displaced middle third fractures of the clavicle gives poor results. J Bone Joint Surgery (Br), 1997; 79 :537-540.
4. Geel CW. Scapula and clavicle. Chapter-4 In Colton CL, Dell'oca AF, Holz U, Kellam JF, Ochsner PE , editors. AO Principles of fracture management, New York : Thieme, 2000; 262-264.
5. Poigenfurst J, Rappold G, Fischer W. Plating of fresh Clavicular fractures. Injury, 1992;23(4):237-241.
6. Nicholl EA. Annotation. Miners and mannequins. J Bone Joint Surgery (Br), 1954; 36:171-172.
7. Neer CS. Non union of the clavicle. JAMA, 1960; 172: 1006-1011.
8. Rowe CR. An atlas of anatomy and treatment of midclavicular fractures. Clin. Orthop, 1968 ; 58:29-42. 120
9. Ali Khan MA, Lucas HK. Plating of fractures of the middle third of the Clavicle. Injury 1977; 9 : 263-267.
10. Manske DJ, Szabo RM. The operative treatment of mid shaft clavicular non union. J Bone Joint Surgery (Am), 1985;67:1367- 1371.
11. Poingenfurst J, Reiler T, Fischer W. Plating of fresh clavicular fractures. Experience with 60 operations. Unfallchirurgie 1988; 14: 26-37.
12. Connolly JF, Dehne R. Non Union of the clavicle and thoracic outlet Syndrome. J Trauma. 1989; 29 : 1127-1132.
13. Schwarz N, Hocker K . Osteosynthesis of irreducible fractures of the clavicle with 2.7mm ASIF plate. J Trauma, 1992; 33: 179-183.
14. Mullagi AB, Jupiter JB. Low-contact compression plating of the clavicle. Injury, 1994 ; 25:41-45.
15. Davids PH, Luitse JS, Strating RP, Vander Hart PC. Operative treatment for delayed union and non union of mid shaft clavicular fractures : AO reconstruction plate fixation and early mobilization. J Trauma, 1996; 40: 985-986.
16. Bostman O, Manninen M, Pihlajamaki H. Complications of plate fixation in fresh displaced mid clavicular fractures. J Trauma, 1997; 43:778-783. 121
17. Nordqvist A, Petersson CJ, Redlund-Johnell I. Mid clavicular fractures in adults : end result study after conservative treatment . J Orthop Trauma, 1998 ; 12 : 572-576.
18. Shen WJ, Liu TJ, Shen YS. Plate fixation of fresh displaced mid shaft clavicle fractures. Injury, 2000; 31 (3) : 175-179.
19. Iannotti MR, Crosby LA, Stafford P, Grayson G, Goulet R. Effects of plate location and selection on the stability of mid shaft clavicle osteotomies : a biomechanical study. J Shoulder Elbow surgery, 2002;11(5): 457-462.



20. Robinson CM, Court Brown CM, McQueen MM, Walkefield AE. Estimating the risk of non union following non operative treatment of a clavicular fracture. *J Bone Joint Surgery (Am)*, 2004; 86 : 1359-1365.
21. Neer CS II Fracture of the distal end of the clavicle. *Clin Orthop*, 1968; 58: 43-50.
22. Kona J, Bosse MJ, Staeheli JW, Rosseau RL. Type II distal clavicle fractures :a retrospective review of surgical treatment. *J Orthop Trauma*, 1990 ; 4 : 115-120.
23. Ballmer FT, Gerber C. Coracoclavicular screw fixation for unstable fractures of the distal clavicle. A report of five cases. *J Bone Joint surgery (Br)*, 1991; 73 : 291-294. 122
24. Edwards DJ, Kavanagh TG, Flannery MC. Fractures of the distal clavicle a case for fixation. *Injury*, 1992; 23 : 44-46.
25. Webber MC, Haines J F. The treatment of lateral clavicle fractures. *Injury* 2000; 31 (3) : 175-179.
26. Kruger – Franke M, Kohne G, Rosemeyer B, Outcome of Surgically treated lateral clavicle fractures. *Unfallchirurgie*, 2000; 103 (7) : 538-544.
27. Kao FC, Chao E K, chen CH, Yu SW, Chen CY, Yen CY. Treatment of distal clavicle fracture using Kirschner wire and tension band wires. *J.Trauma*, 2001;51 : 522-525.
28. Lazarus MD. Fractures of the Clavicle. Chapter-26, In : Bucholz RW and Heckman JD, editors, Rockwood and Green's fractures in adults, 5th edition , Philadelphia : Lippincott Williams and Wilkins, 2001; 1041-1078.
29. Wilk KE. The shoulder. Chapter-15, In Malone TR, McPoil TG, Nitz AJ, editors, Orthopaedics and sports physical therapy, 3rd edition, St.Louis : Mosby 1997; 401-409.
30. Ruedi T and Duwelins PJ. Fractures and dislocations of the shoulder girdle and humerus. Chapter-15 , In : Chapman MW, editor, Chapman's orthopaedic Surgery, Philadelphia, Lippincott Williams and Wilkins , 3rd edition 2001; 444-450. 123
31. Creashaw AH. Fractures of shoulder, arm and forearm. Chapter – 54, In : Canale ST, editor. Campbell's operative orthopaedics, 10<sup>th</sup> edition , St. Louis, Mosby , 2003; 2985-3071.
32. Robinson's CM. Fractures of the clavicle in the adult. Epidemiologyand classification. *J Bone Joint Surgery (Br)*, 1998; 80: 476-484.
33. Jupiter JB and Ring D. Fractures of the clavicle. Chapter- 26, In : Iannotti JP and Williams GR. editors. Disorders of the Shoulder diagnosis and Management, Philadelphia: Lippincott Williams and Wilkins 1999, 709-786.
34. Gaudinez RF, Hoppenfeld S. Clavicle fractures. Chapter-10 In : Hoppenfeld S, Murthy VL, editors. Treatment and Rehabilitation of fractures, Philadelphia: Lippincott Williams and Wilkins, 2000 ; 73-84.
35. Constant CR, Murley AHG. A clinical method of functional assessment of the shoulder. *Clinical Orthopaedics and Related Research*. 1987; 214: 160-164