

**Case Report:**

**Post operative pulmonary edema and complications**

**<sup>1</sup>Sabale BB , <sup>2</sup>Ravishankar K., <sup>3</sup>Sabale DB , <sup>4</sup>Barhate Amruta**

<sup>1</sup> Consultant, Medicine Department, Shri Sainath Hospital , shirdi , Maharashtra , India

<sup>2</sup>MD General Medicine , Senior Resident,Kurnool Medical College, Kurnool.

<sup>3</sup> Shri Sainath Hospital , Shirdi , Maharashtra , India

<sup>4</sup> PSM Department, Bharati Vidhyapeeth , Pune , Maharashtra , India

\*Corresponding author: Mail: drbbsabale11@gmail.com

---

**Abstract:**

Pulmonary edema is a life-threatening complication immediately after extubation or in early post-operative period. Pulmonary complications are not as well studied as cardiac complications in the post-operative setting and they can be life-threatening if not detected and treated early and promptly. We believe that this problem is grossly underestimated in its incidence as only few cases have been reported in literature. Herewith we described a case of 19 year old male who had undergone elective surgery under general anaesthesia. He developed POPE within three to five minutes after administration of “neostigmine-glycopyrrolate” used to reverse residual neuro-muscular blocked. The patient was treated successfully with mechanical ventilatory support with PEEP and adjuvant therapy viz.frusemide,dopamine. This is to emphasise that this potentially fatal complication is not uncommon and it is completely reversible though it can be fatal.

Keywords: Pulmonary oedema

---

**Introduction:**

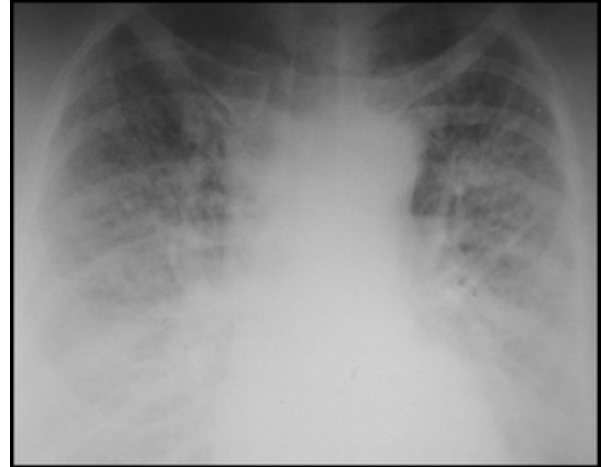
Post operative pulmonary edema is a well known post-operative complication with little known etiology and mortality(1-4) .Extensive pre-operative and intra-operative studies to collect evidence so as to establish to predict the possibility for development of postoperative pulmonary edema were done but without any predictive value. Several etiologic factors suggest that most of these patients have pre-existing heart diseases. Over administration of intravenous fluids during perioperative period which leads to cardiac dysfunction which can prove fatal (5) leads to POPE. Other pathogenic mechanisms besides fluid overload which lead to this serious clinical presentation are (6) are neurogenic

pulmonary edema , ARDS, head injury, polytrauma, hyponatraemia, adrenal tumours , septicaemia and pnumanitis. It was first reported in 1972 in dogs by R L Moore (7) in 1927 Moore demonstrated in studies of dogs that acute airway obstruction produced pulmonary edema (6-7) Pope was first described in humans in 1973 (9) . In 1977 two children were reported (10) to have pulmonary edema during episodes of croup and epiglottitis. A report was published in 1977 (11) of three adult patients who developed pulmonary edema after acute upper airway obstruction. Here we present a case of Negative pressure pulmonary edema that we came across in my institute.

**Case report:**

In this case , a 19 year old boy underwent an elective uncomplicated Cholecystectomy surgery for Cholelithiasis done under general anaesthesia. As surgery was finished and patient came out of anaesthesia ,he was given”neostigmin2.5mg and glycopyrrolate0.4 mg to reverse the residual neuromuscular blocked” and patient was extubated. Everything was fine till this time. Immediately within three to five minutes of extubation, he became restless with signs of respiratory distress, stridor was absent and he had no signs of airway obstruction, pulse oxymetry which was not obtainable in first minute due to patient movement started showing falling oxygen saturation rapidly and shockingly.

Reintubation was accomplished though with difficulty because of copious quantities of blood tinged huge secretions in the oral cavity. During intubation there was no evidence of laryngospasm and there were no gastric contents. Patient was taken in Intensive Care Unit and Mechanical Ventilation with 100percent oxygen with PEEP of 5mmH<sub>2</sub>O and dopamine was started which increased oxygen saturation to 70 percent. Intravenous frusemide and injection norphine was given to relieve distress. Oxygen saturation was increased to 90 percent . After three hours tachycardia was decreased and pulse ox saturation increased to 95 percent. Patient recovered completely within 7 days and was discharge.



**Clinical features**

The clinical picture is similar irrespective of the cause of pulmonary edema. History of recent extubation after anesthesia usually precedes the development of POPE. There are two recognized types fo POPE (12). Type one follows a sudden , severe upper airway obstruction such as seen in strangulation and hanging (11) epiglottitis , croup (10),post extubation laryngospasm (13) and choking . Type 2 POPE develops after surgical relief of chronic upper airway obstruction (14). This may occur after removal of upper airway tumours (14) and tonsillectomy (12)

Both type I and type II POPE present with acute respiratory distress. Clinical features are tachypnoea, tachycardia, pinkfrothy pulmonary secretions and progressive oxygen desaturation , rales and rhonchi on chest auscultation. The onset of type I POPE varies from few minutes to on e hour following extubation or relief of obstruction but the onset has been delayed of upto six hours in some case reports (6,11) and up to thirty hours in some cases .(15).Type II POPE develops soon after relief of chronic airway obstruction. Our reported illustrative case falls in POPE I category.

## INCIDENCE

Incidence of postoperative pulmonary edema is difficult to estimate because only single cases or few series of cases have been reported. In one study (16) of 53 paediatric patients, the incidence of POPE was 9.4 percent. There was another study (17) of 176 children which reported 9.6% of POPE I incidence while POPE II was present in 44%. Sofer S, reported incidence of 29% on radiographic observations of POPE. (18) All these show that POPE is not rare and the consulting physician should always keep in mind this syndrome and promptly diagnose and treat it for saving patients' lives

## ETIOLOGY

The most common cause of POPE I is post-extubation laryngospasm though it is multifactorial (6). Forceful attempts to inhale against an obstruction creates highly negative intra-thoracic pressure which causes increased venous return, decreased cardiac output and fluid transudations into the alveolar space. This theory is supported by apparent increase in susceptibility to POPE I in young children and athletic men (19) who are having good chest musculature and create extremely high inspiratory pressures. Other factors contributing include narcotic use, short neck, obesity, obstructive apnea, nasal, oral or pharyngeal surgery of pathology, vocal cord paralysis, endotracheal tube obstruction, premature extubation (20) administration of muscle relaxant at induction.

The etiology of POPE II is less clear. The sudden removal of PEEP leads to interstitial fluid transudations and pulmonary edema (6,12)

## PROGNOSIS AND MANAGEMENT

The management of post operative pulmonary edema is usually aimed at treatment of the underlying cause. Majority of patients give good results with conservative and symptomatic treatment but few do require reintubation and initiation of mechanical ventilation with allocation of PEEP. Cardiogenic pulmonary edema responds to appropriate cardiac treatment, fluid overload related POPE responds to fluid restriction and diuretic therapy. Diuretics may be required to remove excess intrapulmonary fluid but some researchers consider its use as unnecessary (22). Anaphylactic reaction related POPE requires steroids and beta agonists. The beta agonists cause active cation transport which causes rapid regression of pulmonary oedema.

Non-invasive ventilator support in pulmonary oedema is extremely beneficial as it prevents muscle fatigue, reduces ventricular afterload, better recruitment of alveoli and causes minimal disturbances in haemodynamic parameters (21) and there is decreased morbidity and mortality (21). These patients need positive end expiratory pressure (PEEP) to maintain oxygen saturation (22). Most cases of POPE respond promptly to treatment. Resolution of pulmonary oedema usually occurs within three to twelve hours of beginning of appropriate treatment. These patients have good prognosis if promptly diagnosed and appropriately treated. But a significant complication rate does exist leading even to mortality and it is generally attributed to a delay in diagnosis (23)

## Conclusion

In conclusion, POPE remains an important and fairly common complication which is easily

preventable by careful vigilance of the clinicians involved in post-operative care. It is very important especially in some centres of developing countries like Asia and Africa where advanced post-operative care may not be available, and then such

complications require immediate transfer of these patients to a centre with Intensive Care facilities so as to decrease the morbidity and mortality associated with such complications.

#### References:

1. Finn JC, Rosenthal MH. Pulmonary edema in trauma and critically ill patients. *Semin Anesth.* 1989;8:265–74.
2. Khuri SF, Daley J, Henderson W, Barbour G, Lowry P, Irvin G, et al. The National Veterans Administration Surgical Risk Study: Risk adjustment for the comparative assessment of the quality of surgical care. *J Am Coll Surg.* 1995;180:519–31.
3. Roth E, Lax LC, Maloney JV., Jr Ringer's lactate solution and extracellular fluid volume in the surgical patient: a critical analysis. *Ann Surg.* 1969;169:149.
4. van Hoozen BE, van Hoozen CM, Alberton TE. Pulmonary considerations and complications in the neurosurgical patient: Pulmonary edema. In: Youmans JR, editor. *Neurological surgery.* Philadelphia, PA: WB Saunders; 1996. pp. 624–6.
5. Mangano DT, Browner WS, Hollenberg M, London MJ, Tubau JF, Tateo IM, et al. Association of perioperative myocardial ischemia with cardiac morbidity and mortality in men undergoing noncardiac surgery. The Study of Perioperative Ischemia Research Group. *N Engl J Med.* 1990;323:1781–8.
6. Lang SA, Duncan PG, Shephard DA, Ha HC. Pulmonary oedema associated with airway obstruction. *Can J Anaesth.* 1990;37:210–8.
7. Moore RL. The response to respiratory resistance: a comparison of the effects produced by partial obstruction in the inspiratory and expiratory phases of respiration. *J Exp Med.* 1927;45:1065–80.
8. Suga K, Tsukamoto K, Nishigauchi K, Kume N, Matsunaga N, Hayano T, et al. Iodine-123-MIBG imaging in pheochromocytoma with cardiomyopathy and pulmonary edema. *J Nucl Med.* 1996;37:1361–4.
9. Capitanio MA, Kirkpatrick JA. Obstructions of the upper airway in children as reflected on the chest radiograph. *Radiology.* 1973;107:159–61.
10. Travis KW, Todres ID, Shannon DC. Pulmonary edema associated with croup and epiglottitis. *Pediatrics.* 1977;59:695–8.
11. Oswald CE, Gates GA, Holmstrom FM. Pulmonary edema as a complication of acute airway obstruction. *Rev Surg.* 1977;34:364–7.
12. Guffin TN, Harel G, Sanders A, Lucente FE, Nash M. Acute postobstructive pulmonary edema. *Otolaryngol Head Neck Surg.* 1995;112:235–7.
13. Willms D, Shure D. Pulmonary edema due to upper airway obstruction in adults. *Chest.* 1988;94:1090–2.

14. Miro AM, Shivaram U, Finch PJ. Noncardiogenic pulmonary edema following laser therapy of a tracheal neoplasm. *Chest*. 1989;96:1430–1.
15. Glasser SA, Siler JN. Delayed onset of laryngospasm-induced pulmonary edema in an adult outpatient. *Anesthesiology*. 1985;62:370–1.
16. McGowan FX, Kenna MA, Fleming JA, O'Connor T. Adenotonsillectomy for upper airway obstruction carries increased risk in children with a history of prematurity. *Pediatr Pulmonol*. 1992;13:222–6.
17. Galvis AG. Pulmonary edema complicating relief of upper airway obstruction. *Am J Emerg Med*. 1987;5:294–7.
18. Sofer S, Bar-Ziv J, Scharf SM. Pulmonary edema following relief of upper airway obstruction. *Chest*. 1984;86:401–3.
19. Scarbrough FE, Wittenberg JM, Smith BR, Adcock DK. Pulmonary edema following postoperative laryngospasm: case reports and review of the literature. *Anesth Prog*. 1997;44:110–6.
20. Soldano SL, Place LB, Edwards FH, Cohen AJ. Post-extubation non-cardiogenic pulmonary edema. *Mil Med*. 1993;158:278–80.
21. Jaber S, Chanques G, Jung B. Postoperative noninvasive ventilation. *Anesthesiology*. 2010;112:453–61.
22. Koh MS, Hsu AA, Eng P. Negative pressure pulmonary oedema in the medical intensive care unit. *Intensive Care Med*. 2003;29:1601–4.
23. Perez RO, Bresciani C, Jacob CE, Perez CG, Coser RB, Honda LF, et al. Negative pressure post-extubation pulmonary edema complicating appendectomy in a young patient. *Curr Surg*. 2004;61:463–5.