

Case Report:

Bilateral presence of psoas minor muscle and its morphometric analysis: a case report

Ms.Bali Sharma, Dr. Roma Patel, Dr.U.K.Gupta, Dr.S.K.Agarwal

Department of Anatomy , NIMS Medical College, Jaipur , Rajasthan

Corresponding author: Dr. Roma Patel

Date of submission: 11 July 2014 ; Date of Publication: 09 December 2014

Abstract

The psoas minor, present in only two out of every three individuals, is a slender muscle lying on the surface of psoas major. Psoas minor at its origin lies just in front of the psoas major muscle has small belly and long tendon like plantaris and palmaris longus muscle. The Psoas Minor Muscle is considered inconstant and it's often absent. This muscle consists of a short proximal fixation tendon originated from the sides of the twelfth thoracic vertebra, first lumbar vertebra and corresponding intervertebral disc, continuous with a short spindle-shaped morphology muscular venter, ending with a long distal fixation tendon inserted in the pectineal line of the pubis and iliopectineal eminence. Psoas minor receives its nerve supply from the ventral rami of L1 spinal nerves, which after piercing through the psoas major muscle enter into the muscular belly. Psoas minor also is subject to racial and ethnic variation. During a routine anatomical dissection for medical students, we found bilateral presence of psoas minor muscle.

Key words: Anatomy of Psoas Minor, psoas major, Morphology, Muscle.

Introduction:

The Psoas minor muscle is a constituent of the posterior abdominal wall and lies ventral to the psoas major muscle. The psoas minor muscle have been found to flex the lumbar spine and tilts it sideways when contracting unilaterally^[1], apart from providing stabilization to the hip joint^[2]. It is classified as an inconsistent muscle^[3] and is often absent. It is considered the muscle with highest percentage of unilateral or bilateral agenesis, considered ranging from 40% to 66% in different populations. Someone that has the muscle and strains it, however, can expect a 50 percent reduction in range of hip motion^[4]. To heal this type of injury, patients must first have corrective adjustments to properly align the spine and pelvis before performing a myofascial

stretch. The aim of the present case report is to reveal the anatomy of the psoas minor muscle, ascertain their origin and insertion points, analyze the possible dependent relationship between the fibers of the psoas minor and major muscles, neurovascular relations.

Case report:

During the course of routine cadaveric dissection for undergraduate students of a 52 year old male cadaver, at NIMS Medical College Jaipur, Rajasthan , the posterior abdominal wall revealed the bilateral existence of well formed psoas minor muscle taking origin from the lateral surfaces of the body of T12 & L1 vertebra and from intervening tendinous arch.(figure-1) Bilaterally the psoas minor muscles were getting inserted onto the iliopectineal eminence, which was tendinoaponeurotic,

were fusing with iliac fascia. On both sides, the tendons of muscle were found positioned lateral to the external iliac artery. Bilaterally, they received the nerve supply from anterior division of L1 spinal nerve. The genitofemoral nerve was oriented along the medial border of psoas minor muscle bilaterally.

Values referring to total length and length of the muscle's insertion tendon were obtained on a scale of centimeters (cm) by using a measure tape (figure-2) which are shown in table-1.

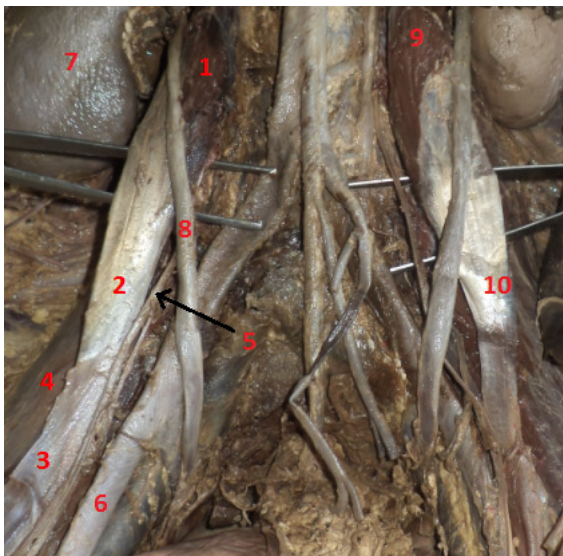


Figure 1: showing bilateral presence of psoas minor muscle,1.Rt psoas minor muscle(belly),2.Rt psoas minor muscle (tendon),3.tendinoaponeurotic part of Rt psoas minor muscle,4.Rt psoas major muscle,5.Rt genito-femoral nerve,6.Rt external iliac artery,7.Rt kidney,8.Rt ureter,9.Lt psoas minor muscle(belly),10.Lt psoas minor muscle (tendon).Rt-right,Lt-left.

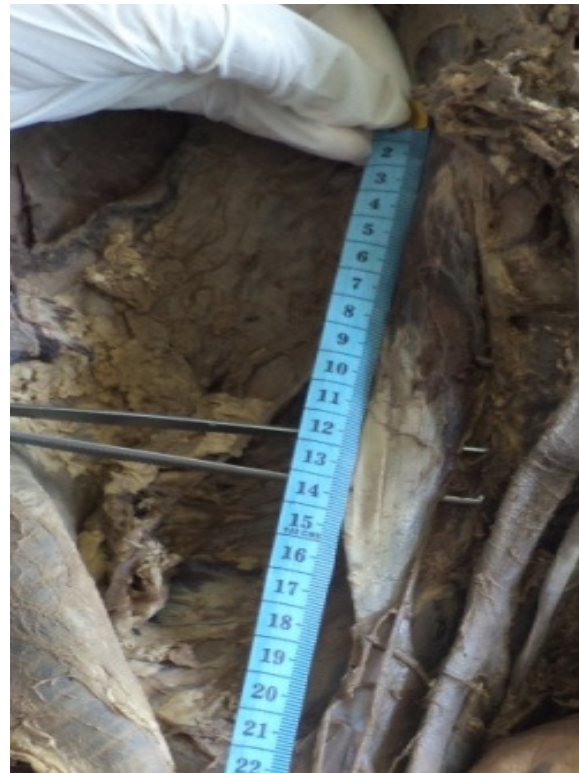

Figure 2: Measuring the total length of the muscle by using a tape measure.

Indian Journal of Basic & Applied Medical Research

Now with Indexed in

HIFA 2015

Muscle		Right	Left
Length	Total	25	25.5
	Belly	9	8
	Tendon	16	17.5
Maximum width	Belly	2.5	2.5
	Tendon	2.2	2.3
Muscle		Right	Left
Length	Total	25	25.5
	Belly	9	8
	Tendon	16	17.5
Maximum width	Belly	2.5	2.5
	Tendon	2.2	2.3
Muscle		Right	Left
Length	Total	25	25.5
	Belly	9	8
	Tendon	16	17.5
Maximum width	Belly	2.5	2.5
	Tendon	2.2	2.3
Muscle		Right	Left
Length	Total	25	25.5
	Belly	9	8
	Tendon	16	17.5
Maximum width	Belly	2.5	2.5
	Tendon	2.2	2.3

[Table 1]

Discussion:

According to Kraychete, the psoas minor muscle was present in only 30% of the cases. Regarding sex, there was no significant difference^[5]. The tendon of this muscle was very

long^[6]. The tendon represented 57% of the total length of the muscle^[4].

In all the fetuses (danillo et al) the fibres of the psoas minor muscle originated in the bodies of the 12th thoracic vertebra and the underlying intervertebral disc, as also found by Lee et al. and Torres et al.(1995).The fibers of the psoas minor muscle originated as a ramification of the fibers of the psoas major in some cases by Macalister^[7].

The duplication of psoas minor has also been seen in the past, where the first belly overlapped the other from before backwards. Infrequently, the ramifications of muscular fibres of psoas major yielding psoas minor have been mentioned as source of unusual origin. Not only can the frequency of its presence vary, but also its morphology. It is not rare to find the psoas minor muscle reduced to only one or two tendons^[4].In a description by Gardner et al, they reported that this muscle was inserted by means of a thin tendon, into the iliopubic eminence and into the arched line, and that it had an additional inconstant insertion into the iliac fascia (as found in this case)and pectineal ligament^[8].

Usually the muscle inserts at the pelvis but sometimes the insertion tendon can descend further down up to the femur making it prone to overstrain. In the long run, it becomes stiff and less flexible. The psoas minor syndrome is attributed to unusual high tone in psoas minor muscle and tendon where, the patient complaints of pain in the lower quadrant of the abdomen. In addition, the pain was aggravated by palpation of the taut tendon in lean individuals presenting with acute abdomen, often mistaken for appendicitis. In this syndrome, there is the limited extension, which impairs ambulation. Tenotomy is the only treatment of choice, which relieves the symptoms^[9]. The comprehension of these muscular variations allows insight into the pattern of localization and spread of infection and malignancy in the retroperitoneal region of the body^[10].

Conclusion:

Psoas minor muscle is regressive muscle. Although the knowledge of normal anatomy and variation of psoas minor is essential because someone that has the muscle and strains it, however, can expect a 50 percent reduction in range of hip motion. Muscle inserts at the pelvis but sometimes the insertion tendon can descend further down up to the femur making it prone to overstrain may lead to psoas minor syndrome. Psoas minor also is subject to racial and ethnic variation. So anatomist and surgeons should aware of its anatomy.

References:

1. Gray H. Anatomia. 29th ed. Rio di Janeiro: Guanabara Kougan; 1977.
2. Moore K, Dally K. Anatomia orientada para a clinica. 5th ed. Rio di Janeiro: Guanabara Kougan; 2007.
3. Tellez V, Acuna L. Consideraciones Anatomicas de los Musculos Inconstantes. Med Unab; 1998.
4. Danillo Ribeiro Guerra, Francisco Prado Reis, Afrânio de Andrade Bastos,, Ciro José Brito, Roberto Jerônimo dos Santos Silva ,José Aderval Aragão: Anatomical Study on the Psoas Minor Muscle in Human Fetuses. Int. J. Morphol:2012;30(1):136-9.
5. Kraychete, D. C.; Rocha, A. P. & Castro, P. A. Psoas muscle abscess after epidural analgesia: case report. Rev. Bras. Anesthesiol., 2007;57:195-8.

6. Macalister, A. Additional observations on muscular anomalies in human anatomy (third series), with a catalogue of the principal muscular variations hitherto published. *Trans. Roy. Irish. Acad.* 1875;25:1-130.
7. Gardener, E.; Gray, D. J. & O'rahilly, R. O abdome. In: Gardener, E.; Gray, D. J. & O'Rahilly, R. *Anatomia. Parede abdominal posterior.* 4a ed. Rio de Janeiro, GuanabaraKoogan, 1988: pp.356.
8. Travell J, Simons D. *Myofascial Pain and Dysfunction: The Trigger Point Manual; Vol. 2., The Lower Extremities.* 2nd ed. Philadelphia: Lippincott Williams and Wilkins; 1998.
9. Dyke JAV, Holley HC, Anderson SD. Review of Iliopsoas anatomy and pathology. *Radiographics.* 1987 Jan 1;7(1):53-84

