

Case Report:

Conventional radiograph verses CT for evaluation of sagittal fracture of mandibular condyle

Dr Anjali Wadhwa, Dr Gaurav Shah, Dr Shweta Sharma, Dr Anand Bhatnagar, Dr Pallavi Malaviya

NIMS Dental College Jaipur, Rajasthan

Corresponding author: Dr Anjali Wadhwa

Date of submission: 18 October 2014 ; Date of Publication: 10 December 2014

Abstract:

Condylar fractures of mandible are not very easy to diagnose radiographically. If fracture is vertical, it would be much more difficult to diagnose. Since treatment depends on type of fracture, CT scan is advised rather than conventional radiographs to diagnose condylar fractures.

Key Words: Sagittal fracture, Mandibular condyle, Conventional radiographs, Axial & Coronal CT

Introduction:

Fracture of the mandibular condyle is very rare among mandibular fractures. Diagnosing not only vertical fracture but also other types of fractures of mandibular condyle is difficult due to its anatomical characteristics¹. Classification of condylar fractures with respect to condylar head to mandibular body is important in choosing the method of treatment, i.e., concerning conservative or open reduction, and has been based upon the classification by Bellinger and MacLennan. Previously, the sagittal split of condyle could not be identified because of overlapping images on plane radiograph, although sometimes PA view of mandible sometimes showed such fractures. The widespread use of CT in recent years has allowed detailed observation of the pathologic state of fractures and some cases of vertical fracture of the mandibular condyle have been reported².

Sagittal fractures of condylar head have special significance since these are intracapsular fractures with highest chances of ankylosis. Hence the

importance of diagnosis especially in young patients.

We encountered two cases of vertical fracture of the mandibular condyle which were visualized by computed tomography (CT) though OPG showed no fracture and initially diagnosis made was traumatic arthritis.

Case report:

Case 1:

A female patient reported to NIMS Dental College Jaipur, in the department of oral and maxillofacial surgery on May 2014, with the chief complaint of pain in left preauricular region. There was a history of fall from bike one week before. Swelling was present on left side of face after trauma and was subsided by medication. No history of ear bleed was present at the time of trauma. On palpation, head of condyle was present in the glenoid fossa and movements were diminished on left side. Orthopantomogram (O.P.G) was advised but no fracture was visible. (fig 1) Initial diagnosis given was traumatic arthritis and patient was advised soft diet and moist heat application. Patient was not

completely relieved from pain when she reported in the department after 15 days. C.T. was advised that showed , sagittal fracture of left condyle in axial section. (fig 2) Intermaxillary fixation was done for 15 days.

Case 2:

A male patient, reported to the department after road traffic accident. There was swelling in left preauricular region with a history of ear bleed. Mouth opening was not restricted but movements of mandible were painful. Patient had tenderness in left preauricular region. Condyle was present in the glenoid fossa and movements were perceptible on both sides. O.P.G again revealed no fracture in either condyle (fig 3) but C.T. showed not only sagittal fracture of left condylar head but also a medial displacement of the medial fragment (fig 4,5,6). A soft diet and limited mouth opening were advised for 15 days.

Discussion:

For the diagnosis of mandibular condyle fracture, radiographic as well as clinical findings are important. However, radiography sometimes does not provide adequate information due to the anatomical characteristics of the fracture area.^{1,2} Anatomically, the medial pole of the condyle extends far beyond the condylar neck and has a greater chance of being split in the sagittal plane, resulting in sagittal fracture of mandibular condyle. The sagittal fracture line usually passes through an area between the lateral one-third and the medial one-third of the condyle³ Vertical fracture of the mandibular condyle is often difficult to diagnose by plane radiography due to its anatomical characteristics¹. With the introduction of CT, the incidence of sagittal fracture of mandibular condyle appeared to increase and was reported to be 9–29% in the cases of condylar fractures. In order to interpret the displacement of the fractured fragment on the coronal sections of the CT images, the

sagittal fracture of condyle were classified into three types²

Type I (fissure type) : The medial part of the condyle split and formed a V-shaped gap between the fragment and the lateral pole of the condyle.

Type II (displacement type): the fractured fragment was anteromedially displaced, and the lateral pole of the condyle was located within the fossa.

Type III (dislocation type): the fractured fragment was anteromedially displaced.

On conventional radiographs the orbito ramus projection, Antero-posterior projection and oblique transcranial projections, it is often unusual to visualize the structures of the internal minor fragments in detail. Salon et al noted that displaced supracondylar fracture on the medial aspect of the temporomandibular joint showed no evidence of fracture by orthopantomogram and multiple standard films, but was clearly defined by CT scanning. This may be due to the fact that the shadow of the minor fragments gives overlapping images with other radiopaque structures around the condyle such as petrous portion of the temporal bone and the zygomatic bone⁴. The direction of radiographic projection may be restricted by functional limitations in the mandibular condyle. Furthermore, no clear correlation was found between the manifestation of clinical findings and the extent of fragment displacement as demonstrated radiographically. Therefore proper radiographic projections in different directions are necessary to diagnose the fracture of the condylar head. However, a split in the sagittal plane of condyle is not visible with a lateral, oblique or panoramic radiograph but only with anteroposterior, transorbital projections of

temporomandibular joint. Therefore, the plane radiograph should be supported routinely by views in axial and coronal computerized tomography, if a sagittal split fracture of the mandibular condyle is suspected².

Avrahani et al performed coronal CT for close examination in a patient who did not show a fracture line by plain radiography at the first consultation, but developed temporomandibular joint ankylosis during follow up⁵. Occlusal reduction is easier in vertical fracture of mandibular condyle than in fracture of the neck of the articular process, since the height of the mandibular ramus is maintained. Therefore, the treatment methods selected should place importance on the recovery of jaw motor function¹.

With regard to treatment, open reduction may be recommended in some of the dislocated fracture cases. However, the operative field is too narrow and restricted to treat the condylar head even if it is not markedly dislocated, especially anteromedially. Yamaoka M et al recommend inter maxillary fixation for 14 days. Ankylosis does not occur and conservative treatment gives satisfactory result². The condyle has its blood supply by way of superficial temporal artery through its parotid branches and the maxillary artery through its deep auricular and pterygoid branches and condyle would be revascularized readily even if muscle fibers are stripped from condyle head⁶.

Conclusion:

The sagittal split of condyle could not be identified because of overlapping images on plane radiograph due to its anatomical characteristics of the fracture area. Therefore, the plane radiograph should be supported routinely by views in axial and coronal computerized tomography when TMJ fracture is suspected. Since such type of fractures can be easily confused with traumatic arthritis. Specially in young patients, where chances of ankylosis are

most, it is required that it should be differentiated from traumatic arthritis. Treatment modality of both is different and therefore CT should be advised.

Fig.1. OPG of case 1.

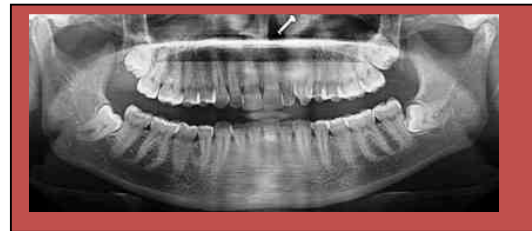


Fig.2. Axial CT of case 1 showing sagittal fracture of Lt condyle.

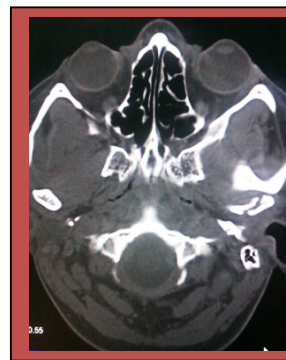

Fig. 3.. OPG of case 2

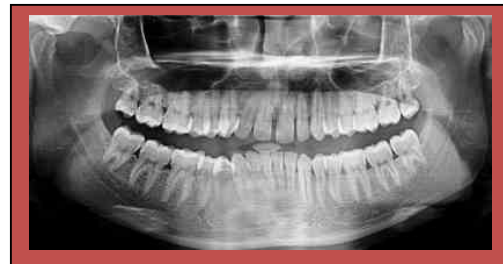

Fig. 4. Axial CT OF case 2 showing sagittal fracture of Lt condyle.

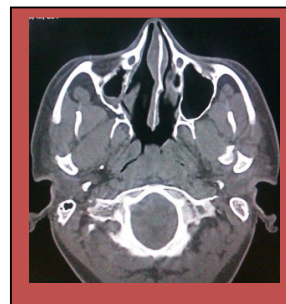


Fig. 5. Coronal CT of case 2 showing sagittal fracture of Lt condyle.

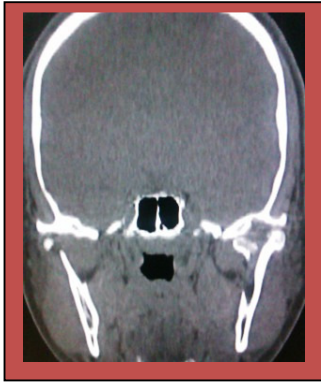
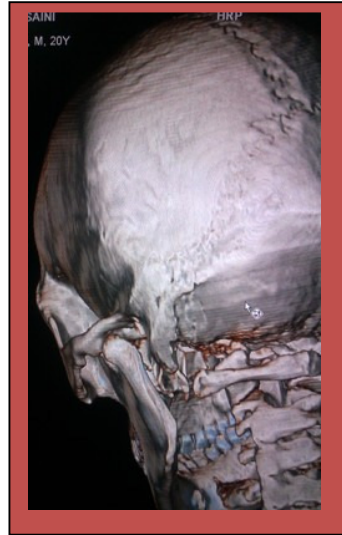
Fig.6. 3D CT of case 2 showing sagittal fracture of Lt condyle.



References:

- 1) Hakubun Yonezu, Takashi Yakushiji, Ken'ichiro Suga.at.al. Vertical fracture of Mandibular condyle treated with Intra-articular Pumping therapy: A case report. Institutional resources of unique collection and academic activities at Tokyo dental college.2009; 50(1):37-40.
- 2) Yamaoka M, Furusawa K, Iguchi K, Tanaka M, Okuda D. Assessment of fracture of mandibular condyle by use of computerized tomography. Incidence of sagittal split fracture. Br j oral maxillofac surg 1994; 32: 77-75.
- 3) Duan D.H , Zhang Y, A clinical investigation on disc displacement in sagittal fracture of the mandibular condyle and its association with TMJ ankylosis development. Int. J. Oral Maxillofac. Surg. 2011; 40: 134–138.
- 4) Salon J M, Ross R. Computer assisted scanning of supracondylar fractures. Oral Surg Oral Med Oral Pathol. 1990;69: 133.
- 5) Avrahami E, Horowitz I 1984 chip fracture of mandibular condyle. Head Neck Surg 6: 978-981.
- 6) Hendrix JH, Sanders SG, Green B. Open reduction of mandibular condyle. Plastic Reconstr Surg , 1959; 23: 283.

