

Case Report:

Case of modern time foreign body in urinary bladder: A earphone wire

Dr Vikash Lal, Dr Ashish Dhande, Dr Kirtibala Dhande, Dr Bibekanand Mahapatra, Dr Pranav Narayan, Dr Tanveer Shaikh

Department of Surgery, Pad.Dr.D Y Patil Medical College, Nerul, Navi Mumbai, Maharashtra India

Corresponding author: Dr Vikas Lal

Date of submission: 16 October 2014; Date of Publication: 10 December 2014

Abstract

Foreign bodies in the urinary bladder are frequently the objects of jokes among doctors, but they may sometimes cause serious implications to the patients. Here we present A case where long segments of earphone wire were introduced into the urinary bladder through the urethra.

Key words: urinary bladder; foreign bodies; , earphone wire ,intravesical foreign body

Introduction

A multitude of foreign bodies have been found in the urinary bladder, such as bullet, pieces of candle, a thermometer, a needle, , a safety pin, an animal feather, chewing gum, a Steinman pin, a gauze pack, a toothbrush, a metal hook, and a scalpel blade etc., as reported in the literature ¹⁻³In most cases, they are either self introduced to produce erotic sensations and sexual gratification or introduced by someone else to get relief from urinary complaints ². Here we report a case and their successful management.

Case reports

A 31-year-old male presented with complaints of dysuria, and suprapubic pain that had lasted for 1 weeks. A physical examination was unremarkable. Urinalysis showed plenty of pus cells with significant growth of E. coli in the urine culture. An X-ray of the pelvis showed a coiled up radiopaque shadow in the bladder region ([Figure-1](#)). Upon further interrogation, the patient admitted that he was used to masturbating by introducing an earphone wire through the urethra. 10 days back, he had lost the earphone wire inside his

erected penis during this process under the influence of alcohol. Under general anesthesia, a 35-inch long earphone wire was removed through 20 F cystoscope with an uneventful recovery.

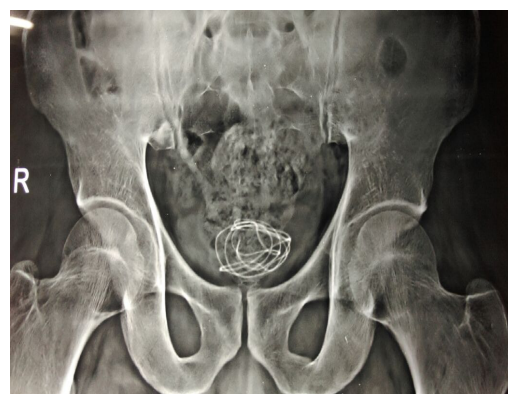


Figure 1

IJBAMR is now with
IC Value 5.09



Figure 2

Conclusion

Foreign bodies may find their way into the urinary bladder by accident, deliberate introduction through the urethra or migration from the neighboring organs⁽¹⁻³⁾. When a wire is introduced through the urethra,

part of it remains in the urethra and part goes to the bladder cavity. At the time of micturition, the contracting bladder curled the part of the wire that had partly moved into the bladder from the urethra. Gradually the whole of the wire originally present in the urethra was pulled into the bladder⁽²⁾. To avoid embarrassment, patients tend to seek treatment late, often waiting until the problem becomes symptomatic⁽³⁾. Usually the patients present with urethritis, cystitis, recurrent UTI, or hematuria⁽¹⁻³⁾. X-rays are sufficient to diagnose such conditions. Intravenous urography rarely gives any additional information, and is indicated only to diagnose radiolucent objects. Cystoscopy gives the final diagnosis in doubtful cases. Managing the situation seeks to remove the foreign body with minimum trauma, and cystoscopic removal is the ideal approach. Where a stone has formed, it should be broken by litholapaxy or intracorporeal lithotripsy together with the removal of the foreign body. Large foreign bodies may be removed by supra-pubiccystostomy where endoscopic removal is not possible.

References

1. Eckford SD, Persad RA, Brewster SF, Gingell JC: Intravesical foreign bodies: five-year review. *Br J Urol.* 1992; 69: 41-45.
2. Kenney RD: Adolescent males who insert genitourinary foreign bodies: is psychiatric referral required? *Urology.* 1988; 32: 127-9.
3. Pal DK: Intravesical foreign body. *Ind J Surg.* 1999; 61: 381-3.