

Original article:

Normal splenic volume assessment on CT in Nepalese population

Chhetri PK¹, Poudel S²

¹Associate Professor, ²Lecturer

Department of Radiology, College of Medical Sciences-Teaching Hospital, Bharatpur, Chitwan, Nepal

Corresponding author: Dr Pramod Kumar Chhetri

ABSTRACT

Introduction: Spleen is a reticulo-endothelial and a lymphoid organ. The accurate assessment of normal splenic volume is important to differentiate normal from an enlarged spleen. It is involved in various pathological conditions which may be manifested simply as splenomegaly.

Aims & objectives: To obtain normal splenic volume in patients undergoing CT abdomen and to compare with studies done in other populations.

Method: A hospital based cross sectional observational study conducted among 150 patients undergoing CT abdomen examination in College of Medical Sciences- Teaching Hospital during the period April 2015 to September 2016. The relationship between spleen volume with age, sex and linear measurements of spleen were also indentified.

Result: The mean splenic volume was $130.16 \pm 29.8 \text{ cm}^3$, ranging from 49.5 to 201.4 cm^3 . There was no significant correlation of spleen volume with gender. There was significant negative correlation of spleen volume with age. There was significant correlation of spleen volume with linear parameters of measurement, among which cranio-caudal length of spleen showed best correlate.

Conclusion: CT is a reliable imaging modality for assessing splenic volume and linear parameters of spleen. However the normal splenic volume differed among various populations. The finding suggests that the defining criteria for splenomegaly differed among populations.

Key Words: CT, normal spleen volume

Introduction

Spleen is a reticulo-endothelial and lympho-haemopoietic organ. It is located in left hypochondrium beneath 9th and 10th intercostal spaces. Histologically splenic parenchyma consists of red pulp, white pulp and marginal zone.¹ Spleen is derived from mesodermal condensation of dorsal mesogastrium at the end of fourth embryonic week. Because of independent condensation of mesoderm, splenunculi and polysplenia can occur.² Spleen enlarges with reactive proliferation of various cells like lymphocytes, reticuloendothelial cells and infiltration with lymphoma, neoplastic cells and lipid-laden macrophages. It also gets enlarged with extramedullary haemopoiesis, proliferation of phagocytic cells, in response to increase destruction of blood cells and by vascular congestion in presence of portal hypertension. Therefore it is important to evaluate splenic size as splenomegaly is an important clinical sign.³ There are various imaging modalities for evaluation of spleen size e.g-plain radiograph, USG, CT, MRI and radionuclide scan. Plain radiography is unreliable and has become obsolete these days. USG is reliable but is limited for accurate assessment because of irregular contour of the spleen, difficulty in visualizing entire organ due to overlying structures such as bone, bowel gas or kidney. Also, determination of splenic size by USG is observer

dependent. Thus, USG is less efficient than CT since these drawbacks are not seen in CT.⁴ MRI has advantage of being non- ionizing with better soft tissue contrast. However, it is more costly and more time consuming and not feasible in all patients.⁵ CT is thus a reliable method for assessing the exact size and volume of spleen and it can accurately visualize the irregular margins of the spleen. It is also not operator dependent, and is reproducible. However, its limitations include its higher cost and use of ionizing radiation.⁶

Due to wide variation in height and physical built in various populations, a single study in one population cannot be used as reference value for all the populations. The purpose of this study was to obtain normal splenic parameters in Nepalese population and to compare with studies done in other populations.

Methods:

This study was undertaken in the Department of Radiology, College of Medical Sciences - Teaching Hospital from the period April 2015 to September 2016. 150 consecutive patients who were referred for CT scan of the abdomen for various abdominal conditions were included in this study. All patients with known splenomegaly on prior ultrasonography or known splenic disorders were excluded from the study. All the patients gave prior informed consent for a contrast enhancement CT. CT was obtained (MDCT 160 slice Aquillon Prime) and reviewed at 10 mm thickness section cranio-caudal.

For spleen volume measurement, each 10 mm section showing spleen were selected. Splenic area from each 10 mm section were measured by tracing the margins of the spleen and then summed up. As slice thickness was 1 cm, area was equal to volume and splenic volume was obtained.

Various linear parameters like maximum splenic width, maximum splenic thickness, cranio-caudal length and length along long axis were also obtained. Age and sex of the patient was also noted for the assessment of splenic volume. The data were used to determine the spleen volume and its relationship with age and sex by using SPSS 20.0 software program. Normality test was done and data were analyzed by using student t-test and Pearson's correlation coefficient to determine correlation of splenic volume with age, sex and linear measurements of spleen.

Results:

Among 150 patients included in the study, 74 (49%) were male and 76 (51%) were female. Maximum number of patients were in the age group of 41-50 years and the least number of patients were in age group of 1-10 years. Figure I show the histogram with distribution curve of spleen volume.

As shown in Figure 2, the mean spleen volume was 130.16 cm³ with standard deviation of 29.80. Mean splenic volume was 110.7 cm³ in 1-10 years age group, 124.6 cm³ in 11-20 years age group, 132.48 cm³ in 21-30 years age group, 140.7 cm³ in 31-40 years age group, 135.9 cm³ in 41-50 years age group, 131.5 cm³ in 51-60 years age group, 123.1 cm³ in 61-70 years age group, 111.9 cm³ in 71-80 years age group and 78.7 cm³ in 81-90 years age group. With age, mean spleen volume increased and reached maximum in the age group of 31-40 years. However, the mean splenic volume decreased with increasing age and reached minimum after 80 years.

As shown in Table I, the mean of maximum width of spleen was 8.7 cm with standard deviation of 1.45. Range of splenic width was 5.1-12.2 cm.

The mean maximum thickness of spleen was 4.9 cm with standard deviation of 1.18. Range of maximum thickness of spleen was 2.7-7.7 cm.

The mean length of spleen along the long axis was 9.1 cm with standard deviation of 1.33. Range of length of spleen along the long axis was 5.9-12.1 cm.

The mean craniocaudal length of spleen was 7.9 cm with standard deviation of 1.38. Range of craniocaudal length of spleen was 5-11 cm.

As shown in Table 2, significant positive correlations were noted between spleen volume and rest of the linear measurement of spleen [Craniocaudal length ($r=0.669$, $p<0.001$), length along long axis ($r=0.662$, $p<0.001$), width ($r=0.597$, $p<0.001$) and maximum thickness ($r=0.566$, $p<0.001$)]. Strongest correlation of the spleen volume among its linear measurements was with craniocaudal length of spleen followed by length along long axis. Negative significant correlation of the splenic volume with age ($r= -0.263$, $p=0.001$) was noted.

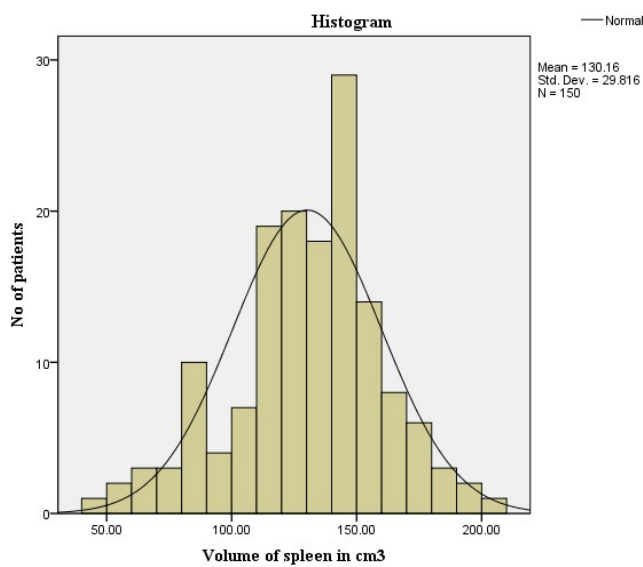


Figure 1: Histogram with distribution curve of spleen volume

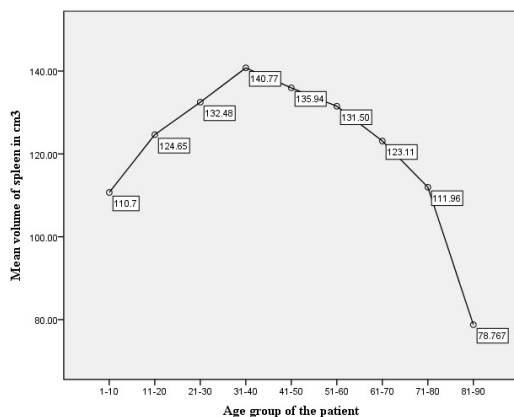


Figure 2: Diagram showing mean splenic volume in various age groups.

Table 1: Mean and standard deviation of different parameters of measurements of spleen

	No. of patients	Mean± SD	Maximum	Minimum
Spleen volume (cm ³)	150	130.16±29.8	201.4	49.5
Width of spleen (cm)	150	8.7±1.4	12.2	5.1
Maximum thickness of spleen (cm)	150	4.9±1.1	7.7	2.7
Length of spleen along long axis	150	9.1±1.3	12.1	5.9
Craniocaudal length of spleen (cm)	150	7.9±1.3	11	5

Table 2: Correlation of spleen volume with other variables.

	r value	p value
Age	-0.263	<0.001
Craniocaudal length of spleen	0.669	<0.001
Length of spleen along long axis	0.662	<0.001
Maximum thickness of spleen	0.566	<0.001
Maximum width of spleen	0.597	<0.001
Sex	0.037	0.656

Discussion:

The mean spleen volume in our study was $130.16 \pm 29.8 \text{ cm}^3$ (range from 49.5 - 201.4 cm^3). A very similar study by Suwal S et al⁷ noted spleen volume in Nepalese population to be $151.20 \pm 59.62 \text{ cm}^3$ (range from 25.95 – 331.66 cm^3). The cause for this discrepancy done on the same population could not be explained except that the above study was done in the capital city Kathmandu valley while our populations were mainly from terai or the plain areas.

Using 3D abdominal CT scan images, Adil Asghar et al⁸ noted mean splenic volume of $161.57 \pm 90.2 \text{ cm}^3$ in North Indian population. One reason for the higher splenic volume could be that only adult population were included in their study (age of patients ranged from 20 to 70 years).

Another study in India by Anitha Jasper⁹ noted a mean splenic volume of $194.6 \pm 78 \text{ cm}^3$ (age of patients was 18 to 64 years). The splenic volume in this study was thus the highest compared to all the above mentioned studies.

However, our findings are in accordance with study by S Srisajjakul et al¹⁰ in 426 Thai adult population, who reported splenic volume to be $124.1 \pm 51.8 \text{ cm}^3$. Kaneko et al¹¹ also reported a mean \pm S.D splenic volume of $112 \pm 40 \text{ cm}^3$ in 150 Japanese population.

On the contrary, Badaran et al¹² who conducted a study in Jordanian population found splenic volume to be $184.15 \pm 79.5 \text{ cm}^3$ and Siddiqui MA et al¹³ found average splenic volume $161.42 \pm 54.91 \text{ cm}^3$ in Saudi Arabian populations. Similarly in western population, Henderson et al¹⁴ proposed mean splenic volume of 219 cm^3 in a normal population. Maximum mean \pm S.D splenic volume of $333.6 \pm 116.1 \text{ cm}^3$ was obtained by Spielman et al¹⁵ in American population by USG. These disparities in the volume of spleen may be due to differences in height and physical built between the various populations.

Age is important factor in the involution of many viscera including spleen. In our study there was negative correlation of the spleen volume with age. Our findings are similar to the findings by McCornick and Kashgarian¹⁶ and Harris et al¹⁷. They concluded that spleen weight reduced with age. In our study, spleen volume reduced with age. Our study showed that the size of the spleen increased with age reaching maximum size during 31-40 years. The size of the spleen then steadily decreased with increasing age with minimum size after 80 years.

In our study, there was no significant gender difference of the spleen volume between male and female individuals. The mean splenic volume were similar in both male and female. Our findings were similar to the findings of Pietri and Boscaini¹⁸ & Kaneko et al.¹¹.

In our study, we measured maximum width of the spleen, maximum thickness of the spleen, length of the spleen along its long axis and craniocaudal length of the spleen. All of these parameters showed significant positive correlation with splenic volume, with the best single correlation being craniocaudal length of spleen followed by length along long axis of spleen. These findings are similar to the findings by Linguraru et al.¹⁹ who found best correlation of the spleen volume with craniocaudal length and width of the spleen among the linear parameters of the spleen.

Conclusion:

Mean splenic volume in our study was 130.16 cm³ (with standard deviation of 29.8). However the normal splenic volume differed among various populations. The finding thus suggests that the defining criteria for splenomegaly differed among populations.

Splenic volume followed a lymphoid growth curve as it increased with age during childhood and adolescent with maximum spleen size at age group of 31-40 years and then decreased subsequently.

There was no significant difference between splenic volume in male and female in this study.

There was a significant correlation of spleen volume with linear parameters of spleen in our study. Maximum correlation of spleen volume was seen with the craniocaudal length of the spleen.

References:

1. Benter T, Kluhs L, Teichgraber U. Sonography of the spleen. *J Ultrasound Med.* 2011;30(9):1281-93.
2. Robertson F, Leander P, Ekberg O. Radiology of the spleen. *Eur Radiol.* 2001;11(1):80-95.
3. Ishibashi H, Higuchi N, Shimamura R, Hirata Y, Kudo J, Niho Y. Sonographic assessment and grading of spleen size. *J Clin Ultrasound.* 1991;19(1):21-5.
4. Asghar A, Naaz B, Agrawal D, Sharma PK. Morphometric study of spleen in North Indian adult population: CT scan image based study. *J Clin Diagn Res.* 2011;5(5):974-7.
5. Mazonakis M, Damilakis J, Maris T, Prassopoulos P, Gourtsoyiannis N. Estimation of spleen volume using MR imaging and a random marking technique. *Eur Radiol.* 2000;10(12):4.
6. Breiman RS, Beck JW, Korobkin M, Glenn R, Akwari OE, Heaston DK, et al. Volume determinations using computed tomography. *AJR Am J Roentgenol.* 1982;138(2):329-33.
7. Suwal S, Subedi K, Gurung G. Assessment of normal splenic volume by Computed Tomography in Nepalese population. *Journal of Institute of Medicine,* Dec, 2015, 37:3

8. Asghar A, Agrawal D, Yunus SM, Sharma PK, Zaidi SHH, Sinha A. Standard Splenic Volume Estimation in North Indian Adult Population: Using 3D Reconstruction of Abdominal CT Scan Images. *Anatomy Research International*. 2011; 2011
9. Anitha Jasper. Liver and Splenic Volumes in the Indian Population: Is There a Single CT Measurement Correlate? *Journal of Clinical and Diagnostic Research*. 2019 Aug, Vol-13(8): TC01-TC05
10. Srisajjakul S, Prapaisilp P, Laorratkul N. Normal splenic volume assessment on CT in 426 Adults. *Sriraj Med J*. 2012;64(2):43-6.
11. Kaneko J, Sugawara Y, Matsui Y, Ohkubo T, Makuuchi M. Normal splenic volume in adults by computed tomography. *Hepatogastroenterology*. 2002;49(48):1726-7.
12. Badran DH, Kalbouneh HM, Al-Hadidi MT, Shatarat AT, Tarawneh ES, Hadidy AM, et al. Ultrasonographic assessment of splenic volume and its correlation with body parameters in a Jordanian population. *Saudi Med J*. 2015;36(8):967-72.
13. Mohammad Aslam Siddiqui, Ali Hassan A. Ali, Mohamed Abdelmohsen Bedewi, Omar O. Serhan. Estimation of Standard Splenic Volume in Saudi Arabian Adult Population: Using 3D Reconstruction of Abdominal CT Scan Images. *Open Journal of Internal Medicine*, 2014, 4, 7-12
14. Henderson JM, Heymsfield SB, Horowitz J, Kutner MH. Measurement of liver and spleen volume by computed tomography. Assessment of reproducibility and changes found following a selective distal splenorenal shunt. *Radiology*. 1981;141(2):525-7.
15. Spielmann AL, DeLong DM, Kliwer MA. Sonographic evaluation of spleen size in tall healthy athletes. *AJR Am J Roentgenol*. 2005;184(1):45-9.
16. McCormick WF, Kashgarian M. The weight of the adult human spleen. *Am J Clin Pathol*. 1965;43:332-3.
17. Harris A, Kamishima T, Hao HY, Kato F, Omatsu T, Onodera Y, et al. Splenic volume measurements on computed tomography utilizing automatically contouring software and its relationship with age, gender, and anthropometric parameters. *Eur J Radiol*. 2010;75(1):97-101.
18. Pietri H, Boscaini M. Determination of a splenic volumetric index by ultrasonic scanning. *J Ultrasound Med*. 1984;3(1):19-23.
19. Linguraru MG, Sandberg JK, Jones EC, Summers RM. Assessing splenomegaly: automated volumetric analysis of the spleen. *Acad Radiol*. 2013;20(6):675-84.