

Original article:

Virtual bronchoscopy in the evaluation of children with suspected foreign body aspiration

¹Dr.Kalyan Prasad T V , ²Dr. Y.P. Sachdev*, ³Dr. Ravindra Kawade, ⁴Dr. D.S. Kulkarni.

Department of Radio-diagnosis, Rural Medical College of Pravara Institute of medical sciences (DU) , Loni, Maharashtra, India.

Corresponding author*

Abstract

Introduction- Computed tomography (CT) virtual bronchoscopy is a noninvasive technique that provides an internal view of trachea and major bronchi by three-dimensional reconstruction.

Aims and objectives- The aim of this study was to investigate the usefulness of virtual bronchoscopy in the evaluation of suspected foreign body aspiration in children.

Materials and methods- Fifteen children with a mean age of 2.4 years (8 months-12 years) who were admitted to emergency room with a suspicion of foreign body aspiration were included in this study. spiral computed tomography scans and virtual bronchoscopy images were obtained. Then, rigid bronchoscopy was performed within 24 h.

Results- CT virtual bronchoscopy and conventional bronchoscopy revealed the location of the foreign body in thirteen patients. It was in the right main bronchus in six patients, in the right lower lobe bronchus in three patients, at the level of carina in one patient and in the left main bronchus in three patients.

Discussion- Airway foreign bodies remain a diagnostic challenge to health care professionals. Organic foreign bodies, such as nuts, are the most frequently inhaled foreign bodies.

Conclusion - Helical CT scanning with virtual bronchoscopy should be performed in only selected cases with suspected foreign body aspiration. When the chest radiograph is normal and the clinical diagnosis suggests aspirated foreign body, helical CT and virtual bronchoscopy can be considered in order to avoid needless rigid bronchoscopy.

Introduction

Airway foreign bodies remain a diagnostic challenge to health care professionals. A sudden onset of respiratory symptoms must alert the clinician to the presence of a foreign body.¹ Airway foreign body present with coughing, choking, acute dyspnoea and sudden onset of wheezing. Foreign body aspiration is an important cause of morbidity and mortality in childhood and occurs most frequently in children between 6 months and 3 years old [1, 2]. Diagnosis of such airway foreign body (FB) rests on a relatively new imaging modality – Virtual bronchoscopy. Advances in CT scanning with rapid imaging and volumetric data acquisition have resulted in significant improvement in imaging of the tracheobronchial tree. This data may be reconstructed into three dimensional (3D) images, including internal virtual endoscopic version that closely resembles bronchoscopic images. Virtual bronchoscopy or “flythrough” methods combine the features of endoscopic display and cross-sectional volumetric imaging. This presentation of volumetric data allows not only studying the inner wall surfaces but also allows navigating inside the virtual organs. It may be helpful for detection of foreign bodies. This technique offers a detailed view of the airways, with reduced risk of infection or perforation and facilitates preoperative planning for airway interventions that would otherwise not be possible.²In presence

of a positive clinical diagnosis & inconclusive chest radiography, CT virtual bronchoscopy must be considered in all cases of tracheobronchial FB aspiration, in order to avoid needless rigid bronchoscopy. Virtual bronchoscopy simulates an endoscopist's view of the internal surface of the airway. It gives excellent results regarding location, severity and shape of airway narrowing. VB is proving to be a very helpful investigation modality in patients of a compromised airway. VB works well in planning the further management protocol not only in conjunction with other modalities but also on its own.³

Aims and objectives

The aim of this study was to investigate the usefulness of virtual bronchoscopy in the evaluation of suspected foreign body aspiration in children. To identify the location of foreign body in tracheobronchial tree by virtual bronchoscopy. To determine if this noninvasive procedure is feasible in our society and can provide adequate information for diagnostic utilization.

Materials and methods

study design: Prospective observational study

study population: Study population includes patients of age group 12 years and below referred to Radiology department, at rural medical college, Ioni, for the evaluation of foreign body aspiration. All the patients with suspected foreign body aspiration will be initially evaluated by xray and will be further evaluated by virtual bronchoscopy and rigid bronchoscopy.

study sample: 15 cases. (All patients with suspected foreign body aspiration referred to radiology department, rural medical college, Ioni.

study period: 1 year i.e. from May 2018 to May 2019.

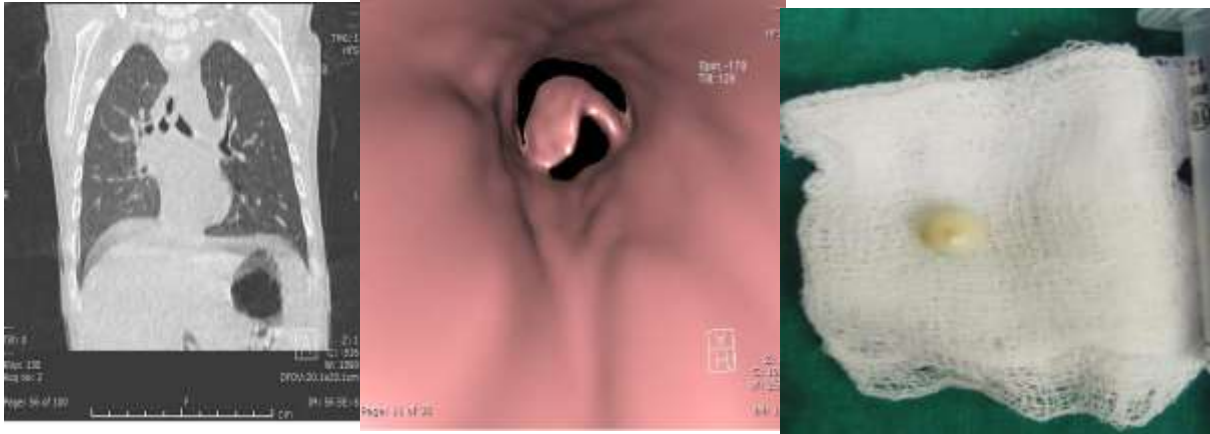
inclusion criteria: All patients aged 12 years and below with a history suggestive of foreign body in the tracheobronchial tree, such as sudden onset of cough, difficulty in breathing, wheezing and decreased air entry into lungs.

exclusion criteria: Patients aged 13 years and above and patients presenting with features of cerebral hypoxia secondary to foreign body aspiration.

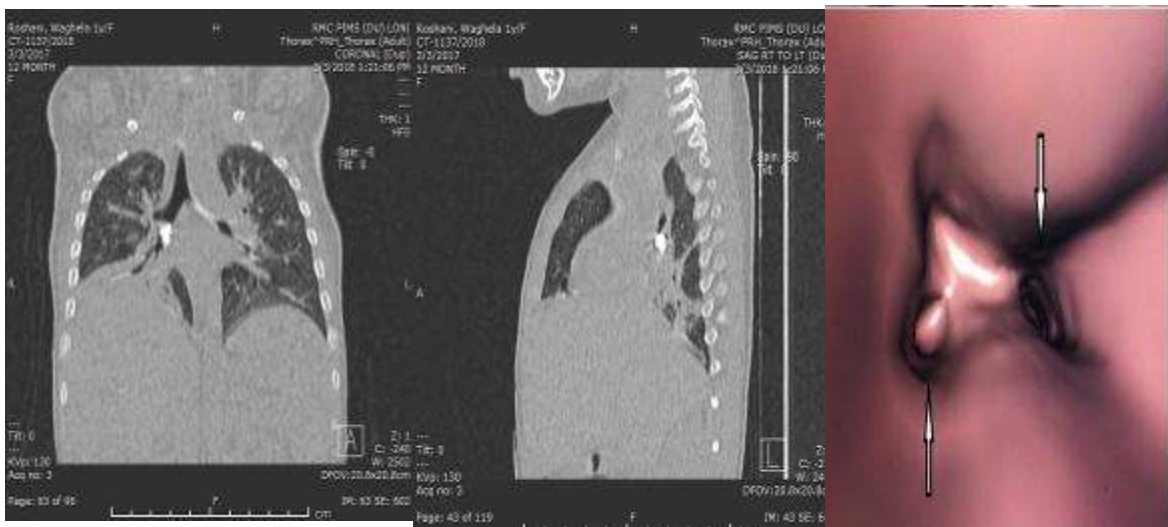Results:

A total 15 children (8 females and 7 males), mean age of 2.4 years (range from 8 months to 12 years), presented to our department with suspected FB inhalation. CT virtual bronchoscopy and conventional bronchoscopy revealed the location of the foreign body in thirteen patients. It was in the right main bronchus in six patients, in the right intermediate lobe bronchus in three patients, at the level of carina in one patient and in the left main bronchus in three patients. Chest radiography in five of 15 patients with foreign bodies showed hyperaeration of the ipsilateral lung, infiltrates in two patients; and atelectasis in one patient. Seven of the 15 patients had normal findings on chest radiography. Chest radiography revealed metallic object in the bronchial tree in one and stone in one of 15 patients. Hyperaeration (n = 5) is the most common additional thoracic CT findings, followed by infiltration (n = 3) and bronchiectasis (n = 1). Axial CT images, virtual bronchoscopy, and conventional bronchoscopy did not reveal foreign bodies in two patients. In these two, CT showed mucous plug in one patient. Findings of CT and chest radiography were normal in one patient. All patients were evaluated endoscopically after CT virtual bronchoscopy was performed. All foreign bodies were removed successfully except in two patients. We removed the following foreign bodies: nuts in 9 patients, metallic object, stone, piece of coconut and tamarind seed one in each patient. In one patient, the foreign body was impacted in the left main

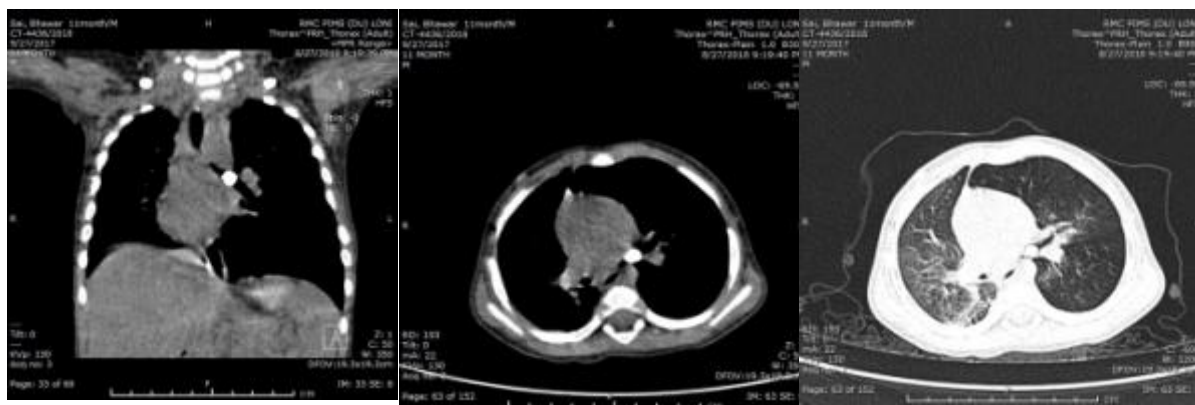bronchus and thus the removal was unsuccessful. after giving treatment for 5 days with steroids, repeat bronchoscopy was done with successful removal. In one patient only part of the foreign body has removed and the remaining foreign body passed distally as a small fragment.



A eight years male patient complaining of sudden onset of cough and wheezing since 1 day showing foreign body in the trachea at the level of bifurcation in coronal image and in virtual bronchoscopy respectively. Rigid bronchoscopy revealed Peanut as the foreign body as shown in the figure.



A one year female patient complaining of sudden onset of cough and wheezing since 1 day showing foreign body(metal object) in the right intermediate bronchus in coronal, sagittal images and in virtual bronchoscopy respectively. Rigid bronchoscopy revealed metal object as the foreign body.



A 11 month male patient complaining of sudden onset of cough, showing foreign body(stone) in the left main bronchus in coronal, axial images respectively. Hyperaeration of the left lung is noted in lung window axial image. Rigid bronchoscopy revealed stone as the foreign body.

Rigid bronchoscopy confirmed the same results (presence and location of foreign bodies) as those of CT virtual bronchoscopy. The sensitivity and specificity of CT virtual bronchoscopy compared with rigid bronchoscopy were 100%. CT is the diagnostic technique used to detect foreign bodies. It not only can reveal foreign bodies in the bronchial tree but also is very sensitive in showing differences in density in the lung parenchyma. The most reliable CT findings of an aspirated foreign body are its presence within the lumen of the tracheobronchial tree.

Discussion

Virtual bronchoscopy locates the exact site of foreign body and during the procedure of rigid bronchoscopy it is helpful in reaching the location of foreign body easily, thus minimizing the trauma to the tracheobronchial tree. Virtual endoscopy of the tracheobronchial system is a relatively new postprocessing technique. Because of a perspective-rendering algorithm, virtual bronchoscopy simulates an endoscopist's view of the internal surface of the airway. The observer **may interactively** move through the airway. Retained secretions and artifacts may result in false-positive findings; virtual bronchoscopy cannot show the morphology, vascularity, or color of the mucosa [6]. Another limitation of our study is that virtual bronchoscopy could not show the segmental and subsegmental parts of the tracheobronchial system. Recent progress in medical imaging, with the development of Helical CT has decreased the acquisition time and improved image quality. 3D images on the basis of CT can provide virtual bronchoscopy, thereby facilitating the management of bronchial FB in children by replacing RB in doubtful cases. This examination can be performed in children without sedation, as it only takes a few seconds in a cooperative patient.

Conclusion

Helical CT scanning with virtual bronchoscopy should be performed in referred cases with suspected foreign body aspiration. When the chest radiograph is normal and the clinical diagnosis suggests aspirated foreign body, helical CT and virtual bronchoscopy can be considered in order to avoid needless rigid bronchoscopy.

References

- [1] Mu L, He P, Sun D. The causes and complications of late diagnosis of foreign body aspiration in children. Report of 210 cases. Arch Otolaryngol Head Neck Surg. 1991;117(8):8769.
- [2] Kaneko M, Eguchi K, Ohmatsu H, et al. Peripheral lung cancer: screening and detection with low-dose spiral CT versus radiography. Radiology 1996;201:798–802.

- [3] Diederich S, Lenzen H, Windman R, et al. Pulmonary nodules: experimental and clinical studies at low-dose chest radiography. *Radiology* 1999;213:289–298.
- [4] Applegate KE, Dardinger JT, Lieber ML, et al. Spiral CT scanning technique in the detection of aspiration of LEGO foreign bodies. *Pediatr Radiol* 2001;31:836–840
- [5] Metrangolo S, Monetti C, Meneghini L, Zadra N, Giusti F. Eight years' experience with foreignbody aspiration in children: what is really important for a timely diagnosis? *J Pediatr Surg* 1999;34:1229–1231.
- [6] Summers RM, Shaw DJ, Shelhamer JH. CT virtual bronchoscopy of simulated endobronchial lesions: effect of scanning, reconstruction, and display settings and potential pitfalls. *AJR* 1998; 170:947–950.
- [7] Black RE, Johnson DG, Matlak ME. Bronchoscopic removal of aspirated foreign bodies in children. *J Pediatr Surg* 1994;29:682–684
- [8] Zerella JT, Dimler M, McGill LC, Pippus KJ. Foreign body aspiration in children: value of radiography and complications of bronchoscopy. *J Pediatr Surg* 1998;33:1651–1654
- [9] Diederich S, Lenzen H, Windman R, et al. Pulmonary nodules: experimental and clinical studies at low-dose chest radiography. *Radiology* 1999;213:289–298
- [10] Ambrosino MM, Genieser NB, Roche KJ, Kaul A, Lawrence RM. Feasibility of high-resolution, low-dose chest in evaluating the pediatric chest. *Pediatr Radiol* 1994;24:6–10
- [11] Dunn GR, Wardrop P, Lo S, Cowan DL. Management of suspected foreign body aspiration in children. *Clin Otolaryngol* 2002;27:384–386 21. Kavanagh PV, Mason AC, Müller NL. Thoracic foreign bodies in adults. *Clin Radiol* 1994;54: 353–360
- [12] Haliloglu M, Ciftci AO, Oto A, et al. CT virtual bronchoscopy in the evaluation of children with suspected foreign body aspiration. *Eur J Radiol* 2003;48:188–192