

## Case Report:

# The Incidental Finding of a Persistent Left Superior Vena Cava

<sup>1</sup>Dr.Rajvi Matalia, <sup>2</sup>Dr. Ravi Masand\*, <sup>3</sup>Dr. Aparna Sodani

<sup>1</sup>DMRD, DNB Resident, CHL Hospital, Indore

<sup>2</sup>MD, Head of department, CHL Hospital, Indore

<sup>3</sup>MD, Consultant Radiologist, CHL Hospital, Indore

Corresponding author\*

## Abstract

Persistent left superior vena cava is very rare but an important congenital vascular anomaly which is found incidentally most of the times. A left-sided SVC is seen in 0.3-0.5% of the normal population and in ~5% of those with congenital heart disease . Herewith we presented a case of 22-year-old boy presented with Bradycardia (HR: 40-45 BPM) . On examination, the general appearance of the patient was good. His blood pressure was 110/80 mmHg. Cardiac auscultation and electrocardiogram (ECG) were normal. Transthoracic echocardiography (TTE) revealed a dilated CS of 33 × 18 mm (Fig). There was no evidence of valvular heart disease. 2D ECHO & Doppler study revealed dilated coronary sinus due to Persistent left SVC draining into coronary sinus ). The right and left ventricles are also mildly dilated most probably due to bradycardia. The LVEF is 58%. Proper understanding of the anatomy , embryology and pathophysiology of PLSVC will reduce unnecessary and potentially harmful testing and save the patient from the fatal complications .

**Keywords:** Left Superior Vena Cava , vascular anomaly

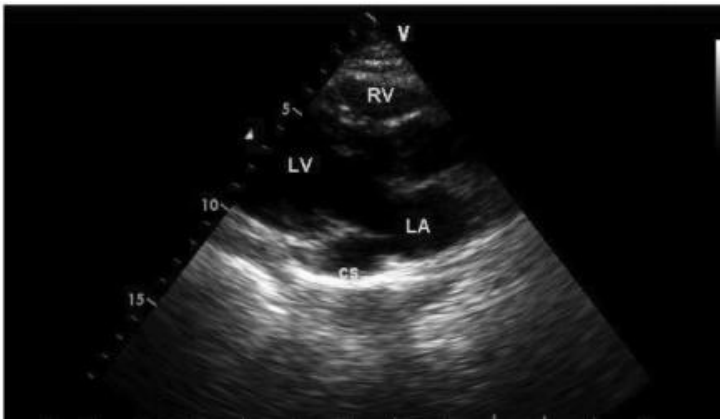
## Background

Persistent left superior vena cava is very rare but an important congenital vascular anomaly which is found incidentally most of the times. A left-sided SVC is seen in 0.3-0.5% of the normal population and in ~5% of those with congenital heart disease . It is only seen in isolation in 10% of cases since the vast majority have a normal right-sided SVC, called SVC duplication. It is mostly seen in isolation but can also be seen with various cardiovascular abnormalities which include atrial septal defect, , coarctation of aorta, bicuspid aortic valve, coronary sinus ostial atresia, and cor triatriatum. The presence of PLSVC can render access to the right side of heart challenging via the left subclavian approach, which is a common site of access utilized when placing pacemakers and Swan-Ganz catheters. With PLSVC occurring in only 0.3% to 0.5% of individuals in the general population and since there is theoretically only a 50% chance of encountering a PLSVC in an individual who has a PLSVC (by assuming that 50% of PLSVCs would be missed by a physician selecting the right side instead of the left side as the site of insertion of any given central venous access device), then it is possible that most physicians who are placing central venous access devices in their clinical practice may possible never, or only once, come across this congenital venous anomaly during their careers. In this regard, a resultant patient outcome in this rarely encountered scenario could potentially be disastrous and devastating if the possibility of PLSVC was not thought of and/or not recognized by the physician at the time of a "difficult" central venous access device placement procedure. In this case report we

present a patient with isolated PLSVC with no other cardiac abnormalities, who was diagnosed incidentally during 2D ECHO and further was advised MDCT for suspicion of intrathoracic malignancy.

### Case report

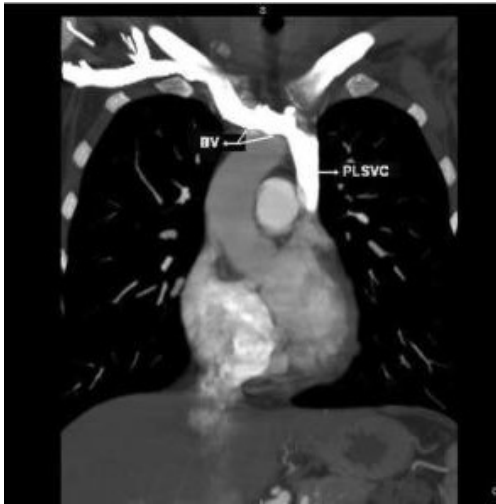Herewith we presented a case of 22-year-old boy presented with Bradycardia (HR: 40-45 BPM) . On examination, the general appearance of the patient was good. His blood pressure was 110/80 mmHg. Cardiac auscultation and electrocardiogram (ECG) were normal. Transthoracic echocardiography (TTE) revealed a dilated CS of  $33 \times 18$  mm (Fig). There was no evidence of valvular heart disease. 2D ECHO & Doppler study revealed dilated coronary sinus due to Persistent left SVC draining into coronary sinus ). The right and left ventricles are also mildly dilated most probably due to bradycardia. The LVEF is 58%.



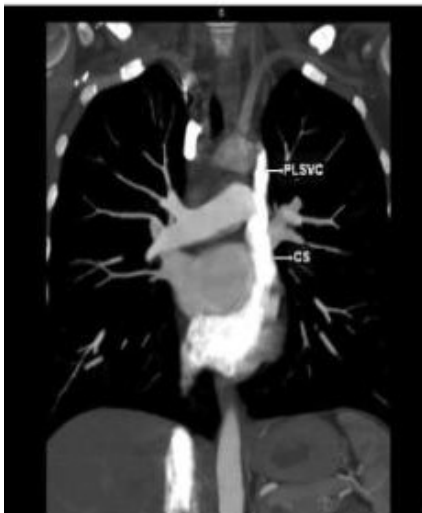Dilated coronary sinus (CS) on transthoracic echocardiography, parasternal long-axis view (LA : left atrium, LV : left ventricle, RV : right ventricle).

MDCT scan was performed which showed a bridging vein draining the right jugular and right subclavian veins; it joins the left brachiocephalic vein and formed the PLSVC, which descended at the left side of the mediastinum leftward of the pulmonary artery and left atrium (LA) before draining into the right atrium (RA) via a dilated coronary sinus (CS) (Figs ).

The RSVC was absent and the PLSVC carried all venous blood from the head, neck and upper extremities. There was no other pathological finding. The visceral organs were normally positioned.



Multiplanar reformatted image demonstrates that the right SVC is not seen and is absent and a bridging vein (BV) is draining the right jugular and subclavian veins, which is then joining the left brachiocephalic vein to form the persistent left superior vena cava (PLSVC).

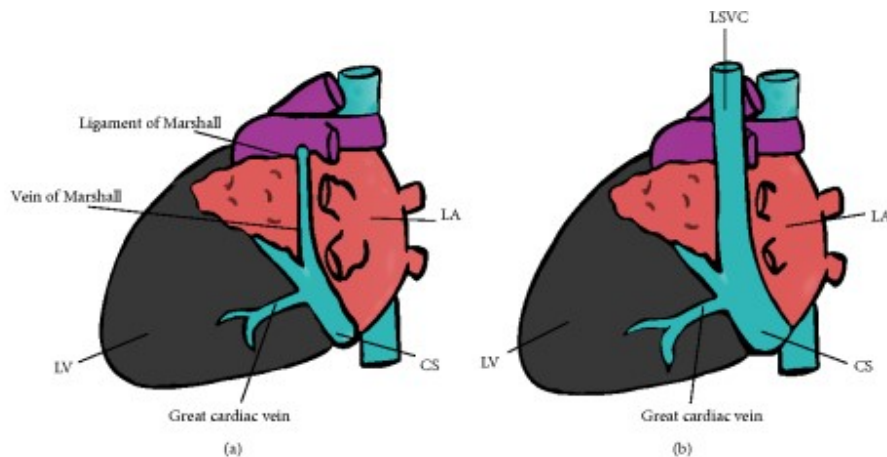


Multiplanar reformatted image reveals the persistent left superior vena cava (PLSVC) which is draining into a dilated coronary sinus (CS).

Contrast was injected from the left antecubital vein. The contrast first came in the CS, later in the RA. The injection was then repeated from the right antecubital vein, that also showed appearance of the contrast first in the CS and then in the RA. The diagnosis was confirmed and no other cardiac abnormality was detected.

## DISCUSSION :

PLSVC is a rare thoracic venous anomaly. It is a persistent congenital remnant of the vein of Marshall, which serves as a counterpart to the superior vena cava (SVC) in early embryologic development. The vein of Marshall fails to regress as development continues and, as a result, venous blood returns to the RA via the connection of the PLSVC into the coronary sinus (Figure ) PLSVC, in the absence of other congenital cardiac anomalies, is almost never diagnosed because it tends to be hemodynamically insignificant, rarely leading to symptoms <sup>[1,2]</sup>.



- (a) Schematic diagram demonstrating normal venous return to the right atrium. The vein of Marshall regresses during embryologic development, forming the ligament of Marshall. (b) Schematic diagram demonstrating a persistent left superior vena cava which empties into a dilated coronary sinus. The PLSVC results from failure of the vein of Marshall to regress during embryologic development.

With the new advances in imaging, the primary care providers can learn to see more patients in whom a PLSVC is incidentally diagnosed by computed tomography or magnetic resonance imaging that was performed for a variety of indications. Given the known association between anomalous venous return and the propensity for cardiac arrhythmias, this finding should be recorded and documented for future in the medical record and an inquiry made about possible cardiac symptoms, such as decreased exercise tolerance, progressive fatigue, chest discomfort, palpitations, or syncope. Yearly clinical followup, including an electrocardiogram, should be continued. Cardiac evaluation should be prompted by any deviations from the patient's baseline<sup>[3]</sup>.

The left superior vena cava (LSVC) is the embryological precursor of the ligament of Marshall, which has been implicated in the initiation and maintenance of atrial fibrillation (AF). Rarely, the LSVC may persist and has been associated with some organized arrhythmias, though not with AF <sup>[1]</sup>.

This higher prevalence of PLSVC detection is during the PM/ICD placement. The patients with congenital anomalous venous return are at an increased risk of abnormalities associated with the cardiac conduction system, leading to arrhythmias that may require the placement of PM or defibrillators <sup>[3]</sup>.

During the normal development, the right sided site (located in the sinus venosus) usually forms the sinoatrial node (SA NODE) while the left sided site (located in the posterior cardinal vein) migrates downward to an area near the coronary sinus. This latter (left sided) tissue in normal development loses its conduction ability as the vein

degenerates, but it is retained if this tissue fails to regress and instead forms a PLSVC. Consequently, abnormal electrophysiologic function can arise from this site, manifesting as both tachyarrhythmias (supraventricular tachycardias, atrial fibrillation/flutter, or Wolff-Parkinson-White syndrome) and bradyarrhythmias (due to the development of atrioventricular conduction blocks) <sup>[1,3]</sup>.

#### **Conclusion:**

Proper understanding of the anatomy , embryology and pathophysiology of PLSVC will reduce unnecessary and potentially harmful testing and save the patient from the fatal complications .

#### **References**

1. L.-F. Hsu, P. Jaïs, D. Keane et al., “Atrial fibrillation originating from persistent left superior vena cava,” *Circulation*, vol. 109, no. 7, pp. 828–832, 2004.
2. B. D. Sarodia and J. K. Stoller, “Persistent left superior vena cava: case report and literature review,” *Respiratory Care*, vol. 45, no. 4, pp. 411–416, 2000.
3. D. R. Morgan, C. G. Hanratty, L. J. Dixon, M. Trimble, and D. B. O’Keeffe, “Anomalies of cardiac venous drainage associated with abnormalities of cardiac conduction system,” *Europace*, vol. 4, no. 3, pp. 281–287, 2002.
4. Z. Jović, Z. Mijailović, S. Obradović et al., “Successful implantation of a permanent pacemaker through a persistent left superior vena cava by using a right subclavian approach,” *Vojnosanitetski Pregled*, vol. 68, no. 9, pp. 792–794, 2011.
5. M. Kilickap, T. Altin, O. Akyurek, R. Karaoguz, G. Akgun, and M. Guldal, “DDD pacemaker implantation in a patient with persistent left superior vena cava and absent right superior vena cava: a four-year follow-up report,” *Canadian Journal of Cardiology*, vol. 21, no. 13, pp. 1221–1223, 2005.
6. V. Sankhla, B. Vajifdar, M. Shah, and Y. Lokhandwala, “Left-sided biventricular pacemaker implantation in the presence of persistent left superior vena cava,” *Indian Heart Journal*, vol. 62, no. 4, pp. 344–345, 2010.
7. W. B. Meijboom and M. Vanderheyden, “Biventricular pacing and persistent left superior vena cava: case report and review of the literature,” *Acta Cardiologica*, vol. 57, no. 4, pp. 287–290, 2002.
8. R. E. Lane, A. W. C. Chow, J. Mayet, and D. W. Davies, “Biventricular pacing exclusively via a persistent left-sided superior vena cava: case report,” *Pacing and Clinical Electrophysiology*, vol. 26, no. 2, part 1, pp. 640–642, 2003.
9. A. Kapetanopoulos, G. Peckham, F. Kiernan, C. Clyne, J. Kluger, and M. A. Migeed, “Implantation of a biventricular pacing and defibrillator device via a persistent left superior vena cava,” *Journal of Cardiovascular Medicine*, vol. 7, no. 6, pp. 430–433, 2006.