

**Original article:**

## **Sacralization of the 5<sup>th</sup> lumbar vertebra and elongated sacral hiatus**

**<sup>1</sup>Dr. Dinendra Kumar Saha , <sup>2</sup>Dr. Hasi Dasgupta, <sup>3</sup>Dr. Susumna Biswas , <sup>4</sup>Dr. Mithu Paul , <sup>5</sup>DR. Reshma Ghosh , , <sup>6</sup>Dr. Sudeshna Majumdar, <sup>7</sup>Dr. Biplab Goswami**

<sup>1</sup>Resident Medical Officer, Department of Radiodiagnosis, Institute of Post Graduate Medical Education and Research and SSKM Hospital, Kolkata – 700020, West Bengal, India.

<sup>2</sup>Professor and Head, Department of Anatomy, Nilratan Sircar Medical College, Kolkata - 700014, West Bengal, India.

<sup>3</sup>Demonstrator, Department of Anatomy, Nilratan Sircar Medical College, Kolkata – 700014, West Bengal, India.

<sup>4</sup>Junior Resident, Department of Anatomy, Nilratan Sircar Medical College, Kolkata – 700014, West Bengal, India.

<sup>5</sup>Junior Resident, Department of Anatomy, Nilratan Sircar Medical College, Kolkata – 700014, West Bengal, India.

<sup>6</sup> Professor, Department of Anatomy, Nilratan Sircar Medical College, Kolkata -700014, West Bengal, India.

<sup>7</sup>Demonstrator, Department of Anatomy, Nilratan Sircar Medical College, Kolkata – 700014, West Bengal, India.

**Name of the corresponding author: Prof. (Dr.) Sudeshna Majumdar**

---

### **ABSTRACT**

The sacrum is a large, triangular fusion of five vertebrae. The sacrum may contain six vertebrae, by development of an additional sacral element by incorporation of the fifth lumbar (L5) or the first coccygeal vertebra. Sacralization of the fifth lumbar vertebra is a congenital anomaly and this variation was found in a bony pelvis among the collection of bones in the Department of Anatomy of NRS Medical College of Kolkata, India. The L5 sacralization may give rise to low back pain and other complications. Moreover, another sacrum was found with elongated, inverted 'V' shaped sacral hiatus and the sacral hiatus is important for caudal epidural block. These two sacra are described here with their variations.

**KEY WORDS:** Sacrum, sacralization, spondylolisthesis, sacral hiatus.

---

### **INTRODUCTION**

The sacrum is a large, triangular fusion of five vertebrae and forms the posterosuperior wall of the pelvic cavity, wedged between the two hip (innominate) bones. It has a blunted, caudal apex that articulates with the coccyx and its superior wide base articulates with the lumbar vertebra at the sacral angle<sup>1</sup>. The sacrum is set obliquely and curved longitudinally; the dorsal surface is convex and the ventral surface is concave: the ventral curvature increases the pelvic capacity<sup>1</sup>. The ventral surface of

the pelvis has four ventral sacral foramina, which communicate with the sacral canal through the intervertebral foramina and transmit the ventral rami of upper four sacral spinal nerves, whereas the dorsal surface has four pairs of dorsal sacral foramina to transmit the dorsal rami of the same nerves. In childhood, individual sacral vertebrae are connected by cartilage and the adult bone retains many vertebral features<sup>1</sup>.

The bony pelvis is a ring of bone consisting of two hip bones in front and sides and the sacrococcygeal

part of the vertebral column behind. The pubic parts of the hip bones are connected to each other by the symphysis pubis which is a secondary cartilaginous joint. The articular surfaces of the lateral mass of the sacrum articulate with the corresponding surface of the ilium of hip bones forming a pair of plane synovial sacro-iliac joints<sup>2</sup>.

On the dorsal surface of the sacrum there is a raised median sacral crest, with four, sometimes, three tubercles which represent the fused sacral spines. Below the fourth (or the third) tubercle there is an arched sacral hiatus (on the posterior wall of the sacral canal), produced by the failure of the fusion of the two laminae of the fifth sacral vertebrae or sometimes the fourth in the median plane. The remnants of the inferior articular processes of the fifth lumbar vertebra elongates downwards on both sides of the sacral hiatus to form the sacral cornua<sup>1</sup>.

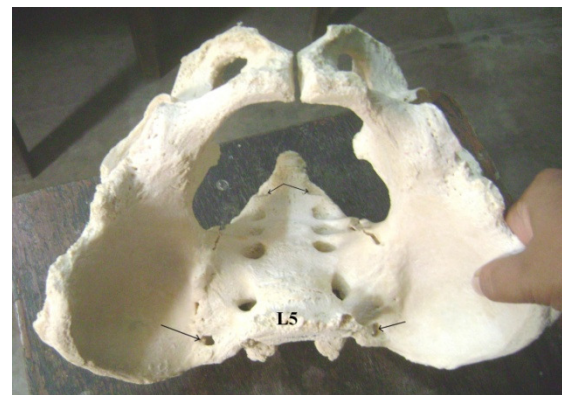
**Variations:** The sacrum may contain six vertebrae, by development of an additional sacral element by incorporation of the fifth lumbar (L5) or the first coccygeal vertebra. Inclusion of the fifth lumbar vertebra (sacralization) is usually incomplete and limited to one side. In the most minor degree of the abnormality a fifth lumbar transverse process is large and articulates, sometimes by a synovial joint, with the sacrum at the posterolateral angle of the base. Sacralization is a segmentation anomaly<sup>1</sup>.

#### **MATERIALS AND METHODS**

In a bony pelvis, present in the collection of bones in the Department of Anatomy of NRS Medical College, Kolkata, few variations were found. In a sacrum derived from the same collection a variation was also found. Those findings were observed properly and relevant photographs were taken.

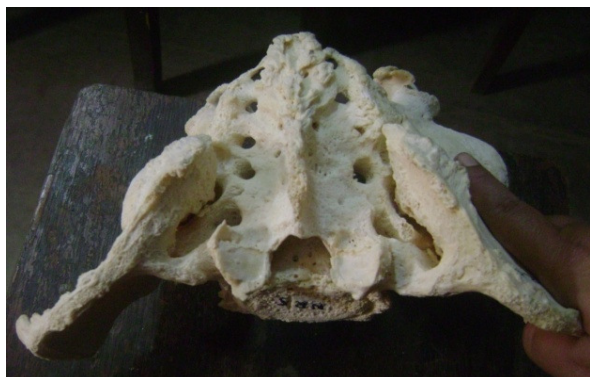
#### **OBSERVATIONS**

A bony pelvis was found in the Department of Anatomy, NRS Medical College, Kolkata, where the fifth lumbar vertebra has united with the first sacral vertebra on the midline and both sides. So the sacrum had six vertebrae. There are five sacral foramina instead of four both on the pelvic and dorsal surfaces of the sacrum. Over the sacroiliac joint on each side there is a bony foramen in the upper part. The sacroiliac joint has been ossified partially on both sides. Another single sacrum was found with elongated sacral hiatus. The laminae of the third fourth and fifth sacral vertebra failed to join with each other and we have got the long, inverted 'V' shaped sacral hiatus below the 2<sup>nd</sup> piece of sacrum.

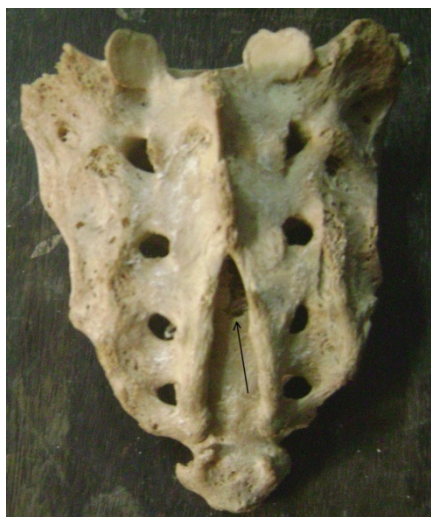

**Figure –1;**

Bony pelvis with sacralization of the 5<sup>th</sup> lumbar vertebra (L5). Five pelvic sacral foramina are visible here. An opening at the junction of sacrum and ilium on each side is marked with arrow, so also the fifth pelvic sacral foramina.



**Figure – 2;** The dorsal surface of the sacrum with five dorsal sacral foramina is visible in the bony pelvis. The 1<sup>st</sup> dorsal sacral foramen is incomplete on right side.



**Figure –3;** Inverted ‘V’ shaped, elongated sacral hiatus (marked with an arrow).

## DISCUSSION

The study conducted by Khairnar and Rajale shows sacralization in 6.6 % cases<sup>3</sup>, whereas Magora & Schwartz found 20.8% sacralization in their studies<sup>4</sup>. Lumbo-sacral transitional vertebrae (LSTV) are common congenital anomalies which include lumbarization and sacralization and observed first time by Bertolotti<sup>3,5</sup>. In LSTV, either the fifth lumbar vertebra may show assimilation to the sacrum (sacralization), or the first sacral vertebra may show transition to a lumbar configuration (lumbarization).

Investigations to diagnose such condition in clinical practice are plain x-rays, CT scan, and MRI<sup>3</sup>.

The frequency of sacralization in the low back pain (LBP) population ranges from 6% to 37%<sup>6,7</sup>. Although there is some debate, it is possible that sacralization of 5th lumbar vertebra contributes to the development of degenerative spondylolisthesis, lumbar disc degeneration and herniation, and low back pain (LBP)<sup>8,9</sup>. This pain may result from the pressure on nerves or nerve trunks, ligamentous strain around the sacralization, compression of soft tissues between bony joints due to L5 sacralization<sup>3</sup>.

The sacralization of L5 is thought to cause stress concentration on L4-L5, which can accentuate development of degenerative spondylolisthesis - a common pathological entity of the lumbar spine, especially of L4-L5<sup>8</sup>. Spondylolisthesis is the forward displacement of a vertebra, especially the fifth lumbar vertebra, most commonly occurring after a break or fracture<sup>10</sup>.

The common radiological findings in degenerative spondylolisthesis include arthritic changes of joints facets and disc degeneration, as well as anterior slippage of the corresponding level<sup>8,11</sup>. In the study, conducted by Kong et al, it has been reported that the incidence of L5 sacralization was higher (54/78=69%) among patients with degenerative spondylolisthesis at L4-L5, than in the general population<sup>8,12</sup>.

L5 is linked to the sacrum by several types of articulation, and this leads to a relatively stable lumbosacral junction<sup>13</sup>. According to Bulut et al (in 2013) the relationship between low back pain (LBP) and sacralization is not clear and they found no significant correlation to conclude that the incidence of transitional vertebra is equal in those with and

without back pain, rendering it only an incidental finding on imaging<sup>11,14</sup>.

Inverted 'V' shaped sacral hiatus was found in 23% cases in a study conducted by Bhattacharya et al in 2013, but in most of the cases the hiatus is Inverted 'U' shaped<sup>15</sup>. Caudal epidural block (CEB) involves the injection of anaesthetic medications into the epidural space through the sacral hiatus to provide analgesia and anaesthesia for different clinical

conditions<sup>16</sup>. Understanding the anatomical variations of sacral hiatus may improve the reliability of CEB<sup>15,17</sup>.

**CONCLUSION:** From this discussion we can conclude that the variations in sacrum described above, have immense importance in Gross Anatomy, Orthopaedics, Anaesthesiology etc.

### **Acknowledgement:**

We are grateful to Dr. Santanu Bhattacharya, Dr. Jayeeta Burman and other members of the Department of Anatomy, Nilratan Sircar Medical College, Kolkata -14, West Bengal, India, for their cordial help.

### **REFERENCES**

1. Standring S, Newell RLM, Collins P, Healy JC, Bogduk N, Christ BEA, Lee J (editors). In: Gray's Anatomy, The Anatomical Basis of Clinical Practice. The Back; 40th Edition. Churchill Livingstone Elsevier, Spain. 2011: 724-728.
2. Datta AK. Essentials of Human Anatomy, Thorax and Abdomen. In: The Pelvis. 7<sup>th</sup> Edition. Current Book International, Kolkata, Mumbai; India. 2006: 342-348.
3. Khairnar KB, Rajale MB. Sacralization of Lumbar Vertebra. Indian Journal of Basic & Applied Medical Research; March, 2013, Issue-6, Vol.-2, P. 510-514.
4. Magora A, Schwartz A. Relation between the low back pain syndrome and X-ray findings. Transitional vertebra (mainly sacralization). Scan J Rehabil Med 1978; 10: 135-45
5. Bertolotti M. contributo alla conoscenza dei vecchi differenziazione regionale del rachida con speciale regards all asimilazione sacrale della v.lombare. Radiologique Medica 1917; 4:113-44.
6. Bulut M, Uçar BY, Uçar D, Azboy I, Demirtaş A, Alemdar C, Mehmet Gem M, Özkul E. Is Sacralization Really a Cause of Low Back Pain? Clinical Study. ISRN Orthopedics. Volume 2013 (2013).
7. Seğer M, Muradov JM, and Dalgıç A. "Evaluation of congenital lumbosacral malformations and neurological findings in patients with low back pain." Turkish Neurosurgery, 2009; vol. 19, no. 2, pp. 145–148.
8. Kong CG, Park JS, Park JB: Sacralization of L5 in Radiological Studies of Degenerative Spondylolisthesis at L4-L5. Asian Spine J. Jun 2008; 2(1): 34–37.
9. Berlemann U, Jeszenszky DJ, Buhler DW, Harms J. The role of lumbar lordosis, vertebral end-plate inclination, disc height, and facet orientation in degenerative spondylolisthesis. J Spinal Disord. 1999;12: 68–73.

10. Wikipaedia: Spondylolisthesis .Available at <http://en.wikipedia.org/w/index.php>. Updated on 2014/21st April,
11. Fitzgerald JA, Newman PH. Degenerative spondylolisthesis. *J Bone Joint Surg Br.* 1976; 58:184–192.
12. Cinotti G, Postacchini F, Fassari F, Urso S. Predisposing factors in degenerative spondylolisthesis. A radiographic and CT study. *Int Orthop.* 1997; 21:337–342.
13. Tini PG, Wieser C, Zinn WM. The transitional vertebra of the lumbosacral spine: its radiological classification, incidence, prevalence, and clinical significance. *Rheumatol Rehabil.* 1977; 16:180–185.
14. Paajanen H, Erkintalo M, Kuusela T, Dahlstrom S, Korman M. Magnetic resonance study of disc degeneration in young low-back pain patients. *Spine*, 1989; vol. 14, no. 9, pp. 982–985.
15. Bhattacharya S, Majumdar S, Chakraborty P, Mazumdar S, Mazumdar M. A morphometric study of sacral hiatus for caudal epidural block among the population of West Bengal. *Indian Journal of Basic & Applied Medical Research*; June 2013: Issue-7, Vol.-2, pp. 660-667.
16. Chen PC, Tang SFT, Hsu TC et al. Ultrasound guidance in caudal epidural needle placement. *Anesthesiology* 2004; 101: 181–4.
17. Sekiguchi M, Yabuki S, Satoh K, Kikuchi S. An anatomic study of the sacral hiatus: a basis for successful caudal epidural block. *Clin J Pain* 2004; 20: 51–4.

Date of submission: 14 March 2014

Date of Provisional acceptance: 18 March 2014

Date of Final acceptance: 27 April 2014

Date of Publication: 07 June 2014

Source of support: Nil; Conflict of Interest: Nil

