

Case Report:

Sigmoid Colon as a Content of inguinal Hernia: A Case report

¹DR. PANCHANAN KUNDU,² DR. SEIKH ALI AMAM,³ DR. HASI DASGUPTA,

⁴DR.PITBARAN CHAKRABORTY,⁵ DR. SUDESHNA MAJUMDAR *,⁶ DR. ARPAN KUMAR GOSWAMI

¹ Professor, Department of Anatomy, Medical Super. and Vice Principal,
Bankura Sammilani Medical College, Bankura -722101, West Bengal, India.

²Associate Professor, Department of Anatomy, Nilratan Sircar Medical College,
Kolkata – 700014, West Bengal, India.

³Professor and Head, Department of Anatomy, Nilratan Sircar Medical College,
Kolkata – 700014, West Bengal, India.

⁴Professor, Department of Anatomy, Bankura Sammilani Medical College, Bankura - 722101,
West Bengal, India.

⁵Professor, Department of Anatomy, Nilratan Sircar Medical College, Kolkata – 700014,
West Bengal, India.

⁶Demonstrator, Department of Anatomy, Nilratan Sircar Medical College, Kolkata – 700014,
West Bengal, India

*Corresponding author: E-mail I.D. : sudeshnamajumdar.2007 @ rediffmail.com

Abstract:

Inguinal hernia can be of two types - direct and indirect, of which indirect one is the commonest variety. This indirect variety of hernia is believed to be congenital in nature which is due to persistence of processus vaginalis - a peritoneal diverticulum in the lower part of the abdomen in foetal life. During routine dissection of abdomen for the M.B.B.S. students in the Bankura Sammilani Medical College, Bankura, West Bengal, India, a case of left sided indirect inguinal hernia was found in a male cadaver aged about 50 years, in the year 2005. The content of the hernial sac was a loop of sigmoid colon and part of sigmoid mesocolon which are rarely found as a content in the hernial sac. This case report may make the surgeons conscious about a rare content inside the sac of inguinal hernia, so that the complications of inguinal hernia can be avoided.

Key words : Indirect Inguinal Hernia, Direct Inguinal Hernia, Sigmoid Colon

Introduction

Protrusion of any viscus (covered by a peritoneal sac) through the inguinal region of abdominal wall is known as inguinal hernia. Inguinal hernia is principally of two types- oblique or indirect and direct. The content of the hernial sac may vary from a piece of omentum to small or large intestine; ileum being commonest. Other abdominal viscera may rarely be involved, like appendix, stomach, Meckel's diverticulum etc ¹. On the right side, caecum, appendix, ascending colon are involved and on the left sigmoid colon ².

The inguinal canal is formed in the lower part of the anterior abdominal wall due to the descent of the gubernaculum of the testis or ovary. A peritoneal fold known as the 'processus vaginalis' protrudes down the inguinal

canal along the ventro-superior aspect of the gubernaculum. The canal is about 4cm long with two ends-superficial and deep inguinal rings. The inferior epigastric vessels lie along the posterior wall of the canal medial to the deep ring. The superficial inguinal ring is a triangular aperture in the aponeurosis of external oblique muscle, with two crura, lying just above lateral to the pubic crest¹. The deep inguinal ring is U shaped gap in the condensed fascia transversalis and situated 1.25cm above the mid inguinal point^{3,4}. These two rings vary in size¹. In femoral hernia the neck of the hernia sac lies below and lateral to the pubic tubercle and in inguinal hernia above and medial to it^{3,4}.

Indirect inguinal hernia is the commonest type¹. The sac passes down the canal on the outer aspect of the spermatic cord, with the neck passing through the deep inguinal ring lateral to the inferior epigastric vessels. It is believed to be congenital in nature due to persistence of the processus vaginalis³. In the direct variety, herniation occurs through the posterior wall and through the Hesselbach's inguinal triangle⁵. The sac protrudes posterior to the spermatic cord and the neck lies medial to the inferior epigastric vessels¹. It is always acquired in nature, associated with straining factors, like chronic cough, usually in older age group when muscle tone is less³.

Materials and methods

During routine dissection for the 1st year MBBS students in the year 2005 in Bankura Sammilani Medical College, West Bengal, a case of left sided indirect inguinal hernia was found in a 50 year aged male cadaver. On further dissection the content of the hernial sac was found to be a loop of sigmoid colon .

The hernial sac was separated from the adhesions of the inguinal canal and its usual contents .It was revealed that the tip of the hernial sac reached the superficial inguinal ring. After lifting up the inguinal sac, the inguinal canal was measured in length on the left side. Shape, position and measurements (length and breadth) of the deep and superficial rings were noted on the left side.

Right sided inguinal region was also meticulously dissected to detect any hernia there. Similar measurements were taken on the right side to compare those with the left side.

Position of the inferior epigastric artery was observed on two sides, specially its relation to the neck of the hernial sac on the left side.

Relevant structures were coloured and photographs were taken.

Following measurements of the hernia sac were taken:

1. Length of the sac: Measured from neck to apex at four positions: a) Anterior ,
b) Posterior, c) Lateral, d) Medial aspects of the sac. The longest one was considered.

2. Breadth of the sac: Measured at three sites: a) at the neck b) midway between the neck and apex c) at the apex. The widest diameter was considered.

The sac was opened and the herniated loop of large intestine was identified, its features and the way of entry were noted.

The measurements of herniated loop of gut was taken in the following way:

- 1. Length of the loop** – from base to apex.
- 2. Breadth of the loop**- measured at three different sites - neck, apex and midway between them.

The loop of the herniated gut was separated from rest of the large intestine, kept in 10% formal saline solution and was examined for histological examination after paraffin block preparation.

Results

On the left side, a hernial sac was found inside the inguinal canal. The inferior epigastric vessels were present on the medial side of the neck of the hernial sac which contained a loop of intestine. So on **left side an indirect inguinal hernia was found.**

On further dissection it was revealed that the herniated viscus had all three cardinal features of large intestine (haustrations, taeniae coli, appendices epiploicae) along with a mesentry on one side. **The content of the hernial sac was a loop of sigmoid colon with sigmoid mesocolon.** That loop had one proximal part and one distal part and it was adherent to the wall of inguinal canal partially. The loop was separated from the adhesions and various measurements were taken.

On the right side no hernia was visible in the inguinal region.

Table 1 : Measurements of the inguinal region:

Measurements		Left side (cm)	Right side(incm)
Length of the inguinal canal		3.78	3.75
Deep ring	Vertical length	2.8	1.2
	Breadth	2.7	1
Superficial ring	Vertical length	2.9	2.3
	Breadth	2.8	1.24

Table 2: Length of left sided hernial sac (from neck to apex):

Different Aspects	Measurements (in cm)
Anterior	5.6
Posterior	5.55
Medial	5.45
Lateral	5.44
Longest one	5.6

Table 3 : Breadth of the left sided hernial sac

Taken at sites	Measurements (in cm)
At neck	2.7
At apex	2.9
Midway between them	2.8
The widest one	2.9

Table 4 : Measurements of the herniated loop of the sigmoid colon :

		Measurements (in cm)
Length (from base to apex)		5.8
Breadth	At the neck	2.7
	At the apex	2.9
	Midway between neck and apex	2.8

On histological examination, the normal features of the large intestine was found. There were four layers in the wall (mucous membrane, submucosa, muscle layer and serous coat). Abundant goblet cells were visible in the epithelial lining of the mucous membrane.

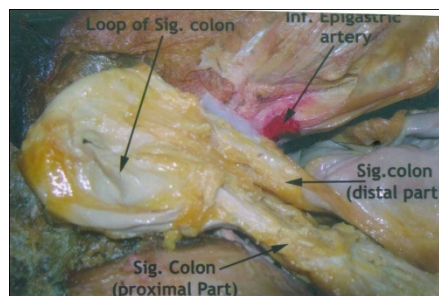


Figure 1 : A loop of the sigmoid colon as the content of hernial sac. The inferior epigastric artery was visible medial to the neck of the loop.

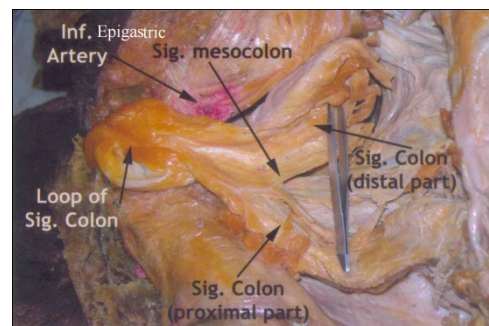


Figure 2 : Loop of the sigmoid colon with sigmoid mesocolon.

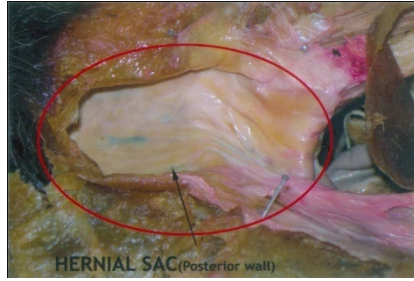


Figure 3 : Hernial Sac.

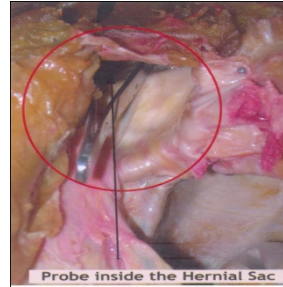


Figure 4 : Probe inside the hernial sac.

DISCUSSION

According to Galloday, 10% of the population develops some type of hernia during lifetime. 50% of the hernias are of indirect inguinal variety with a male to female ratio of 7:1. 25% are direct inguinal, 14% umbilical and 5% femoral hernia⁶. Prevalence of all types of hernia increases with age⁶.

Indirect inguinal hernias may have a wide neck and occlusion of the deep inguinal ring may not be possible with simple digital pressure⁷. There may be complications of inguinal hernia like 1) irreducible hernia, 2) obstructive hernia, 3) strangulated and inflamed hernia. Blood supply to a herniated viscus is compromised in strangulated hernia³ and it is one of the most common surgical emergencies⁸. Visceral contents are difficult to be reduced in incarcerated hernia which is one of the common causes of colonic obstruction (Basson)⁹. In chronic hernias adhesions may impair reduction^{3,9}.

Aberrant collagen states e.g. Ehler-Danlos Syndrome, Hurler and Hunter Syndromes, osteogenesis imperfecta, Marfan's syndrome, Alport's syndrome etc. and undescended testis are associated with increased prevalence of inguinal hernias. Clinical conditions like ascites, constipation, obstructive uropathies, chronic obstructive pulmonary diseases or chronic cough can also be associated with inguinal hernias^{2,6}.

In the present study content of the hernial sac was sigmoid colon. In 2012, Pathak et al presented a very rare case of congenital inguinal hernia with sigmoid colon as a content (the six months old male child had a left sided complete hernia)¹⁰. Bali et al in 2011 presented an extremely rare case of a strangulated right inguinal hernia containing the sigmoid colon⁸. Gregory (2006) presented a case of colonic inguinal hernia in a 43 year old man where the content of hernial sac was a loop of sigmoid colon with double constriction of the segment¹¹. According to him, barium enema X-ray is to be done in such cases followed by appropriate surgery. Upport et al, in 2000, stated in a case report that a 47 year old man underwent colonic resection surgery of 23cm. long segment of perforated sigmoid colon following a road traffic accident; he had a 6 months history of left sided inguinal hernia of which the loop of perforated sigmoid colon was a content (as was revealed by a CT scan before surgery)¹²

Conclusion

From the above case reports we came to the conclusion that herniation of a loop of sigmoid colon into the left sided inguinal canal may occur occasionally, as was found in the present case. This case has profound clinical importance, because such hernias are to be operated with proper precautions to avoid complications noted earlier, though strangulation of a part of herniated large gut is of rarity³.

Presentation at a Meeting: The case report was presented in the National Conference Anatomical Society of India, held in Kochi, Kerala in 2006.

Acknowledgement:

We are grateful to Professor (Dr.) Maya Ghosh and other members of the Department of Anatomy, Bankura Sammilani Medical College, Bankura, West Bengal, India, for their kind co-operation to complete this case report. We express our gratitude to Professor R. K. Ghosh, W.B. University of Animal and Fishery Sciences, for his cordial help.

References:

1. Williams PL, Bannister LH, Berry MM, Collins P, Dyson M, Dussek JE, Ferguson MWJ (editors) (1995). In: Gray's Anatomy; The Anatomical Basis of Medicine and Surgery. Alimentary system; 38th edition; Churchill Livingstone; New York, Edinburgh, London, Tokyo, Madrid, Melbourne; 1788-1789.
2. Brunnicardi Charles F (Editor-in- chief) (2005). In: Schwartz's Principle of Surgery; Inguinal Hernias; 8th Edition; McGraw-Hill Medical Publishing Division, New York; 1353-1394.
3. Russel RCG, Williams NS, Bulstrode CJK (2000). In: Bailey & Love's short practice of surgery; Hernias, Umbilicus, Abdominal wall. 23rd edition; Arnold, London. 1145-1150.
4. Snell RS (2008). In: Clinical Anatomy by Regions. The abdomen, Part 1- The abdominal wall; 8th edition; Lippincott, Williams &Wilkins; London, Buenos Aires, Hong Kong, Sydney, Tokyo; 183-185.
5. Sinnatamby CS (1999). In: Last's Anatomy, Regional and Applied; Abdomen; 10th Edition; Churchill Livingstone, London; 220-221.
6. Golladay ES (September, 2000). Abdominal hernia; British Journal of Surgery; 57(9):1166.
7. Stranding S, Borley NR, Collins P (editors) (2005); In: Gray's Anatomy; The Anatomical Basis of Clinical Practice. Anterior abdominal wall, 3rd edition; Elsevier Churchill Livingstone Ltd; New York, Edinburgh, London, Oxford, Philadelphia, St.Louis, Sydney, Toronto; 1111-1112.
8. Bali C, Tsironis A, Zikos N, Mouselimi M, Katasmakis N (2011). An unusual case of a strangulated right inguinal hernia containing the sigmoid colon. *Int J Surg Case Rep.* 2(4): 53–55.
9. Basson MD (February, 2004). Colonic obstruction. *Drugs;* 7(2):160-165.
10. Pathak N, Langer V, Rajagopalan S (October, 2012). Sigmoid colon as a content of congenital inguinal hernia: A rare presentation; *Medical Journal Armed Forces of India.*
11. Gregory RS; Colonic inguinal hernia (2006). *Medpix TM Teaching;* File case no;4634, Case summary 4634-11, National capital consortium-11.
12. Upport RN; Ghey VK; Gupta R; Gold SW (2000). Intestinal perforation from blunt trauma to an Inguinal Hernia; *American Journal of Roentgenology;* 174:1538.

Date of submission: 08 June 2013

Date of Provisional acceptance: 16 June 2013

Date of Final acceptance: 28 July 2013

Date of Publication: 04 September 2013

Source of support: Nil

Conflict of Interest: Nil